

Evaluation of imaging diagnostics in dizziness induced by cerebral small vessel disease: A focus on transcranial Doppler and CT

Y. Wei, Q. Wang, J. Yang*

Department of Neurology, Shanghai Construction Engineering Hospital, Shanghai, China

ABSTRACT

► Short Report

*Corresponding author:

Jiandao Yang, BM.,

E-mail:

jessica555777@163.com

Received: March 2024

Final revised: May 2024

Accepted: June 2024

Int. J. Radiat. Res., January 2025;
23(1): 249-254

DOI: 10.61186/ijrr.23.1.249

Keywords: Cerebral small vessel disease, dizziness, transcranial Doppler, computed tomography, diagnostic imaging.

Background: This study aims to evaluate the therapeutic efficacy of hyperbaric oxygen (HBO) as adjuvant therapy for patients with cerebral small vessel disease (CSVD) related dizziness and to assess the impact of this treatment on diagnostic indicators from both transcranial Doppler (TCD) and computed tomography (CT). **Materials and Methods:** A prospective randomized controlled study was conducted from January 2019 to December 2023, including 200 patients with CSVD related dizziness. They were randomly assigned to either the HBO group or the control group. The control group received betahistine mesylate tablets, while the HBO group received HBO in addition to the control group treatment. Various parameters including Dizziness Handicap Inventory (DHI) scores, cerebral artery blood flow velocity (Vm), resistance index (RI), pulsatility index (PI), cystatin (Cys), homocysteine (HCY), hypersensitive c-reactive protein (hs-CRP) levels, and CT imaging for grading cerebral white matter degeneration were assessed before and after treatment. **Results:** After treatment, DHI scores in both groups decreased significantly, with the HBO group showing greater improvement compared to the control group. Hemodynamic parameters (Vm, RI, PI) improved significantly in both groups, with greater improvements seen in the HBO group. White matter lesion grading and levels of Cys, HCY, and hs-CRP were significantly lower in the HBO group post-treatment compared to the control group. **Conclusions:** HBO as adjuvant therapy demonstrates significant therapeutic benefits for CSVD related dizziness. It effectively alleviates symptoms, improves hemodynamic parameters, enhances white matter lesion assessment outcomes, and promotes neurological function recovery.

INTRODUCTION

CSVD encompasses a spectrum of disorders initiated by vascular lesions within the brain with a diameter ranging from 40 to 200 μm ⁽¹⁾. These pathologies include microcirculation disturbances, microbleeds, and pathological changes in the brain's white matter ^(1,2). These vascular alterations typically result in abnormalities in the functioning of the nervous system, leading to a cascade of symptoms such as balance disorders, urinary and fecal incontinence, as well as cognitive and emotional disturbances, directly impacting the holistic health of individuals ⁽³⁾. The global prevalence of CSVD is significant, especially among the elderly, affecting an estimated 15% of older adults worldwide, marking it as an increasingly concerning neurological condition. With the exacerbation of societal aging trends, the incidence of CSVD exhibits a steady upward trajectory, rendering it a neurologic condition of heightened concern ⁽⁴⁾.

Upon examination through imaging modalities, CSVD patients often present with pathological changes in the head, manifested as tiny bleeding

points and lesions in the brain's white matter ⁽⁵⁾. These pathological features are commonly accompanied by a spectrum of symptoms, including balance disorders, urinary and fecal incontinence, as well as cognitive and emotional impairments ⁽⁶⁾. This significantly affects the quality of life for patients, emphasizing the pressing need for effective treatment and intervention ^(7,8). Current treatments predominantly involve symptomatic and preventive approaches, which often fail to achieve consistent therapeutic outcomes due to their limitations in effectiveness and potential side effects.

Dizziness, as a prevalent clinical symptom among elderly CSVD patients, significantly disrupts their daily lives with diverse manifestations such as visual rotation, a sensation of head heaviness, self-perceived swaying, and gait abnormalities ⁽⁹⁾. The pathophysiological mechanisms linking CSVD to these symptoms are not fully understood, necessitating further research into innovative treatment modalities. This dizziness may further lower the quality of life for patients. Current treatments for vascular-origin dizziness primarily encompass symptomatic treatment, etiological

treatment, preventive measures, and rehabilitation. However, while drug therapy combined with physical training can alleviate symptoms to some extent, achieving satisfactory therapeutic outcomes remains a challenge, prompting the need for further enhancement of treatment effectiveness ⁽¹⁰⁾.

Emerging research suggests that hyperbaric oxygen (HBO) therapy might be a promising treatment for CSVD-induced dizziness, offering potential improvements in cognitive function and daily capabilities with a high safety profile ⁽¹¹⁾. However, substantial uncertainties remain about the efficacy of HBO in this specific context, highlighting the need for comprehensive clinical trials to substantiate its benefits ⁽¹²⁾. Some researchers propose that hyperbaric oxygen (HBO) therapy may serve as an effective treatment modality for elderly CSVD patients ⁽¹¹⁾. HBO treatment not only significantly improves patients' cognitive function and enhances their daily life capabilities but also boasts a high level of safety. Nevertheless, uncertainties persist regarding whether HBO treatment yields positive effects in CSVD-related dizziness patients, necessitating clinical validation ⁽¹²⁾.

Against this background, this study introduces a novel approach by combining HBO therapy with rigorous diagnostic evaluations using both transcranial doppler (TCD) and computed tomography (CT). This dual-modality diagnostic evaluation is designed to not only assess the symptomatic relief provided by HBO ⁽¹³⁾ but also to explore its underlying effects on cerebral hemodynamics and white matter integrity. This comprehensive assessment is critical as it may reveal new insights into the pathophysiological processes of CSVD and lead to more effective treatment protocols. Our study is among the first to integrate these

diagnostic tools in the context of HBO therapy for CSVD-related dizziness, providing a new perspective on treatment efficacy and mechanism of action.

MATERIALS AND METHODS

General information

Two hundred patients with cerebral small vessel disease (CSVD)-related dizziness, admitted to our hospital from January 2019 to December 2023, were selected as the study population. Using a random number table, the patients were allocated into two groups: the Hyperbaric Oxygen (HBO) group (n=100) and the control group (n=100). The study received approval from the medical ethics committee. Inclusion criteria were as follows: (1) meeting the diagnostic criteria for CSVD confirmed by imaging examinations; (2) presenting with symptoms of dizziness, such as self-perceived visual rotation, swaying, head heaviness, unsteady gait, or a sense of head congestion; (3) age ≥ 18 years; (4) meeting indications for HBO therapy; (5) absence of cognitive impairment and psychiatric disorders, with the ability to cooperate with treatment and follow-up; (6) informed consent obtained from patients and their families. Exclusion criteria included: (1) dizziness caused by other diseases, such as benign paroxysmal positional vertigo (BPPV), Meniere's disease, or intracranial masses; (2) concomitant epilepsy or malignant tumors; (3) a history of significant head trauma or surgery; (4) severe infections or systemic immune disorders; (5) impaired liver or kidney function; (6) allergy to medications used in the study or intolerance to the treatment methods, necessitating immediate discontinuation; (7) pregnant women; (8) withdrawal from treatment without a valid reason; (9) missing clinical data. Baseline data were compared between the two groups, and no statistically significant differences were observed ($P > 0.05$) (table 1).

Table 1. Comparison of baseline data between two groups [$\bar{x} \pm s$, n (%)].

Group	Cases	Gender		Age (years)	Disease Duration (years)	Comorbidities		
		Male	Female			Hypertension	Diabetes	Hyperlipidemia
HBO Group	100	61 (61.00)	39 (39.00)	59.86 \pm 7.43	3.15 \pm 1.02	35 (35.00)	15 (15.00)	22 (22.00)
Control Group	100	53 (53.00)	47 (47.00)	61.07 \pm 8.22	2.97 \pm 0.86	29 (29.00)	19 (19.00)	18 (18.00)
t/χ^2		1.306		1.092	1.349	0.827	0.567	0.500
P		0.253		0.276	0.179	0.363	0.451	0.480

Control group

Patients in the control group were treated with Metoprolol Succinate tablets (Weicai Pharmaceutical Co., Ltd., National Medical Products Administration Approval No. H20040130, Specification: 6 mg). The dosage was 6 mg per dose, three times a day, taken orally after meals.

HBO group

On the basis of the control group, patients in the HBO group received additional Hyperbaric Oxygen (HBO) therapy. The treatment protocol was roughly as follows: Start the hyperbaric chamber, slowly pressurize within 20 minutes until reaching 0.24 MPa. Maintain stable oxygen

inhalation for 30 minutes while the patient is at 0.24 MPa, rest for 5 minutes, then resume oxygen inhalation for another 30 minutes. Slowly depressurize within 20 minutes until reaching normal pressure. Patients exit the chamber at normal pressure. This process was performed once a day. Both groups received continuous treatment for 14 days. The HBO protocol was as follows: patients received 100% oxygen at 2.5 ATA (atmospheres absolute) for 90 minutes per session, one session per day, for a total of 14 consecutive days.

Observational indicators

(1) Dizziness Symptoms: Assessment of the severity of

dizziness symptoms in enrolled patients was conducted before and after treatment using the Dizziness Handicap Inventory (DHI) ⁽¹¹⁾. The DHI consists of 25 items, primarily divided into three dimensions: physical, functional, and emotional. Scores range from 0 to 100, with higher scores indicating more severe symptoms and greater impact on daily life. DHI total scores of ≤ 30 were considered mild impairment, scores of 31-60 were considered moderate impairment, and scores ≥ 61 were considered severe impairment.

(2) TCD Parameters: Blood flow velocities and other hemodynamic parameters in major cerebral arteries were assessed using a TCD ultrasound system (Philips CX50 POC Ultrasound, USA). Before and after treatment, a TCD diagnostic instrument was used to detect changes in intracranial blood flow in enrolled patients. Patients were positioned supine and maintained in a relaxed state. Bilateral temporal windows were used as the detection points, with a probe frequency of 2 MHz and a detection depth of 50-65 mm. The peak blood flow velocities during systole and diastole of the bilateral middle cerebral arteries (MCA) were measured. The procedure was repeated three times, and the average values were calculated to obtain the mean blood flow velocity (Vm), resistance index (RI), and pulsatility index (PI). The bilateral average values were taken as the final results.

(3) Biochemical Indicators: Before and after treatment, 3 mL of fasting venous blood was collected from patients and sent to the laboratory. Cystatin (Cys), homocysteine (HCY), and high-sensitivity C-reactive protein (hs-CRP) levels were measured according to strict operational procedures. All biochemical analyses were performed in a certified laboratory with established quality controls.

(4) CT imaging examination: CT scans were performed to evaluate changes in white matter integrity, using a 64-slice CT scanner (Siemens SOMATOM Force CT scanner, USA). Patients undergo CT imaging examinations. Using CT images as the reference for grading cerebral white matter degeneration, according to the Fazekas scale for white matter lesions: Grade 0: No damage to the periventricular and centrum semiovale white matter; Grade I: Focal damage to the periventricular and centrum semiovale white matter; Grade II: Beginning of confluence of damage in the periventricular and centrum semiovale white matter; Grade III: Diffuse damage throughout the periventricular and centrum semiovale white matter, including or excluding the U fibers.

Statistical analysis

Statistic Package for Social Science (SPSS) 24.0 statistical software (IBM, Armonk, NY, USA) was used for data analysis. Measurement data, such as age, disease duration, DHI scores, Vm, RI, PI, Cys, HCY, and hs-CRP levels, were expressed as ($\bar{x} \pm s$). Independent sample t-tests were used for between-group comparisons, and paired t-tests were used for within-group comparisons. Count data, such as gender and comorbidities, were expressed as n (%), and between-group comparisons were performed using the χ^2 test. A P-value < 0.05 indicated statistical significance.

RESULTS

Comparison of DHI scores between two groups

After the intervention, the dizziness handicap inventory (DHI) scores, which assess the impact of dizziness on daily life, showed significant improvement in the HBO group compared to the control group. Specifically, the total DHI score decreased from an average of 35.01 ± 7.26 before treatment to 19.83 ± 4.75 after treatment in the HBO group ($P < 0.001$). In contrast, the control group showed a decrease from 34.85 ± 7.13 to 23.16 ± 5.07 ($P < 0.001$), indicating a more pronounced effect of HBO therapy on reducing dizziness symptoms (table 2). A typical CT of the brain in a CSVD patient was shown in figure 1. A typical TCD image of the brain in a CSVD patient was shown in figure 2.

Comparison of TCD parameters between the two groups

Transcranial Doppler (TCD) imaging was used to measure cerebral blood flow dynamics. There was no statistically significant difference in mean blood flow velocity (Vm) post-treatment between the groups ($P > 0.05$). However, resistance index (RI) and pulsatility index (PI) showed significant improvements in the HBO group. The post-treatment RI decreased from 0.79 ± 0.08 to 0.64 ± 0.07 in the HBO group, compared to a decrease from 0.81 ± 0.09 to 0.68 ± 0.09 in the control group ($P < 0.01$ for both groups, with a greater decrease in the HBO group). Similarly, PI decreased from 0.91 ± 0.16 to 0.68 ± 0.12 in the HBO group, which was a greater improvement than in the control group, where PI decreased from 0.87 ± 0.14 to 0.74 ± 0.15 ($P < 0.01$) (table 3).

Comparison of biochemical indicators between two groups

Biochemical analysis revealed a decrease in levels of cystatin C (Cys), homocysteine (HCY), and high-sensitivity C-reactive protein (hs-CRP) post-treatment. In the HBO group, Cys levels decreased from 1.63 ± 0.49 mg/L to 0.75 ± 0.18 mg/L, HCY from 9.86 ± 2.37 μ mol/L to 7.63 ± 1.19 μ mol/L, and hs-CRP from 5.24 ± 1.08 mg/L to 1.73 ± 0.42 mg/L. These changes were statistically significant when compared to the control group, where the decreases were less pronounced ($P < 0.05$ for all comparisons) (table 4).

DHI among different groups of cerebral white matter lesions

MRI findings were quantitatively assessed using the Fazekas scale for cerebral white matter lesions. The results correlated white matter lesion severity with DHI scores. Patients in the HBO group consistently showed lower DHI scores across all grades of lesion severity, suggesting better management of dizziness symptoms even in more severe cases. Specifically, the order of DHI scores

from low to high severity was Grade 0 <Grade I <Grade II <Grade III, with each step increase in lesion grade showing a statistically significant increase in DHI score ($P<0.05$). This trend was more pronounced

in the HBO group compared to the control group, highlighting the effectiveness of HBO in patients with varying degrees of white matter degradation (table 5).

Table 2. Comparison of DHI Scores between Two Groups ($\chi \pm s$, points).

Group	Cases	Physical		Functional		Emotional		Total scores	
		Before Treatment	After Treatment	Before Treatment	After Treatment	Before Treatment	After Treatment	Before Treatment	After Treatment
HBO Group	100	10.04±1.37	5.48±1.17*	14.82±3.15	9.35±2.16*	12.08±3.76	7.04±1.53*	35.01±7.26	19.83±4.75*
Control Group	100	9.86±1.24	6.09±1.25*	15.09±3.22	10.84±2.37*	11.97±3.54	8.26±1.94*	34.85±7.13	23.16±5.07*
t		0.974	3.563	0.599	4.647	0.213	4.938	0.157	4.793
P		0.331	0.001	0.550	<0.001	0.832	<0.001	0.875	<0.001

Note: * $P<0.05$ compared with the same group before treatment.

Table 3. Comparison of TCD Parameters between the Two Groups ($\chi \pm s$).

Group	Cases	Vm (cm/s)		RI		PI	
		Before Treatment	After Treatment	Before Treatment	After Treatment	Before Treatment	After Treatment
HBO Group	100	39.74±2.38	53.29±6.14*	0.79±0.08	0.64±0.07*	0.91±0.16	0.68±0.12*
Control Group	100	40.16±2.55	51.76±5.83*	0.81±0.09	0.68±0.09*	0.87±0.14	0.74±0.15*
t		1.204	1.807	1.661	3.508	1.881	3.123
P		0.230	0.072	0.098	0.001	0.061	0.002

Note: compared with the same group before treatment. * $P < 0.05$

Table 4. Comparison of Biochemical Indicators between Two Groups ($\chi \pm s$).

Group	Cases	Cys (mg/L)		HCY (μmol/L)		hs-CRP (mg/L)	
		Before Treatment	After Treatment	Before Treatment	After Treatment	Before Treatment	After Treatment
HBO Group	100	1.63±0.49	0.75±0.18	9.86±2.37	7.63±1.19*	5.24±1.08	1.73±0.42
Control Group	100	1.57±0.42	0.91±0.22	10.15±2.44	8.24±1.36*	5.36±1.17	1.98±0.65
t		0.930	5.629	0.853	3.376	0.754	3.230
P		0.354	<0.001	0.395	0.001	0.452	0.001

Note: compared with the same group before treatment. * $P < 0.05$

Table 5. Comparison of the DHI scores between the two study groups.

Group	Control Group	HBO Group			
		Fazekas Scale 0	Fazekas Scale I	Fazekas Scale II	Fazekas Scale III
DHI Scores	23.16±5.07	21.21±3.12	21.01±3.67	19.83±4.06	18.36±4.15
t		3.276	3.435	5.127	4.793
P		0.001	<0.001	<0.001	<0.001

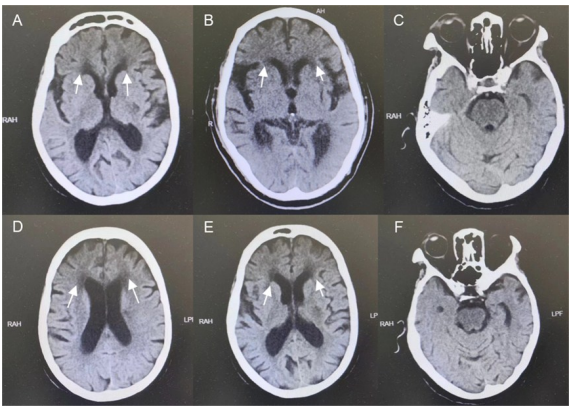


Figure 1. CT image of the brain in typical CSVD patients. A, B, and C are from a 64-year-old patient with CSVD, and E, F, and G are from another 72-year-old patient with CSVD. The arrows demonstrate the lesion areas in the images. CSVD: cerebral small vessel disease.

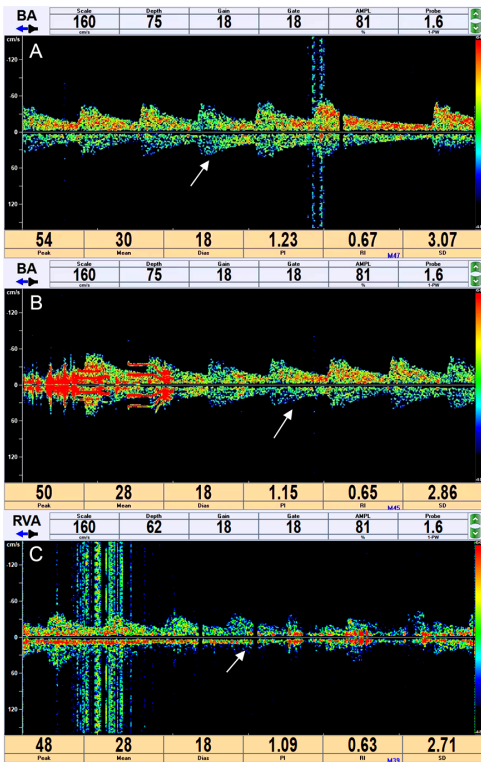


Figure 2. TCD image of the brain in a typical CSVD patient. A is from a TCD image of a 66-year-old patient. B is from a TCD image of a 58-year-old patient. C is from a TCD image of a 61-year-old patient. The numbers above and below the images demonstrate the patient's blood flow parameters. The arrows demonstrate the lesion areas in the images. TCD: transcranial Doppler. CSVD: cerebral small vessel disease.

DISCUSSION

In the past, cerebral small vessel disease (CSVD) was mostly found in the elderly population. However, recent research has indicated a trend of CSVD occurring at a younger age⁽¹⁴⁾. Many CSVD patients exhibit symptoms such as dizziness and balance disorders, significantly impacting their quality of life and prognosis. The etiology of CSVD-related dizziness is multifaceted, involving factors such as age, inflammatory cell infiltration, underlying conditions like hypertension and diabetes, unhealthy lifestyle habits such as smoking and excessive alcohol consumption, as well as psychosocial factors^(15,16). Aging can lead to arterial sclerosis and reduced vestibular function, causing a decline in the perception of self-movement, spatial orientation, and integration of balance control, leading to dizziness. The pathological mechanisms of CSVD-related dizziness are not fully understood, but it may be related to white matter lesions⁽¹⁷⁾. Compared to other forms of CSVD, dizziness symptoms are more common in patients with white matter damage⁽¹⁸⁾. It may also be associated with hemodynamic changes, as vascular lesions in small brain vessels, without collateral circulation supplying arterial blood flow, can significantly reduce cerebral tissue perfusion, disrupt the blood-brain barrier, and increase the risk of dizziness⁽¹⁹⁾.

Observing the research results, it is evident that the Dizziness Handicap Inventory (DHI) scores in each dimension and the total score for the HBO group were lower than those for the control group after treatment ($P < 0.05$). This indicates that HBO-assisted treatment can effectively reduce DHI scores, improving dizziness symptoms in CSVD patients. Moreover, the addition of CT imaging for grading cerebral white matter degeneration according to the Fazekas scale offers a novel perspective on the structural changes in the brain that may correlate with the severity of dizziness symptoms. After treatment, the levels of Cystatin C (Cys), homocysteine (HCY), and high-sensitivity C-reactive protein (hs-CRP) in both groups were lower than before, and the HBO group was lower than the control group ($P < 0.05$). Cys is a metabolic indicator that has a certain predictive value for the progression of CSVD, with its levels being related to the severity of CSVD⁽²⁰⁾. HCY levels are significantly correlated with the severity of white matter lesions in CSVD patients, and HCY can disrupt the structure of vascular endothelial cells, leading to increased vascular permeability and arterial sclerosis. Hs-CRP is an inflammatory factor that can induce atherosclerosis, increase blood viscosity, reduce cerebral perfusion, gradually cause ischemia and hypoxia in brain tissue, and eventually develop into CSVD⁽²¹⁾. Therefore, HBO-assisted treatment for CSVD-related dizziness patients is beneficial for reducing vascular and tissue damage, promoting neurological function recovery.

CONCLUSION

In conclusion, the inclusion of CT imaging and white matter lesion grading based on the Fazekas scale enriches

our understanding of HBO's therapeutic mechanisms, emphasizing its role in addressing structural brain changes associated with CSVD. Nevertheless, the limitations of our study, including the homogeneity of the sample and the short duration of follow-up, necessitate further research. Longitudinal studies with diverse populations and extended monitoring are required to validate and expand upon these results.

ACKNOWLEDGMENT

None.

Conflict of Interests: The authors declared no conflict of interest.

Funding: This study did not receive any funding in any form.

Ethical considerations: This study was approved by the ethics committee of Shanghai Construction Engineering Hospital (Approval no. 21-419). Signed written informed consents were obtained from the patients and/or guardians.

Author' contributions: YW and JY designed the study and performed the experiments, YW and QW collected the data, JY and QW analyzed the data, YW and JY prepared the manuscript. All authors read and approved the final manuscript.

REFERENCES

1. Litak J, Mazurek M, Kulesza B, et al. (2020) Cerebral Small Vessel Disease. *International Journal of Molecular Sciences*, **21**(24): 9729.
2. Li Q, Yang Y, Reis C, et al. (2018) Cerebral Small Vessel Disease. *Cell Transplantation*, **27**(12): 1711-1722.
3. van den Brink H, Doubal FN, Düring M (2023) Advanced MRI in cerebral small vessel disease. *International Journal of Stroke*, **18** (1): 28-35.
4. Zanon ZM, Sveikata L, Viswanathan A, Yilmaz P (2021) Cerebral small vessel disease and vascular cognitive impairment: from diagnosis to management. *Current Opinion in Neurology*, **34**(2): 246-257.
5. Liu Y, Dong YH, Lyu PY, Chen WH, Li R (2018) Hypertension-Induced Cerebral Small Vessel Disease Leading to Cognitive Impairment. *Chinese Medical Journal*, **131**(5): 615-619.
6. Benveniste H and Nedergaard M (2022) Cerebral small vessel disease: A glymphopathy? *Current Opinion in Neurobiology*, **72**: 15-21.
7. Chen X, Wang J, Shan Y, et al. (2019) Cerebral small vessel disease: neuroimaging markers and clinical implication. *Journal of Neurology*, **266**(10): 2347-2362.
8. Bordes C, Sargurupremraj M, Mishra A, Debetto S (2022) Genetics of common cerebral small vessel disease. *Nature Reviews Neurology*, **18**(2): 84-101.
9. Low A, Mak E, Rowe JB, Markus HS, O'Brien JT (2019) Inflammation and cerebral small vessel disease: A systematic review. *Ageing Research Reviews*, **53**: 100916.
10. Thrippleton MJ, Backes WH, Sourbron S, et al. (2019) Quantifying blood-brain barrier leakage in small vessel disease: Review and consensus recommendations. *Alzheimers & Dementia*, **15**(6): 840-858.
11. Markus HS (2021) Cerebral small vessel disease: Microbleeds, perforator artery imaging and clostozol. *International Journal of Stroke*, **16**(9): 1000-1001.
12. Zwanenburg J and van Osch M (2017) targeting cerebral small vessel disease with MRI. *Stroke*, **48**(11): 3175-3182.
13. Ter Telgte A, van Leijsen E, Wiegertjes K, Klijn C, Tuladhar AM, de Leeuw FE (2018) Cerebral small vessel disease: from a focal to a global perspective. *Nature Reviews Neurology*, **14**(7): 387-398.
14. Blumen HM, Jayakody O, Verghese J (2023) Gait in cerebral small vessel disease, pre-dementia, and dementia: A systematic review. *International Journal of Stroke*, **18**(1): 53-61.

15. Wang J, Wang B, Wang K (2023) Review of neuroimaging research progress of cerebral small vessel disease. *Folia Neuropathologica*, **61**(1): 1-7.
16. Shi Y, Thrippleton MJ, Makin SD, *et al.* (2016) Cerebral blood flow in small vessel disease: A systematic review and meta-analysis. *Journal of Cerebral Blood Flow and Metabolism*, **36**(10): 1653-1667.
17. Mancuso M, Arnold M, Bersano A, *et al.* (2020) Monogenic cerebral small-vessel diseases: diagnosis and therapy. Consensus recommendations of the European Academy of Neurology. *European Journal of Neurology*, **27**(6): 909-927.
18. Backhouse EV, Boardman JP, Wardlaw JM (2024) Cerebral small vessel disease: early-life antecedents and long-term implications for the brain, aging, stroke, and dementia. *Hypertension*, **81**(1): 54-74.
19. Pinter D, Enzinger C, Fazekas F (2015) Cerebral small vessel disease, cognitive reserve and cognitive dysfunction. *Journal of Neurology*, **262**(11): 2411-2419.
20. Grochowski C, Litak J, Kamieniak P, Maciejewski R (2018) Oxidative stress in cerebral small vessel disease. Role of reactive species. *Free Radical Research*, **52**(1): 1-13.
21. Hainsworth AH, Oommen AT, Bridges LR (2015) Endothelial cells and human cerebral small vessel disease. *Brain Pathology*, **25**(1): 44-50.