

Pancreatic adenocarcinoma in a patient with relapsed Hodgkin's lymphoma

G.Yavas^{1*}, M. Araz², C. Yavas³, F. Baba⁴, O. Ata²

¹Selcuk University, Selcuklu Faculty of Medicine, Department of Radiation Oncology, Konya, Turkey

²Selcuk University, Selcuklu Faculty of Medicine, Department of Medical Oncology, Konya, Turkey

³Konya Training and Research Hospital, Department of Radiation Oncology, Konya, Turkey

⁴Selcuk University, Selcuklu Faculty of Medicine, Department of Pathology, Konya, Turkey

► Case report

ABSTRACT

After curative treatment of Hodgkin's lymphoma, increased risk of certain solid tumors has been reported. To best of our knowledge this is the first report of metachronous pancreatic adenocarcinoma which developed outside the previous radiation field in a patient with relapse Hodgkin's lymphoma. Herein we present an 81-year-old female who developed pancreatic adenocarcinoma four years after the curative treatment of Hodgkin's lymphoma.

Keywords: Hodgkin's disease, Metachronous, Pancreas adenocarcinoma, Radiotherapy.

*Corresponding author:

Dr. Guler Yavas,

Fax: +90 332 2417791

E-mail:

guler.aydinyavas@gmail.com

Received: Dec. 2011

Accepted: May 2012

Int. J. Radiat. Res., July 2013;
11(3): 195-198

CASE PRESENTATION

The patient was a 77-year-old woman who was diagnosed to have Hodgkin's Lymphoma (HL) stage IIB in 2007. She presented with bilateral cervical lymphadenopathy (LAP). There wasn't any other LAP and distant metastasis, including the bone marrow. The diagnosis was confirmed by excisional biopsy of the right cervical LAP, which revealed HL of the mixed cellular type (figure 1). Immunohistochemical examination revealed tumor cells positive for CD-45, CD-20 and focally positive for CD-3 and negative for CD-15 and BCL-1.

The patient received four-cycles of Cyclophosphamide, Vincristine and Prednisolone (CVP) and achieved complete response. A dosage of 3000 cGy radiotherapy with 2 Gy/fraction was applied to bilateral neck and supraclavicular fossa. Then, she was followed-up at regular intervals.

In May 2011, at the age of 81-year, she complained of upper abdominal pain and anorexia. She had lost 5 kilograms within two months, which was 10% of her total body weight. Physical examination revealed abdominal tenderness. The abdominal computed tomography (CT) and magnetic resonance imaging (MRI) revealed a 8.5x5x5 cm mass located on the corpus and tail of the pancreas, a left para-aortic 18x12 mm LAP and multiple hypodense nodules in the spleen (figure 2a and 2b). The initial diagnosis of the patient was a relapse HL. However, due to high serum Ca-19-9 levels, which was 592.33 U/ml (0-30.9), and a pancreatic mass, we performed fine needle aspiration biopsy in order to exclude primary pancreatic cancer. The histopathology was nonspecific. She received 2-cycles of Adriamycin, Bleomycin, Vinblastine and Dacarbazine (ABVD). Then, in order to see the response to the treatment we repeated the abdominal CT, which revealed a near complete response in all other

sites except for the progressive pancreatic mass (figure 3a and 3b). The true-cut-biopsy of the pancreatic mass disclosed a primary pancreatic adenocarcinoma (figure 4). We completed ABVD

to four-cycles and then focused on the treatment of pancreatic adenocarcinoma, which was the curative radiotherapy.

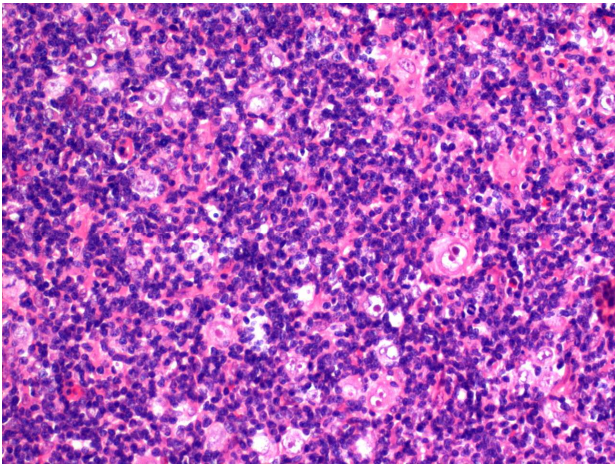


Figure 1. H and E staining (20X): Section from the right cervical LAP reveals Reed-Sternberg cell (arrow) and multiple lymphocytic and histiocytic cells with mature lymphoid background consisting eosinophil leukocytes.

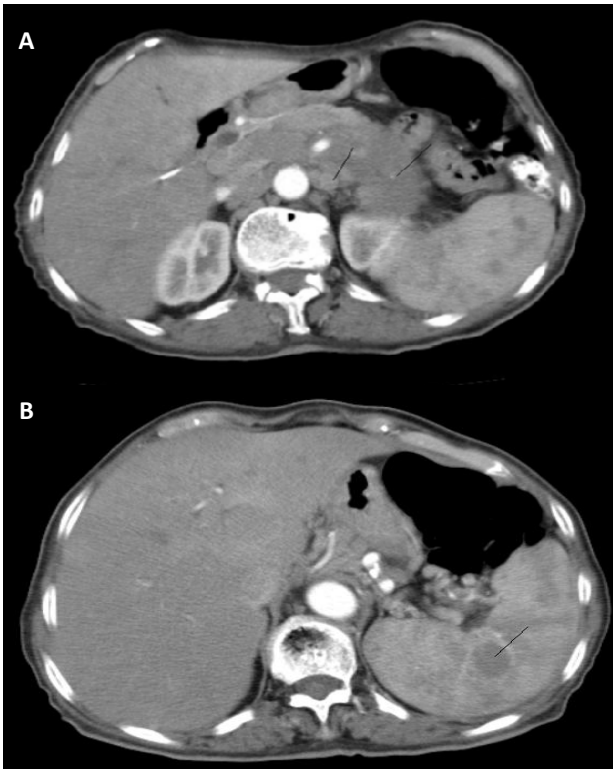


Figure 2. Axial CT scan before the Adriamycin, Bleomycin, Vinblastine and Dacarbazine chemotherapy: A) Showing pancreatic mass and a left para-aortic lymph node. B) Showing a splenic nodule which was 20 mm in diameter.

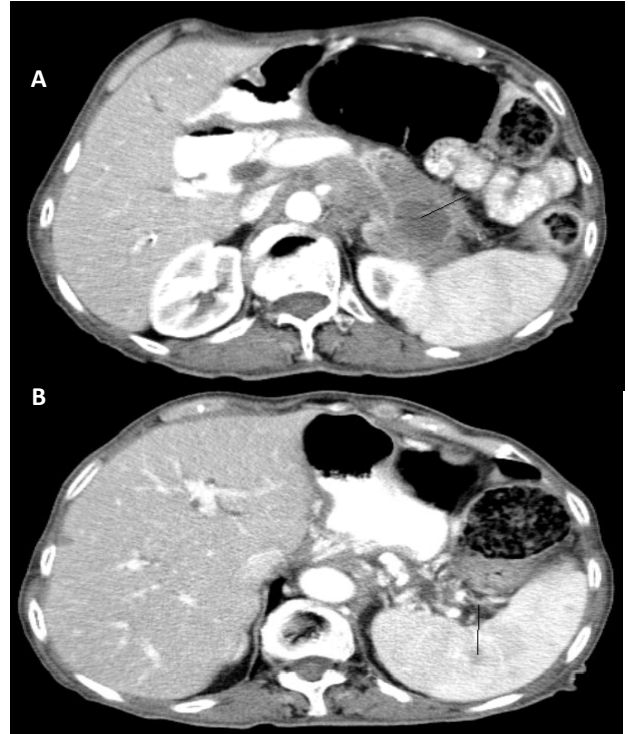


Figure 3. Axial CT scan after the Adriamycin, Bleomycin, Vinblastine and Dacarbazine (ABVD) chemotherapy: A) Showing the progressive mass located on the tail of the pancreas. Left para-aortic lymph node was completely disappeared. B) Showing a splenic nodule which was regressed to 7 mm after ABVD chemotherapy.

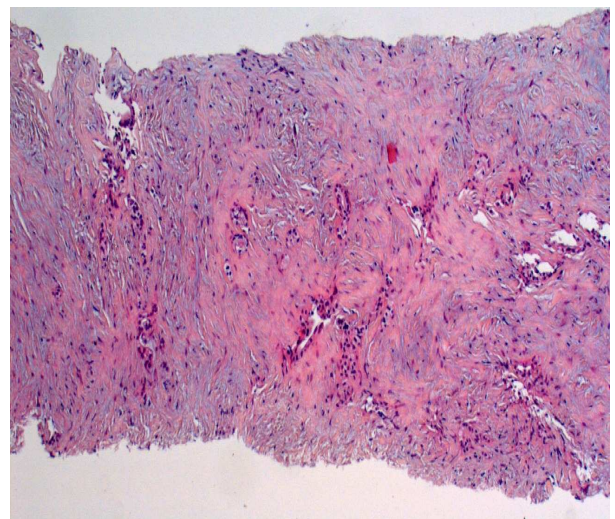


Figure 4. H and E staining (5X): Section from the pancreatic mass showing desmoplastic fibrous tumor stroma with atypical acini.

DISCUSSION

The development of secondary malignancies after treatment for HL is now well established (1-3). The most common secondary malignancy after the treatment of HL is acute myelogenous leukemia. It is associated with the administration of alkylating agents. Solid malignancies including gastric adenocarcinoma, lung cancer, breast cancer, testicular cancer, colon cancer, basal cell cancer and osteosarcoma have been also reported (4-9). It has been also shown that patients receiving chemotherapy and radiotherapy have a significantly higher risk of developing solid tumors than those receiving chemotherapy alone (1-3, 10). Radiation is a well known carcinogen and it is usually associated with solid tumors. However, to characterize a human solid tumor as radiation induced, three criteria must be fulfilled; (i) tumor must occur in the radiation field, (ii) tumor must appear after a latent period and (iii) the tumor must be histologically distinct from the previous neoplasm (11). There are some studies in the literature reporting the development of pancreatic carcinoma after treatment of HL (12, 13). However, in all these studies, pancreatic carcinoma has been developed in the previous radiation field of HL, indicating that it was related to previous radiation treatment, and met all these three criteria. To best of our knowledge, the current case is the first case of metachronous pancreatic carcinoma occurring outside the previous radiotherapy field in patients with HL in the literature. Our case is also unique in the sense that when pancreatic mass appeared, patient had also relapsed HL at abdominal region.

Four-years after the treatment for HL, our patient had recurrent disease findings including weight loss and a mass located on the corpus and tail of the pancreas, a left para-aortic LAP and multiple hypodense nodules located in the spleen in abdominal CT. Since the radiologic appearance of the pancreatic mass was not consistent with pancreatic involvement of lymphoma and serum Ca 19-9 levels were high, we suspected from a primary pancreatic carcinoma. The aspiration biopsy from the mass was not diagnostic. During this time period,

patient received 2 cycles of ABVD as a salvage treatment for recurrent HL. Repeated abdominal tomography was consistent with relapsed HL. It revealed a near complete response in the left para-aortic lymph node and splenic nodules except for the progressive pancreatic mass. Despite this achieved response, serum Ca 19-9 levels continued to increase. The exact histopathological diagnosis was reached by tru-cut biopsy which revealed pancreatic adenocarcinoma.

In the present case, second malignancy had been developed after a latent period that was sufficient for radiation related tumor. However; the tumor was developed outside the previous radiation field. Therefore we thought that it was not related to the previous RT. On the other hand chemotherapeutic agents used for HL or genetic susceptibility and environmental risk factors could not be excluded from the etiology of the pancreatic adenocarcinoma.

In our patient, pancreatic adenocarcinoma developed at the time of HL relapse and it was just a coincidence. Initially we thought the pancreatic mass as HL involvement. However after ABVD chemotherapy, pancreatic mass was enlarged and serum Ca 19-9 levels increased. Although the first biopsy which was taken from the pancreatic mass was not diagnostic, we repeated the biopsy. And it revealed the pancreatic adenocarcinoma. This coincidence did not delay the treatment of pancreatic adenocarcinoma. Because after we finished ABVD chemotherapy, we immediately focused the treatment of pancreatic adenocarcinoma.

HL survivors who developed relapse findings must be carefully evaluated. In these cases, as our presented case, beside radiological appearance of the lesion and tumor markers, the response to treatment of relapsed disease can also be a clue for differential diagnosis. However, the exact diagnosis must be reached by histopathological examination.

Conflict of interest

The authors declare that they have no conflict of interest.

REFERENCES

1. Tucker MA, Coleman CN, Cox RS, Varghes A, Rosenberg SA (1988) Risk of second cancers after treatment for Hodgkin's disease. *N Eng J Med*; **318**: 76-81.
2. Swerdlow AJ, Douglas AJ, Vaughan Hudson G, Vaughan Hudson B, Bennett MH, Maclennan KA (1992) Risk of second primary cancers after Hodgkin's disease by type of treatment: Analysis of 2846 patients in the British national lymphoma investigation. *Br Med J*, **304**: 1137-1143.
3. Van Leeuwen FE, somers R, Taac BG, Van Heerde P, Coster B, Dozeman T et al (1989) Increase risk of lung cancer, non-Hodgkin lymphoma and leukemia following Hodgkin's disease. *J Clin Oncol* **7**: 1046-1058.
4. Tardivon AA, Garnier ML, Beaudré A, Girinsky T (1999) Breast carcinoma in women previously treated for Hodgkin's disease: clinical and mammographic findings. *Eur Radiol*, **9**: 1666-71.
5. Porta C, Moroni M, Nastasi G (1994) Metachronous occurrence of seminoma and Hodgkin's lymphoma in the same patient with late-onset colon cancer. *J Intern Med.*; 236: 91-2.
6. Bisi D, Federico M, Sarti M, barbieri F, Curci G (1989) The onset of double metachronous neoplasms 29 years after the diagnosis of Hodgkin's disease. *Minerva Med*, **80**: 511-514.
7. List AF, Doll DC, Greco FA (1985) Lung cancer in Hodgkin's disease: association with previous radiotherapy. *J Clin Oncol*, **3**: 215-221.
8. Yalçintaş Arslan U, Öksüzöğlü B, Onder FO, Irkkan C, Üyetürk U, Gökbayrak N, Alkış N (2011) Concomitant Hodgkin's lymphoma and gastric adenocarcinoma: a rare coincidence. *Med Oncol. Mar*, **28**: 251-4.
9. De S, Ghosh S, Mondal D, Sur PK (2010) Osteosarcoma of the mandible--second cancer in a case of Hodgkin's lymphoma post-chemotherapy. *J Cancer Res Ther*, **6**: 336-8.
10. Abrahamsen JF, Anderson A, Hannisdal E, Nome O, Abrahamsen AF, Kvaloy S, et al. (1993) Second malignancies after treatment of Hodgkin's disease follow-up time, and age. *J Clin Oncol* **11**: 255-261.
11. Fajardo L-G FL (1982) Radiation-induced versus radiation associated neoplasms. In: Stenberg SS editor. Pathology of radiation injury. New York: Mason: 252-254.
12. Lambert C, Benk V, Freeman CR (1998) Pancreatic cancer as a second tumour following treatment of Hodgkin's disease. *Br J Radiol*, **71**: 229-232.
13. Deutsch M, Rosenstein MM, Ramanathan RK (1999) Pancreatic cancer in a young after treatment for Hodgkin's disease. *Clin Oncol*, **11**: 280-282.