

Radiation induced testicular injury and its amelioration by *Prunus domestica* in Swiss albino mice

G. Sharma¹, R. Sisodia^{1*}, E. Meghnani²

¹Neurobiology lab, Department of Zoology, University of Rajasthan, Jaipur, India

²Mahatma Gandhi Institute of Applied Sciences, Jaipur, India

ABSTRACT

► Original article

*** Corresponding author:**

Dr. Rashmi Sisodia,

Fax: + 91 141 27111458

E-mail: rashsiodia@yahoo.co.in

Revised: Jan. 2014

Accepted: Feb. 2014

Int. J. Radiat. Res., January 2015;
13(1): 45-54

DOI: 10.7508/ijrr.2015.01.006

Background: The increasing use of nuclear radiation for human welfare necessitates the search for new, safe, cost effective radio protectors not only for the personnel's charged with the responsibility of working or testing with radiations in laboratories, but also for general public. With this view the present study has been undertaken to determine the deleterious effects of sub lethal gamma radiation on testes and its modulation by *Prunus domestica* extract (PDE). **Material and Methods:** For this purpose Swiss albino mice were divided into five groups: (1) Control (2) PDE treated (400 mg kg⁻¹ day⁻¹ for 15 days) (3) Irradiated (5 Gy) (4) PDE + Irradiated and (5) Irradiated+PDE treated. Antioxidant and biochemical assays as well as histopathological analysis were performed to verify PDE radioprotective potential. **Results:** Radiation induced histological lesions in testicular architecture were observed more severe in all experimental groups. PDE administration before irradiation significantly ameliorated radiation induced elevation in lipid peroxidation and deficit in glutathione, protein, superoxide dismutase, catalase concentration in testes. PDE was found to have strong radical scavenging activity in 2,2-diphenyl-1-picrylhydrazyl (DPPH*) and also showed *in vitro* radioprotective activity. **Conclusion:** The results indicate the radioprotective potential of *Prunus domestica* fruit extract in testicular constituents against gamma irradiation in mice.

Keywords: *Prunus domestica*, Irradiation, Radioprotection, Antioxidant, Lipid peroxidation.

INTRODUCTION

The threat of accidental or hostile exposure to radiation is of great concern. This necessitates the search for new, safe, cost effective radio protectors for one and all. Ionizing radiations inflicts their adverse effects through the generation of oxidative stress that unleash large-scale destruction or damage of various biomolecules. In testis, for example, developing germ cells, in addition to undergoing complex cellular changes, must migrate progressively from basal to the adluminal compartment of the seminifer-

ous epithelium where elongate spermatids are eventually released into the tubular lumen during spermiation^(1,2). This makes testes a highly radiosensitive organ with wide range of radiosensitive germ cells. Medicines derived from plants have played a pivotal role in health care of ancient and modern cultures. Current estimate indicates that about 80% of people in developing countries still rely on traditional medicinal plant-based remedies to meet their primary healthcare⁽³⁾. Vitamin C has been reported to prevent cellular damage in mouse spermatogenesis process induced by radiations⁽⁴⁾. Some medicinal fruits have been trialed for

their antiradiation property and many of them are found to be useful^(5,6). In this context, *Prunus domestica* (Plums) (family Rosaceae) commonly known as Alu bukhara, which has been used as a traditional medicinal food in humans to enhance immunity against infectious agents, has been used for exploring its antiradiation effect. This fruit contains immunostimulatory components that potentially may be useful in human and veterinary medicine. *Prunus domestica* (Plums) are fruits rich in phenolic compounds, characterized by relatively high antioxidant activity, higher than e.g. oranges, apples or strawberries^(7,8). The fruit contain anthocyanins (type cyanidin-3- glucoside and cyanidine-3-rutinoside) and flavanols (catechin)⁽⁹⁾. According to nutrient database, 100 grams of edible portion of fruits of *Prunus domestica* has Protein 4.1g, fat 4.9g, carbohydrate 11.1g, minerals and fibre 0.4g, calcium 10mg, phosphorus 12mg, iron 0.6mg, magnesium 147mg, sodium 0.8g, potassium 247g, copper 0.13g, sulphur 33mg, carotene (Vit A) 166 µg, thiamine (Vit. B1) 0.04mg, riboflavin (Vit. B) 0.1mg, niacin 0.3mg, vitamin C 5mg and oxalic acid 1mg⁽¹⁰⁾. According to Mahmood *et al.*⁽¹¹⁾ hentricontane, ethyl hexadecanoate and linoleic acid were identified in n-haxene extract of *Prunus domestica*. Bioassay screening of oil showed moderate antibacterial activity against salmonella group (Gram+ve and -ve) by agar well diffusion method, moderate antifungal activity against *Microsporum canis* by agar tube dilution method and good antioxidant activity by DPPH radical scavenging method. Sisodia and Sharma, 2012⁽¹²⁾ studied free radicals scavenging activity of fruit extract of *Prunus domestica* and the deficits in spatial learning after irradiation and its modulation by *Prunus avium* in *Swiss albino* mice.

MATERIALS AND METHODS

Extract preparation

Fresh fruits of *Prunus domestica* were washed, shade dried and powdered after removal of seeds. Methanolic extract was then prepared by refluxing for 48 hours (4 × 12) at 50°C. The extract thus obtained was vacuum-

evaporated so as to achieve powdered form. The extract was redissolved in doubled-distilled water (DDW) just before the oral administration.

Mice

The animal care and handling was done according to the guide-lines set by INSA (Indian National Science Academy, New Delhi, India). The Departmental Animal Ethical Committee (DAEC) approved this study. Six weeks adult male *Swiss albino* mice, weighing 25 ± 2 g, from an inbred colony were used for the present study. These mice were maintained under controlled conditions of temperature and light (light: dark, 10h:14h). Four mice were housed in polypropylene cages containing sterile paddy husk (procured locally) as bedding throughout the experiment. They were provided standard mouse feed (procured from Hindustan Levers Ltd, India) and water *ad libitum*.

Source of irradiation

The cobalt teletherapy unit (ATC-C9) at Cancer Treatment Center, Radiotherapy Department, SMS Medical College and Hospital, Jaipur, Rajasthan, India was used for irradiation. Unanaesthetized mice were restrained in well-ventilated Perspex boxes and whole body exposed to gamma radiation at a source-to-skin distance (SSD) of 77.5 cm from the source to deliver the dose rate of 1.07 Gy/min.

Antioxidative assay

Preparation of DPPH

2, 2'-diphenyl-1-picrylhydrazyl (DPPH; C18H12N5O6; Hi media) 0.8 mg was dissolved in 10ml methanol to obtain a concentration of 0.08 mg/ml for antioxidative (qualitative and quantitative) assay⁽¹³⁾.

Qualitative and quantitative assay

10 mg extract was dissolved in 10 ml of its suitable solvent to get a concentration of 1mg/ml and from this 0.25 µl was taken, applied on silica gel G plates, sprayed with DPPH solution and allowed to stand for 30 minutes. The change in the colour (from deep-violet to light-yellow) was recorded at 517 nm on a UV spectrophotometer (Varian Cary PCB 150, Water Peliter System). A concentration of 1mg/ml of ethanolic

extract of each test sample was prepared to obtain different concentrations (102 - 103 µg/ml), out of which 2.5 ml was mixed with 2.5 ml of DPPH. The samples were kept in dark for 15 min at room temperature and the decrease in absorption was measured (at 517 nm) against a blank. The experiments were done in triplicates and the mean was taken for each concentration. Data were processed and concentration that caused 50% reduction in absorbance (IC₅₀) was calculated. The same procedure was also followed for the standards of quercetin and ascorbic acid.

Experimental design for radioprotective study

Mice were randomly divided into five groups (fifteen in each group) for biochemical, histopathological studies.

Group I (Control): Mice of this group received double distilled water for 15 days.

Group II (Only PDE): Mice of this group were supplemented PDE orally once every day for fifteen consecutive days at optimum dose (400 mg/kg bwt/d) dissolved in double distilled water.

Group III (Irradiated): Mice in this group received double distilled water, which equaled to the dose of extract for fifteen days and then exposed to whole body γ -irradiation at the dose of 5 Gy.

Group IV (PDE+ Irradiation): Mice were supplemented orally with PDE at optimum dose (400 mg/kg bwt/d) for fifteen consecutive days and then exposed to 5 Gy whole body irradiation.

Group V (Irradiation +PDE): Mice in this group were exposed to 5Gy whole body γ -irradiation and then supplemented orally with PDE at the optimum dose (400 mg/kg bwt/d) for 15 consecutive days.

Animals from each group were necropsied by cervical dislocation at various intervals viz 1-30 days post treatment. Testis was removed for various biochemical estimations and histopathological studies

Biochemical assay

Lipid peroxidation (LPO) assay

LPO was measured by the method of Buege

and Aust ⁽¹⁴⁾. Briefly, tissue homogenate was mixed with TCA-TBA-HCl and was heated for 15 min in a boiling water bath. After centrifugation the absorbance was recorded at 535 nm using a UV Vis double beam spectrophotometer. The LPO has been expressed as MDA in n mole/ gm tissue.

Reduced glutathione (GSH) assay

Spectrophotometric quantification of reduced glutathione (GSH) has been carried out using 5, 5-dithiobis- (2-nitrobenzoic acid) (DTNB) reagent according to the method proposed by Moron *et al.* ⁽¹⁵⁾. Briefly, 200 µl of tissue homogenate (20%) was added to 800 µl distilled water and then 2 ml of sodium phosphate-EDTA buffer (0.1 M sodium phosphate, 0.005 M EDTA buffer, pH 8.0), containing 0.6 M DTNB were added. The optical density of the yellow colored complex developed by the reaction of GSH and DTNB was measured at 412 nm using a UV-vis spectrophotometer.

Super oxide dismutase

Super oxide dismutase was assayed by method of Marklund and Marklund ⁽¹⁶⁾. Which involves inhibition of pyrogallol auto-oxidation at PH 8.0? A single unit of enzyme is defined as the quantity of superoxide dismutase required to produce 50% inhibition of auto-oxidation. The absorbance was read at 420 nm with a UV-VIS systronics spectrophotometer.

Catalase

It was estimated in the testis homogenate as described by Aebi ⁽¹⁷⁾. The reaction mixture (1 ml, vol.) contained 0.02 ml of suitably diluted cytosol in phosphate buffer (50 Mm. Ph 7.0) and 0.1 ml of 30 Mm H₂O₂ in phosphate buffer. The specific activity of catalase has been expressed as µ moles of H₂O₂ consumed /min/mg protein. The difference in absorbance at 240 nm per unit time is a measure of catalase activity done by in a UV-VIS spectrophotometer.

Histopathological analysis

Testes were surgically removed at each autopsy interval from the necropsied animals of each group and weighed. One part of it was fixed in

Bouin's fluid, and slides were prepared by routine procedure and stained with Hematoxylin and Eosin. Histological alterations in the testicular architecture were observed in the seminiferous tubules.

Statistical analysis

The results obtained in the present study were expressed as mean ± SEM. The statistical differences between various groups were analyzed by the student's *t*-test (SPSS software) and the significance was observed at the $p < 0.001$, $p = 4.45$ and $p = 4.49$ level. The following groups were compared by student's *t* test: (a) control versus PDE treated, (b) control versus irradiated, (c) irradiated versus PDE treated + irradiated, (d) irradiated versus irradiated + PDE treated.

RESULTS

Antioxidant efficacy of *Prunus domestica*

Radical scavenging (antioxidant) activity of methanolic extract of *Prunus domestica* - IC₅₀ was computed to be 6µg/ml whereas the ascorbic acid has 4µg/ml, which shows that the antioxidant activity of the methanolic extract of *Prunus domestica* is comparable to the ascorbic acid (figure 1).

Optimum dose selection and Dose Reduction Factor (DRF)

Different doses of PDE (100-1200) given were found to be non toxic and no mortality was observed till day 30. An optimum dose 400 mg/kg b wt was selected against 5 Gy gamma radiation. On the basis of maximum survivability a LD_{50/30} values for control (irradiated alone) and experimental (PDE +irradiation) were computed as 2.36 and 3.77 Gy, respectively. DRF value was calculated as 1.59 Gy⁽¹²⁾.

Biochemical assay result

LPO

Lipid-peroxidation level in testes was found to be significantly ($p < 0.001$) higher in irradiated animals (Group III) at all autopsy intervals as compared to control (group I). LPO level also increased in PDE pre treated irradiated animals up to day 7 but the values were significantly ($p < 0.001$) lower than their respective irradiated controls. PDE-treated-irradiated group IV and V attended the normal level of TBARS level at day 30 post-treatment. Only PDE treated mice decreases TBARS level but not statistically significant (figure 2).

GSH

Significant difference ($p < 0.05$) in the GSH content of testes was observed between control

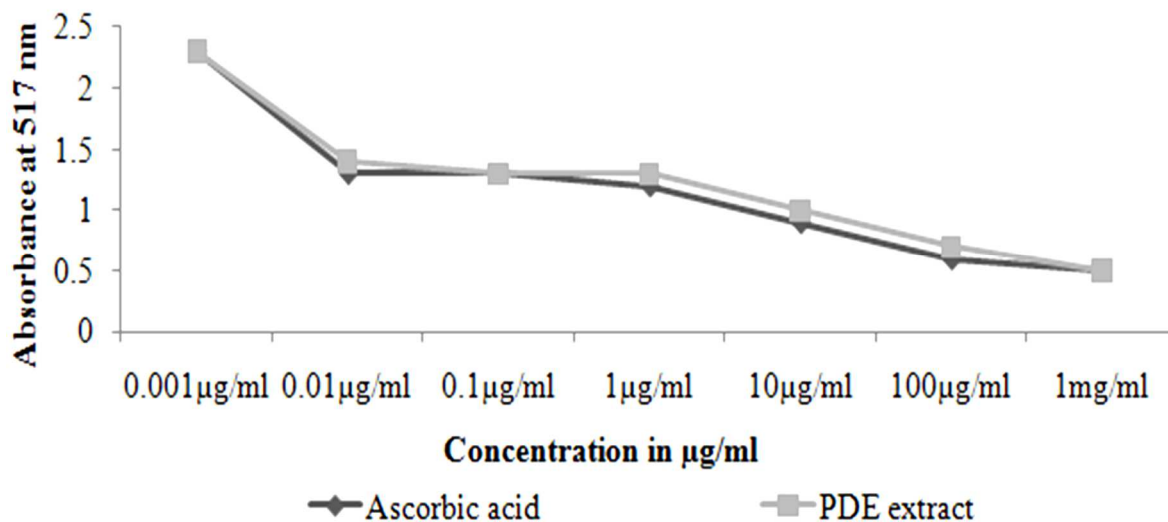


Figure1. Antioxidant potentials of *Prunus domestica*.

and PDE alone treated animals throughout the experiment. However, in irradiated animals (Group III) a statistically significant decrease in GSH level was evident up to day 7 as compared to normal, but afterwards a significant ($p < 0.001$) increase in GSH was observed till day 15 post treatment. PDE pre irradiated (Group IV) animals also showed a similar mode of variation in GSH throughout the experiment, but the observed values were significantly higher at all autopsy. PDE post treated (Group V) animals also showed significantly higher at all autopsy interval but more effective than pretreated (figure 3).

SOD

SOD concentration in irradiated mice (Group III) showed decrease of from the control mice (Group I) respectively ($p < 0.001$). Animals supplemented with PDE after irradiation i.e. experimental group (Group IV) exhibited a higher ($p = 4.445$) SOD concentration than control group (Group III). In irradiated mice (Group III) with a maximum decline at day 3th (0.558 ± 0.133). The values of SOD content in the PDE pretreated (Group IV) were significantly higher ($p < 0.01$) than corresponding control mice (figure 4).

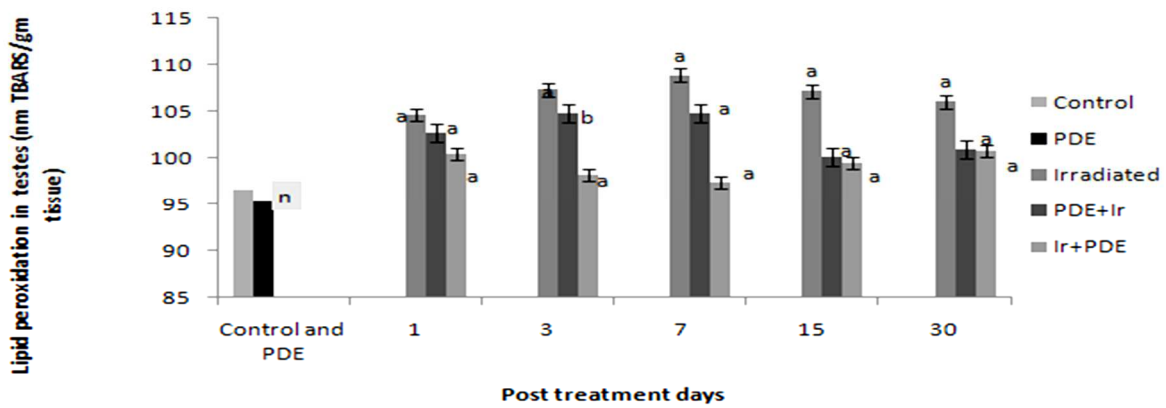


Figure 2. Protection against lipid peroxidation in mice testis after 5 Gy gamma irradiation by pre- and post-administration of PDE. Data have been expressed as mean \pm SEM. The following groups were compared by student's *t* test:(a) control versus PDE treated, (b) control versus irradiated, (c) irradiated versus PDE treated + irradiated, (d) irradiated versus irradiated + PDE treated.

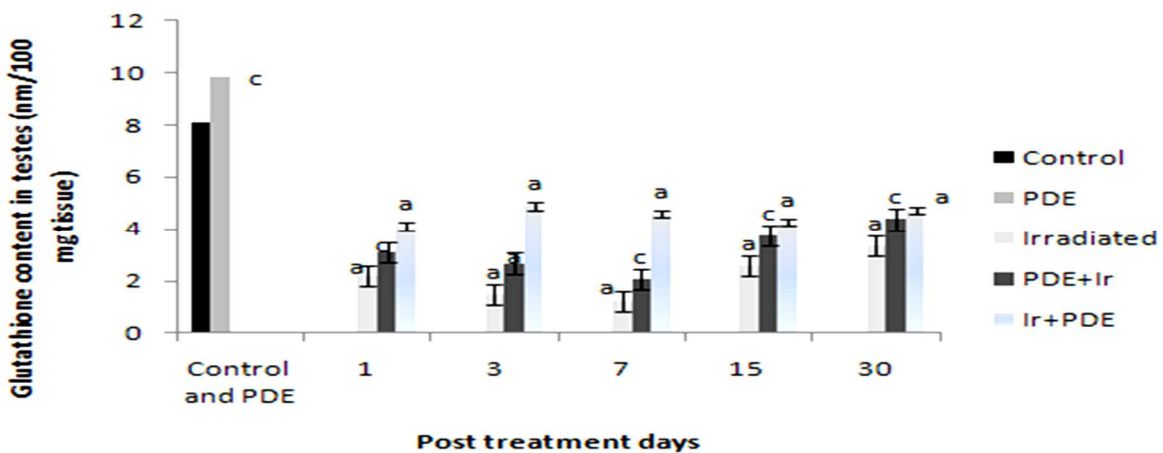


Figure 3. Protection of glutathione (GSH) level of mice testis after 5 Gy gamma irradiation by pre- and post-administrations by PDE. Data have been expressed as mean \pm SEM. The following groups were compared by student's *t* test:(a) control versus PDE treated, (b) control versus irradiated, (c) irradiated versus PDE treated + irradiated, (d) irradiated versus irradiated + PDE treated.

Catalase

Testis tissue showed a gradual and continuous decrease in the level of catalase content till the third post irradiation day in irradiated mice (Group III) thereafter, a gradual increase in catalase content was observed. However, the catalase value was statistically significantly in PDE+IR (Group IV) except day 15. The difference between the control catalase value and that in the group supplemented with PDE only was statistically significant ($p < 0.05$). Post irradiation supplementation of PDE was more effective than pre supplementation and statistically significant ($p < 0.001$) (figure 5).

Testicular histopathology

Histological sections of irradiated mice showed drastic pathological lesions in testes architecture when compared with mice treated with control or PDE alone (group I or group II). Distorted architecture of seminiferous tubules was seen in the form of shrunken tubules, exfoliation, intertubular oedema karyorrhexis, karyolysis, pycnotic nuclei, necrotic cells, and with degenerated cytoplasm in irradiated mice. These radiological symptoms were apparent from the initiation of treatment and the extent of damage intensified gradually up to day 7 post treatment where cellular tires were completely

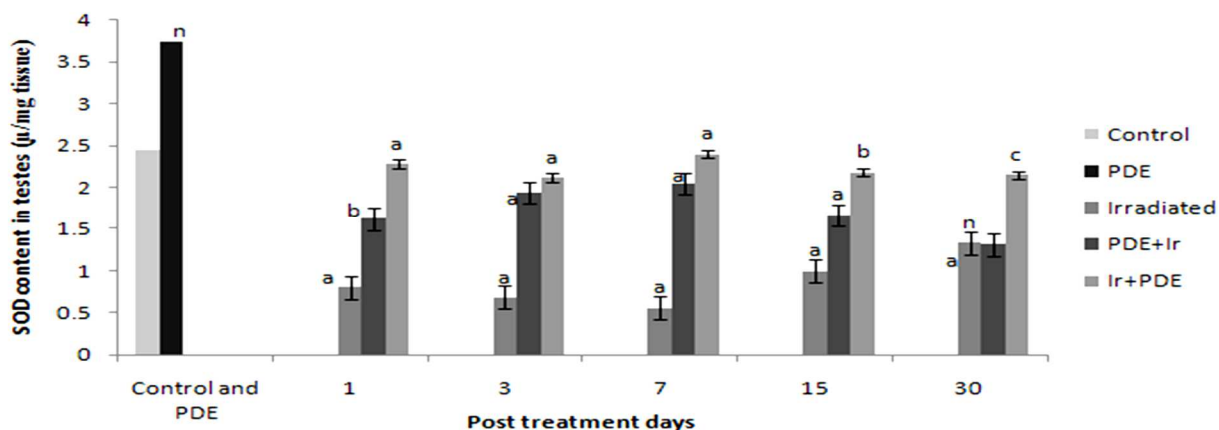


Figure 4. Variation in SOD levels (μ/mg tissue) with and without PDE supplementation in irradiated mice. Data have been expressed as mean \pm SEM. The following groups were compared by student's *t* test:(a) control versus PDE treated, (b) control versus irradiated, (c) irradiated versus PDE treated + irradiated, (d) irradiated versus irradiated + PDE treated.

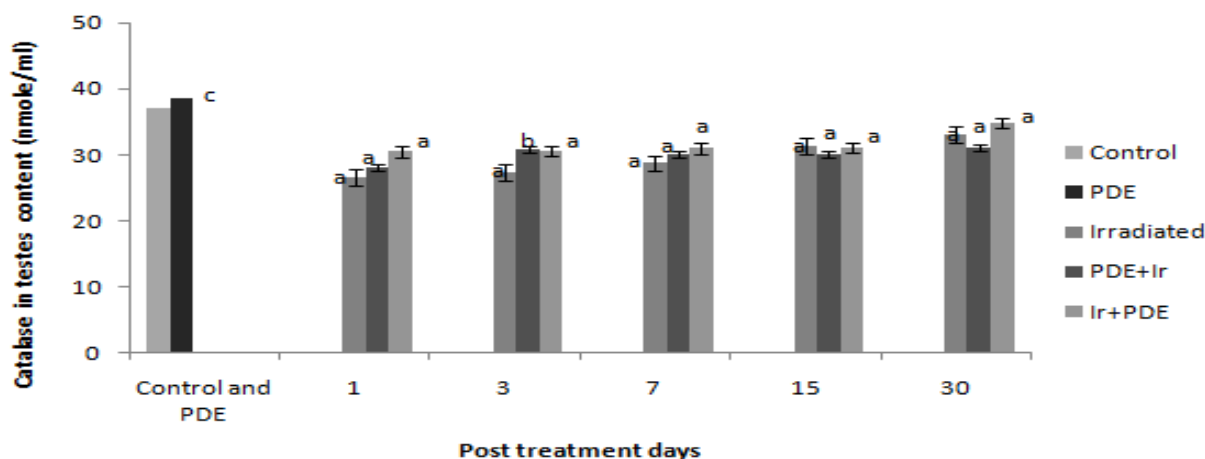


Figure 5. Variations in CAT (nmole/ml) with and without PDE supplementation in irradiated mice. Data have been expressed as mean \pm SEM. The following groups were compared by student's *t* test:(a) control versus PDE treated, (b) control versus irradiated, (c) irradiated versus PDE treated + irradiated, (d) irradiated versus irradiated + PDE treated.

distorted in most of the tubules along with decreased population of germ cells. Notably, PDE pretreatment rendered the quality as evident in the form of intact germinal epithelium, mild cytoplasmic vacuolization with the absence of karyolysis, pyknosis, and necrosis as well as increased germ cells number, and almost a normal testicular architecture was visualized by the end of experiment (figure-6, photomicrograph (A–D) at 40X.

DISCUSSION

Most living species have protective system against oxidative stress and toxic effects of ROS.

Several studies have demonstrated that the antioxidant properties of plant compounds could be correlated with oxidative stress defense. As antioxidant compounds can be used to counteract oxidative damage by reacting with free radicals, chelating free catalytic metals and also by acting as oxygen scavengers. Several studies have demonstrated that the antioxidant properties of plant compounds could be correlated with oxidative stress defense ⁽¹⁸⁾. In present investigation screening attempts have been made to search for anthocyanin and other antioxidants rich fruit extract having potential as antioxidant agents, as now a days due to food habits most of people are suffering from degenerative diseases and to cure such diseases

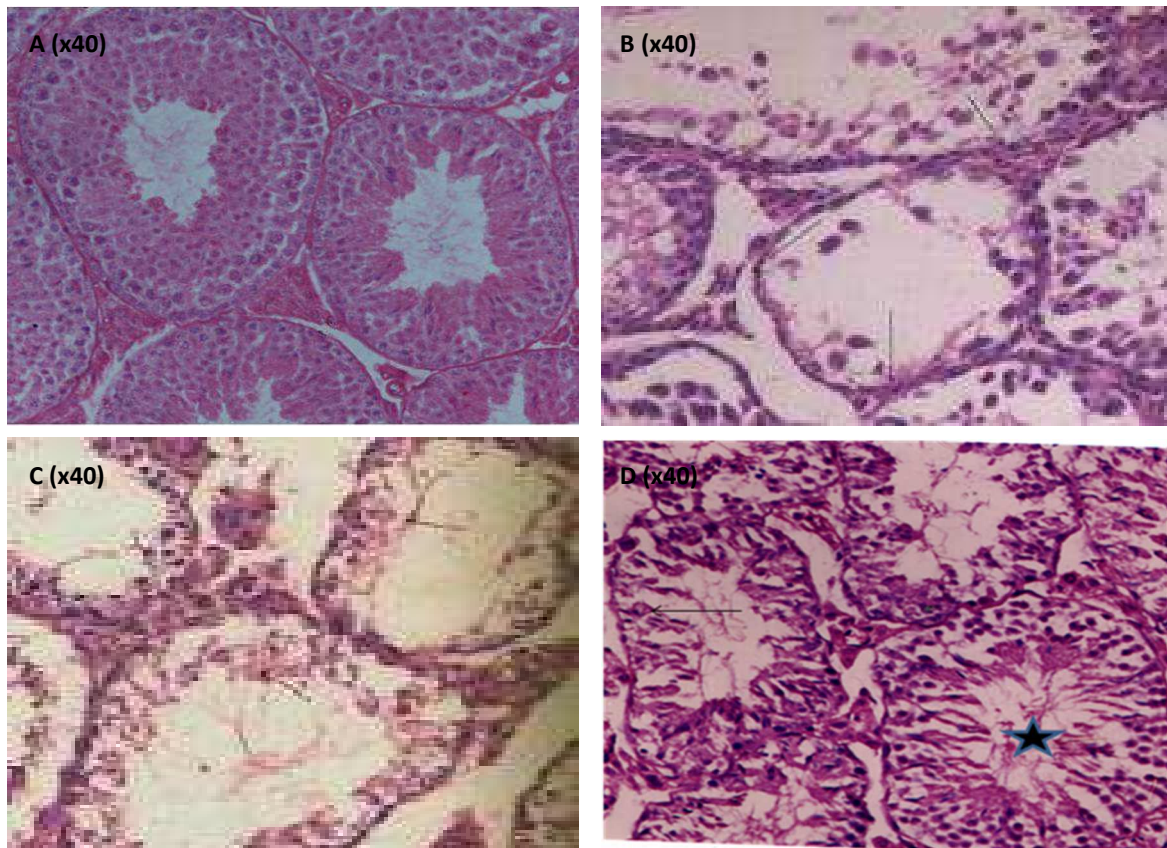


Figure 6: Modulation of radiation-induced histological changes in testes of *Swiss albino* mice by *Prunus domestica* extract. Photomicrograph (A) PDE treated (group II) showing more populated. Photomicrographs (B) of irradiated (group III) T.S. of testes on day 7 are showing disrupted germinal epithelium, lack of mature spermatozoa. Photomicrograph (C) of group IV treated mice on day 7. These are showing intact testicular element and better image then group III. Photomicrograph (D) of group IV treated mice on day 7. Group V images illustrating similar pattern as in group III like cytoplasmic vacuolation necrotic and pyknotic nuclei but the damage is slightly lesser then group III.

there is an urgent need of such extract having potent antioxidant activity. Earlier work in our laboratory with *Grewia asiatica* was also reported to scavenge DPPH, NO (nitric oxide) radicals in vitro in a concentration dependent manner⁽¹⁹⁾. Methanolic extract of *Prunus domestica* showed antioxidant activity comparable to ascorbic acid. Thus, this fruit can be safely used as potent antioxidant agent and can use for various herbal drinks to cure.

Oral administration of a 400 mg/kg bwt dose of PDE for 15 consecutive days, prior to radiation exposure (10 Gy), was found to be effective in terms of survivability compared to other higher and lower doses of PDE. Delayed mortality in group supplemented with PDE prior to irradiation may be due to the effectiveness of PDE in arresting gastrointestinal (GI) death, as indicated by the increased number of survival days in all the treatment groups, compared to the irradiated mice. This reduction in GI death may also be due to the protection of intestinal epithelium, which would have allowed proper absorption of the nutrition. Anthocyanin pigments and associated flavonoids have demonstrated the ability to protect against free radicals.

Infertility has been a major medical and social preoccupation. The protective ability of the phytochemicals against radiation-induced male reproductive abnormalities may offer a new insight into the modification of testicular germcell radiosensitivity which may have implication in amelioration of testicular injuries⁽²⁰⁾. Therefore, the major concern of the present investigation is to assess the possible radioprotective capability of *Prunus domestica* extract in clinical field against radiation-induced male reproductive dysfunctions.

General observations in the present study showed that pre irradiated treatment with PDE appreciably increased survival time of mice by 30 days without any symptoms of radiation-induced sickness. The Present study we selected optimum dose of PDE (400mg/Kg b.wt.) selected after survival studies in our laboratory. Previous findings from our laboratory⁽¹⁸⁾ strongly suggest that radiation-induced depletion of glutathione resulted in an enhanced

LPO as also observed in testicular tissue by Fidan *et al.*⁽²¹⁾. LPO produces a progressive loss of cellular integrity, fluidity of sperm membrane, and its motility, impairment in membrane transport function and disruption of cellular ion homeostasis in testes⁽²²⁾. In the present study, both the irradiated control and experimental groups showed a gradual and continuous augmentation in the level of TBARS contents till day 15 post irradiation, which may be due to increased oxidative stress and decrease in body weight, organ weight, and protein value after radiation exposure as also suggested by Yadav *et al.*⁽²³⁾. Radiation exposure induced a significant depletion in GSH levels at early intervals, which may be due to its enhanced utilization as an attempt to detoxify the acute radiation-induced free radical damage as glutathione is a major endocellular nonenzymatic antioxidant and executes its radioprotective function through free radical scavenging mechanism⁽²⁴⁾. Intracellular GSH status appears to be a sensitive indicator of cell's overall health and its ability to toxic challenges. Being tripeptide in nature, a decrease in GSH content probably is the result of continuous attack of free radicals on it⁽²⁵⁾. Oral administration of *Prunus domestica* to irradiated mice caused significant increase in testes antioxidant mainly GSH in present study. Superoxide radicals (O₂⁻) have been reported in several pathological disorders and susceptible for elevated oxidative stress. A decrease in SOD activity will increase the level of superoxide radicals, leading to an increase in oxidative stress enhancing early cell death, probably by apoptotic mechanisms⁽²⁶⁾. In the present study enhance activity of SOD after PDE msupplementation possibly eliminated the radicals. A decrease in CAT activity increases the concentration of H₂O₂ in the cell leading to an increase in LPO and oxidative stress. Although there is not a single report examining the effects of H₂O₂ on sertoli cell tight junctions in vitro, it is likely that this model of junction disruption, if examined in detail, provides some valuable clues as to the causes of infertility. Testicular CAT is an important and useful sertoli cell marker, because there is a good correlation between testicular CAT activity and relative numbers of sertoli cells.

A decrease in CAT activity will decrease the numbers of sertoli cells affecting spermatogenesis directly or indirectly (27). So decline in CAT activity in the testis may leads to infertility in irradiated mice. Our results suggest that PDE contains a very effective and natural antioxidant system (NAO) that is capable of preventing oxidative damage which is mediated principally through the generation of reactive oxygen species. The exact mechanism of action of PDE is not known. However, scavenging of free radicals and increased concentration of endogenous antioxidant system may be considered as important mechanisms of protection provided by PDE against radiation-induced damage to the testicular tissue. Mechanisms of antioxidative action of vitamin C are direct scavenging and blocking of reactive oxygen species (ROS), as well as regeneration of other antioxidative systems (28). The anthocyanin and other antioxidants may up regulate mRNAs of antioxidants enzymes as well as up regulation of DNA repair genes may also protect against radiation induced oxidative stress by bringing error free repair of DNA damage and thus may counteract the oxidative stress induced by irradiation. Many studies around the world proved that the selection of a particular food plant, plant tissue, or herb for its potential health benefits appears to mirror its polyphenol and flavonoid composition. Polyphenols act as chain breakers or radical scavengers, which attribute to their antioxidant properties possibly through their O₂- and singlet oxygen quenching ability as also noticed by Weiss and Landauer and Hou *et al.* (29,30).

Present study showed that post treatment is more effective then pre treatment especially at later interval. A possible explanation for the post-irradiation protective effects of antioxidants is a model based on electron spin resonance studies suggesting that radiation exposure results in short-lived radicals, such as OH, responsible for cell death, and long lived radicals, which can cause mutations and transformations (31). This concept is also supported by experiments using cells irradiated with a microbeam (32). Studies are required to unravel the underlying mechanism of such plant against ROS mediated damage for improving its efficacy.

CONCLUSION

Based on the above promising results, it can be concluded that fruit extract of *Prunus domestica* has the potential to mitigate the testicular injuries against lethal dose of gamma radiation, which in turn reflected in the form increased survival, inhibited pathological alterations, significant decline in LPO levels, and an enhancement in GSH, SOD CAT, content in PDE pretreated irradiated group as compared to irradiated control group.

ACKNOWLEDGEMENT

We thankfully acknowledge CAS and Department of Zoology, University of Rajasthan, Jaipur, for the liberal use of facilities. The authors are also thankful to Dr A. Chougale, Radiotherapy Unit, SMS Medical College and Hospital, Jaipur (India) for the irradiation facilities and radiation dosimetry.

Conflict of interest: Declared none

REFERENCES

1. Setchell BP and Waites GMH (1989) The blood-testis barrier. In: Hamilton DW, Greep RO, editors. *Handbook of physiology*, Baltimore, 5:143-72.
2. Kretser DM, Kerr JB (1998) The cytology of the testis. In: Knobil E, Neill J, editors. *The physiology of reproduction*. Raven Press, New York 1: 837-932.
3. Patwardhan B, Vaidya ADB, Chorghade M (2004) Ayurveda and natural products drug discovery. *Cur Sci*, 86(6): 789-799.
4. Mahdavi M and Mozdarani H (2011) Protective effects of famotidine and vitamin C against radiation induced cellular damage in mouse spermatogenesis process. *Iran J Radiat Res*, 8 (4): 223-230.
5. Sisodia R, Singh S, Mundotiya C, Meghnani E, Srivastava P (2011) Radioprotection of *Swiss albino* mice by *Prunus avium* with special reference to the hematopoietic system. *JEPTO*, 30(1): 55-70.
6. Sisodia R, Sharma KV, Singh S (2009) Acute toxicity effects of *Prunus avium* fruit extract and selection of optimum dose against radiation exposure. *JEPTO*, 28(4): 305-311.
7. Kayano S, Kikuzaki H, Fukutsaka N, Mitani T, Nakatani N (2002) Antioxidant activity of prune (*Prunus domestica* L.)

- constituents and a new synergist. *Agric Food Chem*, **50**: 3708-3712.
8. Leong LP, Shui G (2002) An investigation of antioxidant capacity of fruits in Singapore markets. *Food Chem*, **76**: 69-75.
 9. Los J, Wilska-Jeszka J, Pawlak M (2000) Polyphenolic compounds of plums (*Prunus domestica*). *Pol J Food Nutr Sci*, **9/50(1)**: 35-38.
 10. Gopalan C, Sastri BVR, Balasubramanyam SC (2002) Food composition table nutritive value of Indian foods. 2nd ed. National Institute of Nutrition, Hyderabad, India **2**: 156.
 11. Mahmood A, Ahmed R, Kosar S (2009) Phytochemical screening and biological activities of the oil components of *Prunus domestica* Linn. *JSCS*, **13**: 273-277.
 12. Sisodia and Sharma (2011) Radio protective potential of *Prunus domestica* against radiation induced oxidative stress in *Swiss albino* mice with special reference to spatial learning. *Pharmacologyonline*, **3**: 1159-1174.
 13. Takao T, Kitatani F, Wanatabe N, Yogi A, Sakata K (1994) A simple screening method for antioxidant and isolation of several antioxidant produced by marine bacteria from fish and shell fish. *Biosci Biotech Biochem*, **58**: 1780-1783.
 14. Buege JA, Aust SD (1978) In *Methods in Enzymology*, Academic Press, New York, **52**: 302-314.
 15. Moron MS, Depierre JW, Mannervik B (1979) Levels of GSH, GR and GST activities in rat lung and liver. *BBA*, **582**: 67-78.
 16. Marklund S, Marklund G (1974) Involvement of superoxide anion radical in auto oxidation of pyrogallol and a convenient assay for superoxide dismutase. *FEBS*, **47**: 469-474.
 17. Aebi H Catalase: (1984) In vitro. Eds. Colowick SP, Kaplan NO. In: *Method of Enzymology*, Academic press, New York. **105**: 121-126.
 18. Amarowicz R, Pegg RB, Rahimi MAP, Barl B, Weil JA (2004) Free radicals scavenging capacity and antioxidant activity of selected plant species from the Canadian prairies. *Food Chem*, **84 (55)**: 1-62.
 19. Sharma KV, Sisodia R (2009) Evaluation of the free radical scavenging activity and radioprotective efficacy of *Grewia asiatica* fruit. *J Radiol Prot*, **29**: 429-443.
 20. Sharma P, Parmar J, Sharma P, Verma P, Goyal PK (2011) Radiation-Induced Testicular Injury and Its Amelioration by *Tinospora cordifolia* (An Indian Medicinal Plant) Extract. *Ecam*, 1155/2011/643847
 21. Fidan AF, Engina H, Cigerci H, Korcan E, Ozdemir A (2008) The radioprotective potential of *Spinacia oleraceae* and *Aesculuc hippocastanum* against ionizing radiation with their antioxidative and antioxidative properties. *J Am Vet Med*, **7(12)**: 1528-1536.
 22. Aitken RJ, Baker MA (2004) Oxidative stress and male reproductive biology. *Reprod Fert Develop*, **16(5)**: 581-588.
 23. Yadav RK, Bhatia AL, Sisodia R (2004) Modulation of radiation induced biochemical changes in testis of *Swiss albino* mice by *Amaranthus paniculatus* Linn. *AJES*, **18**: 63-74.
 24. Bump EA, Brown JM (1990) Role of glutathione in the radiation response of mammalian cells in vitro and in vivo. *Pharmacol Therapeut*, **47(1)**: 117-136.
 25. Duke RC, Ocius DM, Young JDE (1996) Cell suicide in health and disease. *Sci, Am*. 12-79.
 26. Verme R, Chakraborty D (2008) Emblica officinalis aqueous extract ameliorates ochratoxin- induced lipid peroxidation in the testis of mice. *Acta Pol Pharm*, **65 (2)**: 187-194.
 27. Ihrig TJ, Renston RH, Renston JP, Gondos B (1974) Catalase activity in the developing rabbit testis. *J Reprod Fer*, **39**: 105-108.
 28. Griffiths HR, Lunec J (2001) Ascorbic acid in the 21st century more than a simple antioxidant. *Environ Toxicol Phar*, **10**: 173-182.
 29. Weiss JF, Landauer MR (2003) Protection against ionizing radiation by antioxidant nutrients and phytochemicals. *Toxicol*, **189(1-2)**: 1-20.
 30. Hou Z, Lambert JD, Chin KV, Yang CS (2004) Effects of tea polyphenols on signal transduction pathways related to cancer chemoprevention. *Mut Res*, **555(1-2)**: 3-19.
 31. Koyama S, Kodama S, Suzuki K, Matsumoto T, Miyazaki T, Watanabe M (1998) Radiation-induced long-lived radicals which cause mutation and transformation. *Mut Res*, **421**: 45-54.
 32. Wu LJ, Randers GP, Xu A, Waldren CA, Geard CR, Yu Z, Hei TK (1999) Targeted cytoplasmic irradiation with alpha particles induces mutations in mammalian cells. The Proceedings of the National Academy of Sciences Online USA, **96**: 4959-4964.