

• **Case report****Leiomyosarcoma of the tongue; Report of a case****A. Kazemian¹, Sh. Kamian^{2*}, M. S. Hoseini², M.R. Azizi³**¹Department of Radiation Oncology, Cancer Institute, Tehran University of Medical Sciences, Tehran, Iran² Imam Khomeini Hospital, Dr. Gharib Street, Tehran, Iran³ Shariar General Hospital, Tehran, Iran

Soft tissue sarcomas of the oral cavity are uncommon malignancies; those of smooth-muscle origin are extremely rare. Leiomyosarcomas of the tongue are very rare. Either surgery or radiation therapy with or without chemotherapy are the treatment modalities which improve prognosis. We are presenting a 32-year-old man with leiomyosarcoma of the lateral aspect of the oral tongue with neck metastasis, who was referred to our radio therapeutic oncology department after glossectomy and radical modified neck dissection. The clinical and pathologic features together with his clinical course will be discussed. Six months after chemoradiotherapy, he developed a single metastasis in his right femur, and then by features of lung metastasis he died in a few weeks, unfortunately. Iran. J. Radiat. Res., 2005; 3 (3): 143-147

Keywords: Tongue, leiomyosarcoma.**INTRODUCTION**

Soft tissue sarcomas arising in the head and neck are rare among adults. They account for approximately 10% of all soft tissue sarcomas and approximately 1% of head and neck tumors. Leiomyosarcomas are among the unusual soft tissue sarcomas in the head and neck which account about 0.2% of the cases in the reported series⁽¹⁾. Leiomyosarcoma of the tongue is a very rare tumor. Reviewing of literature by Aydin *et al.* revealed that there were 80 cases of oral cavity leiomyomas and 26 cases of leiomyosarcoma⁽²⁾, but only 5 cases originated from the tongue⁽²⁾.

The optimal treatment is complete resection. Although radical resection alone results in a high rate of local control, achieving a complete compartmental resection in the head and neck especially oral cavity is usually not feasible. Local recurrence rate for high grade soft tissue sarcoma after a wide local excision may be as high as 50%⁽¹⁾. Thus, most

patients with soft tissue sarcomas of head and neck receive post operative adjuvant radiotherapy (RT), including those with low grade lesions⁽¹⁾. The 5-year local control rates of combination of surgery and RT in soft tissue sarcomas arising in the head and neck range 60-70%, which are similar to the 5-year cause-specific and overall survival rates⁽¹⁾. The value of adjuvant chemotherapy is unclear. Few data directly pertain to the efficacy of chemotherapy for these tumors, so it is necessary to extrapolate data from soft tissue sarcomas arising in the other site such as doxorubicin-based regimens⁽¹⁾. As leiomyosarcomas of the oral cavity are among the rare soft tissue sarcomas in the head and neck, the best treatment options seems to be surgery combined with radiotherapy to improve local control. It may be possible to know the best approaches by practicing more cases.

CASE REPORT

A 32-year-old man was admitted with an ulcerative mass in the lateral aspect of his tongue from 12 months before biopsy. There was not history of using tobacco or alcohol. Excisional biopsy was carried out. The lesion was characterized by pleomorphic spindle-cells proliferation with whorled pattern (figure 1). In some areas, the tumor cells showed perinuclear halo. Mitotic figures were frequent, and the tumor was partly covered by necrotic debris. Immunostains revealed negative reaction with epithelial

***Corresponding author:**

Dr. Shaghayegh Kamian, Dr. Gharib Street, Imam Khomeini Hospital, Tehran, Iran.

Fax: +98 21 66933005

E-mail: shk_191@yahoo.com

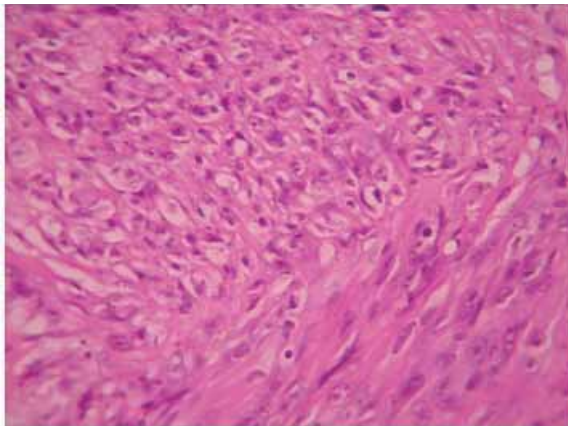


Figure 1. Photo micrograph of the tongue lesion (H & E; × 40).

membrane antigen (EMA), cytokeratin and smooth muscle actin (SMA) and patchy reactions for muscle specific actin (MSA) and Desmin. The histomorphologic features in conjunction with immunohistochemical stains (IHC) pattern were consistent with leiomyosarcoma. Then he was undergone a partial glossectomy. On the gross examination of the specimen the ulcerative region overlaid a tumor measuring up to 1.5 cm. This was composed of pleomorphic spindle cells with atypical and typical mitosis more than 5 per each microscopic field of view, which presented a high grade tumor (figure 1). Safe surgical margins were about 1.5-2.5 cm, and depth of specimen were free from tumor. He did not receive further treatment. Seven months later, multiple lymphadenopathies in the left superior jugular chain appeared, so modified radical neck dissection was done. The pathologic report indicated highly malignant pleomorphic spindle cells compatible with metastatic leiomyosarcoma in one out of 29 dissected lymph nodes. He was then referred to the radiotherapeutic oncology department for post operative radiotherapy. The patient had no complaint, and there was neither cervical lymphadenopathy nor palpable mass in the tongue except the scar in the physical examination. Other examinations were normal. Imaging studies (CT scan) of thorax was normal at that time. Radiation therapy with Co 60 with two lateral portals for upper neck and tongue for total dose of 60 Gy (FD=200cGy) five days a week (30 fractions) in 40 days, and a single supraclavicular field

for total dose of 50Gy in 25 fraction in 30 days was delivered. During the treatment, complications were mucositis grade 2 and some degree of sore throat was observed. The signs and symptoms at the end of radiotherapy were mucositis grade 2 moist desquamation on his neck, and grade 1 dysphagia. On his follow up, one month after the end of radiotherapy, he had only a complaint of hoarseness, which was relieved by corticosteroid.

Then, he received chemotherapy with the regimen of MAID (Mesna, Adriamycin, Ifosfamide, and Dacarbazine), which is a suitable regimen for sarcomas, through six cycles. He had no symptom or sign of the disease in this time. One month after the end of the last chemotherapy course, his complaint from pain of the proximal of his right femur. Increased uptake in the neck of the right femur seen in the whole body bone scan was compatible with metastasis (figure 2). In plain X-ray, there was a round cyst-like mass with internal dense component measuring 25×23 mm in the right femoral neck with normal cortex around it suggestive of a solitary metastasis (Figure 3). In the MRI imaging, some excess little fluid was seen in the right hip joint (figure 4). In the metastatic work up, brain and thorax CT scans were normal. Core needle biopsy was done, and pathologic report revealed a pleomorphic spindle cell tumor with areas of necrosis (figure 5). He was undergone hip arthroplasty and another biopsy 25 days later. The gross specimen was a tumoral mass measuring 60×50×10 mm, and there

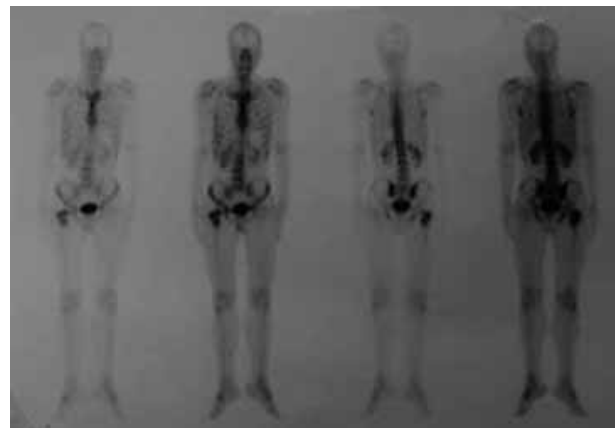


Figure 2. Single metastasis in right femur in bone scan.

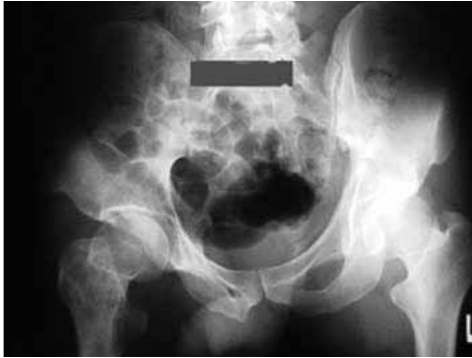

Figure 3. Plain X-Ray, single bone metastasis in right femur.

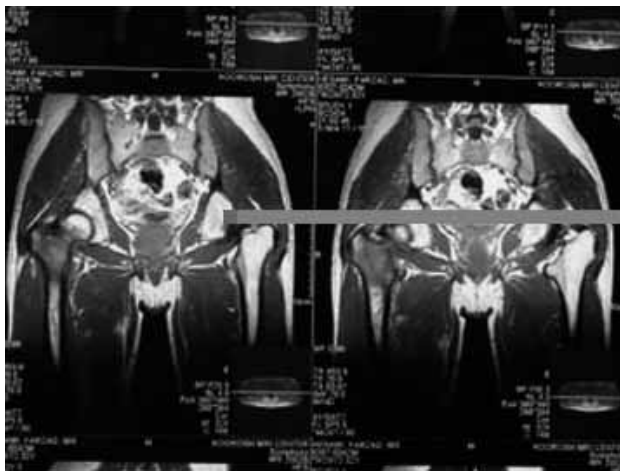


Figure 4. Metastasis in right femur in MRI.

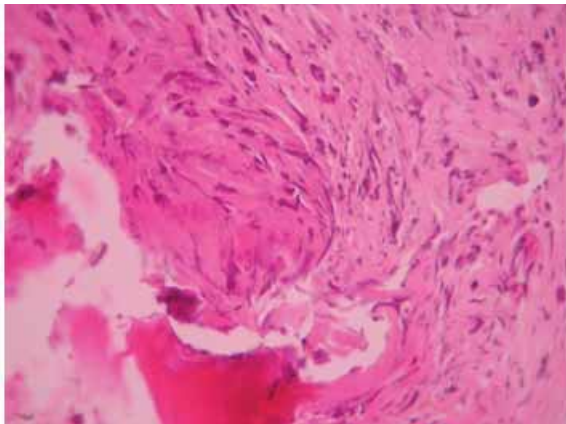


Figure 5. Photo micrograph of the femur metastatic lesion (H & E; × 40).

were atypical spindle cells having prominent mitotic figures and extensive necrosis with marked pleomorphism that destructed cortical bone and extended into surrounding soft tissue.

Radiotherapy was done for right femur with two AP/PA fields with Co-60 for tumor dose of 30 Gy in 10 fractions post operatively,

as a palliative therapy for decreasing the sustained pain. Pain was then decreased. Unfortunately 5 months later lung metastasis appeared. Before initiating any treatment, he developed progressive respiratory distress and died.

DISCUSSION

More than 95% of the oral tongue cancers are squamous cell carcinoma⁽³⁾. Soft tissue sarcomas of the head and neck in adults are rare, and they represent approximately 1% of all head and neck malignancies and 10% of all soft tissue sarcomas. There is a variable male preponderance; the median age is approximately 50 to 55 years with a wide range. Most patients are initially seen with a painless mass. The median interval between onset and diagnosis is 5.5 months. Most head and neck soft tissue sarcomas are high grade. A wide spectrum of histologic subtypes is observed, but there is preponderance of angiosarcoma in this site. The prognosis may vary depending on the histologic findings, and angiosarcoma is the worst one⁽¹⁾. In a study, 103 known cases of soft tissue sarcoma of head and neck were reviewed, and was discovered that survival was dependent to recurrence, grade, extension of primary tumor. The only independent prognostic factor in local control was T stage⁽³⁾.

Soft tissue sarcoma of the oral cavity is very uncommon malignancies; those of smooth-muscle origin are extremely rare. Leiomyosarcoma may arise in any location, but more than half are located in retroperitoneal or intraabdominal sites, and in the head and neck account for about 0.2% of the cases in the reported series⁽¹⁾. Leiomyosarcoma of the oral cavity is a very rare tumor that is associated with aggressive clinical behavior and low survival. The behavior of this disease is site-related. Leiomyosarcoma of the tongue is a very rare tumor. The literature reveals about 80 leiomyomas and 26 cases of leiomyosarcoma, and only 5 of the them with leiomyosarcoma occurred in the tongue⁽²⁾. Most of these tumors present as a painless subcutaneous or submucosal mass.

CT and/or MRI are used to evaluate the extent of the primary lesion and to assess the regional lymph nodes. The likelihood of regional lymph node metastases is low. In the reports, the incidence of positive regional nodes was about 2-5%⁽¹⁾.

Fine-needle aspiration (FNA) is the first step to obtain a histologic diagnosis of a neck mass. However, the sample is limited and may not be diagnostic, so a core needle biopsy or limited incisional biopsy may be necessary. Soft tissue sarcomas are prone to seeding, and care should be taken not to contaminate a potential future operative site⁽¹⁾.

The likelihood of distant metastases is related to histologic grade and tumor size; the risk is highest for large, high-grade lesions. The most common site for distant metastases is the lung. Thus, patients should undergo a chest CT before treatment. Metastases to other sites are unlikely, particularly in the absence of pulmonary metastases, so that additional diagnostic studies, such as a brain MRI or a bone scan, are not necessary in the absence of symptoms⁽¹⁾.

The optimal treatment is complete resection and every attempt should be made to obtain a gross total resection with at least 1 cm margin. However, unlike extremity sarcomas, head and neck sarcomas are not amenable to wide local excision with generous margin of normal tissue due to anatomic constraints. Therefore, the use of adjuvant therapy is more liberal in this site, because local recurrences could be the cause of death in a substantial proportion of the patients⁽⁵⁾. Postoperative adjuvant RT is indicated for patients with low-grade tumors who have close (<1 cm) or positive margins, as well as those with high-grade tumors⁽¹⁾.

If surgery is not feasible, the tumor is treated with definitive RT to a high dose (74.4-81.6 Gy at 1.2 Gy per fraction twice daily in a continuous course). It is difficult to assess the efficacy of RT alone, because it is usually used for large unresectable tumors that have a low chance of cure after any treatment modality. However, it is likely that surgery and RT are more efficacious than RT alone for resectable tumors⁽¹⁾.

The value of adjuvant chemotherapy is

unclear. Few data directly pertain to the efficacy of adjuvant chemotherapy for head and neck soft tissue sarcomas, therefore, it is necessary to extrapolate data from soft tissue sarcomas arising in more common locations. However, subset analysis of patients with extremity soft tissue sarcomas revealed a significant improvement in overall survival for patients who received adjuvant chemotherapy⁽¹⁾.

Due to the rarity of this tumor, there is a limited number of leiomyosarcoma of the tongue reported in the literature. A 48-year-old woman with leiomyosarcoma of the tongue was reported by Wollenberg *et al.*⁽⁶⁾. The tumor was surgically removed. The prognosis was not mentioned in the report. A case report of this disease was published by Mayall *et al.* in a 60-year-old man⁽⁴⁾. Partial glossectomy was done without further treatment, and in one year of follow up, there was no evidence of recurrence. Another report by Aydin *et al.* was a patient, a known case of the leiomyosarcoma of the base of the tongue, who was treated with radiation therapy, and at follow up of about 1.5 year he had no sign or symptom of local recurrences or distant metastasis⁽²⁾. Muzio *et al.* reported a case of leiomyosarcoma of the oral tongue in a 67-year-old man who had a wide local excision and after five years of follow up, he had no symptom of recurrence⁽⁷⁾.

There are some difficulties in the histopathologic discrimination between benign and malignant smooth muscle tumors due to the absence of reliable histologic parameters for prognostication of leiomyosarcomas. So evaluation of the diagnostic and prognostic value of various immunohistochemical and molecular markers have been done by some investigators. By means of immunohistochemistry and quantitative real-time PCR analysis, Nikitakis *et al.* detected protein expression of PCNA, bcl-2, CDK4, p53 and MDM2 in both of their two cases of oral leiomyosarcomas, and MDM2 amplification in one of the cases⁽⁸⁾. Another review of literature was done by Montgomery *et al.* Cases diagnosed as leiomyosarcoma of the head and neck was retrieved from the archives of three institutions. Immunohistochemical stains were performed

and follow-up information was obtained. They studied 13 cases aged 21-73 years with lesions of different sites in the head and neck. Three of the cases were leiomyosarcomas of the buccal area. All tumors showed at least focally typical histological features of leiomyosarcoma with perpendicularly arranged fascicles of smooth muscle cells with blunt-ended nuclei, eosinophilic cytoplasm and paranuclear vacuoles. They expressed muscle-specific actin, smooth muscle actin, and desmin. All 13 patients had surgery, with radiation and/or chemotherapy in seven. Three (27%) recurred at 6-24 months; in one case two recurrences at different times were detected. Five (56%) had metastases, including the three with prior recurrences at 1-128 months. Five (including two who received adjuvant therapy) were disease-free at a median of 47 months, one was alive with metastatic disease at 24 months), and three were dead of disease (median 13 months). They concluded that head and neck leiomyosarcomas are rare and aggressive neoplasms with a high propensity for metastasis, and adjuvant therapy has limited effect⁽⁹⁾.

According to the literatures, there are few cases of leiomyosarcomas of head and neck, and more uncommon in the oral cavity. So, there is not a standard treatment for this rare disease. Surgery, radiation therapy, and chemotherapy were the options that have been used for the reported cases. It is logical that surgery is the primary treatment of this lesion like soft tissue sarcoma of other sites, and in some of the reports satisfactory results has been seen with this approach. But unfortunately there were fewer experiences with adjuvant therapy. Adjuvant RT likely improves the probability of cure in patients with high-grade tumors and those with close or positive margins. RT alone may cure a small subset of patients with advanced unresectable lesions. Although the efficacy of adjuvant chemotherapy is ill defined, it should be considered for patients with high-grade lesions⁽¹⁾.

In our case, both radiotherapy and

chemotherapy were done after resection of the recurrent tumor. But unfortunately he developed a single metastasis to the proximal of his right femur that is not a common site of metastasis of soft tissue sarcoma. As discussed earlier, metastasis work up was done for him and all of them were negative except the involvement of the femur. This presentation was not seen in the previous reported cases. Despite radiotherapy for femoral metastasis, he died five months later.

Appropriate treatment options, and accurate estimation of survival outcome, however, will not be conclusive until sufficient cases have been reported. With the rarity of this tumor, such knowledge may require more practices.

REFERENCES

1. Mendenhall WM, Mendenhall CM, Werning JW, Riggs CE, Mendenhall NP (2005) Adult head and neck soft tissue sarcomas. *Wiley Inter Science*, DOI: 10.1002/hed.20249.
2. Aydin H and Dreyer T (1994) Leiomyosarcoma of base of the tongue treated with radiotherapy: a case report. *Eur J Cancer B Oral Oncol*, **30B**: 351-5.
3. Devita Jr, Hellman S, Rosenberg SA (2005) Cancer principle and practice of oncology. 7th ed. Lippincott Williams &Wilkins; Philadelphia, USA
4. Mayall F, Hickman J, Bulman C, Blewitt R (1994) Leiomyosarcoma of the tongue: a very rare tumor. *J Laryngol Otol*, **108**: 617-8.
5. Devita Jr, Hellman S, Rosenberg SA (2001) Cancer principle and practice of oncology. 6th ed. Philadelphia, USA: Lippincott Williams &Wilkins.
6. Wollenberg B, Muller-Hocker J, Wustrow TP (1993) Leiomyosarcoma of the tongue. *Laryngorhinootologie*, **72**: 342-5.
7. Lo Muzio L, Favia G, Mignogna MD, Piattelli A, Maiorano E., (2000). Primary intraoral leiomyosarcoma of the tongue: an immunohistochemical study and review of the literature. *Oral Oncol*, **36**: 519-24.
8. Nikitakis NG, Lopes MA, Bailey JS, Blanchaert RH Jr, Ord RA, Sauk JJ (2002) Oral leiomyosarcoma: review of the literature and report of two cases with assessment of the prognostic and diagnostic significance of immunohistochemical and molecular markers. *Oral Oncol*, **38**: 201-8.
9. Montgomery E, Goldblum JR, Fisher C (2002) Leiomyosarcoma of the head and neck: a clinicopathological study. *Histopathology*, **40**: 518-25.