

Influence of simultaneous-integrated boost, intensity-modulated radiation therapy on electroencephalogram records: Case report-

K. Jezierska^{1*}, M. Łukowiak², H. Podraza¹, W. Podraza¹, M. Falco³,
M. Lewocki², H. Domek¹

¹Department of Medical Physics, Pomeranian Medical University, ul. Ku Słońcu 12, 71-073 Szczecin, Poland

²Medical Physics Department, West-Pomeranian Oncology Center, ul. Strzałowska 22, 71-730 Szczecin, Poland

³Radiotherapy Department, West-Pomeranian Oncology Center, ul. Strzałowska 22, 71-730 Szczecin, Poland

► Case report

ABSTRACT

60-year-old woman was treated for a brain metastasis. The patient received *intensity-modulated radiation therapy* (SIB-IMRT) dose of 30 Gy for the whole brain and 40 Gy delivered simultaneously to individual brain metastases in 10 fractions. The present report investigated the influence of applied novel prepared treatment plan, among others the fractionation protocol on the electroencephalogram (EEG) record.

Keywords: Head and neck, neuroradiology, radiation oncology, physics.

*Corresponding author:

Dr. Karolina Jezierska

Fax: + 48 91 4414521

E-mail: karo@pum.edu.pl

Revised: March 2016

Accepted: April 2016

Int. J. Radiat. Res., January 2016;
15(1): 113-116

DOI: 10.18869/acadpub.ijrr.15.1.113

CASE PRESENTATION

60-year-old woman, was treated for a brain metastasis (figure 1). Neurological examination showed no knee and ankle jerk reflexes. Polyneuropathy after chemotherapy was diagnosed. The patient received SIB-IMRT therapeutic dose of 30 Gy for the whole brain and 40 Gy delivered simultaneously to individual brain metastases in 10 fractions, combined with the next session of chemotherapy and medication (anticonvulsants and steroids). Patient was discharged from the hospital in good general condition.

The dose volume histogram is presented in figure 2. On the first and last day of radiotherapy, the waking EEG examinations

were performed. The EEG records were analyzed by the neurologist. Additionally, we applied the fast Fourier transform (FFT) to the statistical analysis of the EEG data.

For both records the alpha rhythm shows typical responses to eye-opening. The dominant EEG pattern in the parieto-occipital areas, in both records, was an alpha rhythm with a frequency 8 Hz and an amplitude up to 60 μ V, mixed with low amplitude theta waves (5-7 Hz).

Analysis of the first EEG record showed that, on a background of low voltage beta activity in the frontal areas, a repeated, synchronized group of waves with a frequency of 2-5 Hz and a maximum amplitude of 80 μ V occurred in the fronto-temporal-parietal areas, particularly on the left side of the brain. After therapy, the

spatial analysis showed that, on a background of low voltage beta activity in the frontal areas, low voltage theta waves appeared with a frequency of 4-5 Hz in the left fronto-temporal area.

The minimum, maximum and mean doses were comparable among the different brain lobes, as seen in table 1.

Analyses of the spectral contributions to EEG rhythmic activity suggested that the bioelectrical

activity changed after the applied treatment in both sides of the brain (Table 2). The most significant results were observed in the central and temporal areas, particularly in the right hemisphere.

The research was conducted with the approval of the Bioethics Committee of the Pomeranian Medical University in Szczecin and informed consent of patients.

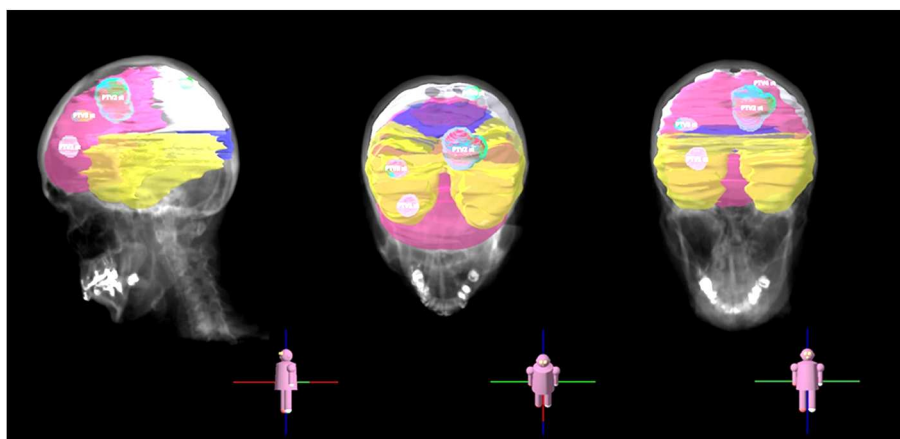
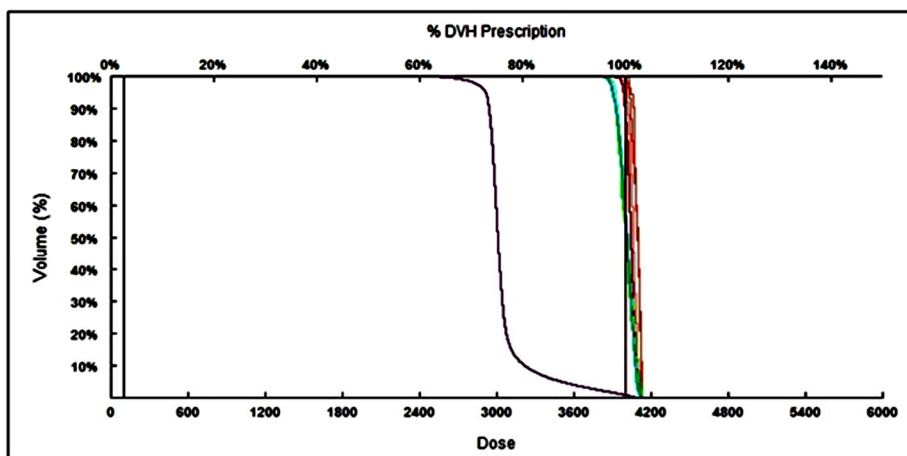


Figure 1. Positions of targets. Brain lobes – frontal (pink), temporal (yellow), parietal (grey), occipital (violet).



Name	Vol (cc)	DLV (%)	D-X (cGy)			V-X (%)		Min (cGy)	Max (cGy)	Mean (cGy)	Median (cGy)	Modal (cGy)	
GTV1	0.8	100.0	4112.0	3992.0	4060.0	0.0	98.0	100.0	3986.5	4111.1	4060.2	4059.5	4056.5
GTV2	9.7	100.0	4112.0	3972.0	4042.0	0.0	88.1	100.0	3916.2	4124.4	4041.4	4041.5	4036.5
GTV3	0.4	100.0	4134.0	4022.0	4092.0	0.0	100.0	100.0	4007.4	4133.3	4091.6	4091.5	4070.5
GTV4	0.1	100.0	4119.0	4026.0	4100.0	0.0	100.0	100.0	4025.5	4118.6	4086.3	4099.5	4118.5
PTV1st	2.5	100.0	4108.0	3910.0	4014.0	0.0	55.5	100.0	3866.9	4111.1	4010.1	4013.5	3936.5
PTV2st	18.2	100.0	4107.0	3879.0	4017.0	0.0	59.5	100.0	3811.7	4124.4	4007.0	4016.5	4036.5
PTV3st	1.9	100.0	4129.0	3874.0	4008.0	0.0	52.5	100.0	3846.8	4133.3	4008.5	4006.5	4081.5
PTV4st	0.9	100.0	4119.0	3887.0	4007.0	0.0	53.2	100.0	3865.8	4118.6	4001.7	4006.5	4025.5
PTV1	1633.7	100.0	3983.0	2820.0	3009.0	0.0	0.9	4.0	2197.6	4133.3	3056.7	3008.5	2993.5

Figure 2. Dose volume histogram. (Top) The dose, volume, and percent of prescription are shown for each brain area. Colors represent the areas shown in the table (color-code is in the left column). (Bottom) Values and statistical parameters are shown for each dose shown on the histogram.

Table 1. The minimum, maximum, and mean doses for the brain lobes.

		D min [Gy]	D mean [Gy]	Dmax [Gy]
Frontal lobe	right	25.28	31.60	41.00
	left	26.06	31.90	40.92
	whole	25.28	31.75	41.00
Parietal lobe	right	28.03	29.87	32.96
	left	27.44	30.17	40.86
	whole	27.44	30.02	40.86
Temporal lobe	right	27.25	29.79	31.35
	left	24.35	29.68	31.55
	whole	24.35	29.74	31.55
Occipital lobe	right	28.85	29.66	30.68
	left	28.94	29.84	30.72
	whole	28.25	29.76	30.72

Table 2. The differences between the spectral contributions of EEG rhythmic activity before and after radiotherapy sessions. Only artifact-free segments that lasted at least 5 s were analyzed. When the data distribution was normal, the Student-t test was used for statistical analysis; otherwise, the Wilcoxon signed-rank test was applied. Values in parentheses are not statistically significant (p -value <0.05).

Electrode locations	Spectral contribution of EEG rhythmic activity [%]			
	DELTA	THETA	ALPHA	BETA
Fp2-F8	8	(1-)	7-	(0)
F8-T4	12	(1)	4-	9-
T4-T6	(3)	9	10-	(2-)
T6-O2	(2-)	(2)	(1)	(2-)
Fp1-F7	8	8-	(1-)	(0)
F7-T3	(0)	2	(1-)	(1-)
T3-T5	8	(1)	7-	3-
T5-O1	5-	(0)	4	(1)
Fp2-F4	(1)	(0)	7-	6
F4-C4	15	3	18-	(0)
C4-P4	(0)	7	(3-)	2-
P4-O2	5	(0)	3-	2-
Fp1-F3	7	2-	5-	(0)
F3-C3	6	4	14-	4
C3-P3	(0)	3	4-	(2)
P3-O1	5-	(2-)	4	3
Fz-Cz	2	3	8-	(1)
Cz-Pz	(1-)	7	5-	(1-)

DISCUSSION

Brain tumors comprise a group of commonly occurring metastatic tumors observed in patients with chronic cancers ⁽¹⁻²⁾. When the tumor exhibits a relatively small volume and has undergone a small number of changes, in-field boost radiotherapy has been increasingly used

to treat the whole brain with a SIB ⁽³⁻⁵⁾.

The data we presented are based on irradiation of the patient with brain metastases. That was one of the first patients irradiated with stereotactic technique. We tried to introduce it with highest possible level of safety and we decided to start with whole brain radiotherapy combined with concomitant boost to

metastases. Results of two trials with such approach were published; both used more aggressive regimens (the first one WBRT 20Gy and 40 delivered in 5 fractions, the other WBRT 30 Gy and 60 Gy delivered in 10 fractions) ^(4,6). We decided to use moderate escalation in 10 fractions with doses 30 Gy WBRT and 40Gy. This regimen appeared to be safe and quite effective. We verified precision of our irradiation and decided to start with more hypofractionated regimen limited to selected groups of our patients.

The effects of radiotherapy on the pathological brain are complex and multifactorial. Nevertheless, our analysis of EEG records showed that the treatment did not cause any alarming changes in bioelectric activity. Both abnormalities, before and after radiotherapy seemed to be the result of the disease and the impact of the treatment on EEG recording is still difficult to estimate. The comparison of two methods for evaluating EEG records indicated that the FFT analysis was more worthwhile than the spatial analysis in this case study (FFT analysis showed significant EEG changes before and after radiation whereas spatial analysis did not). Clearly, we cannot draw any firm conclusions in comparing these methods based on only one case report. However obtained results were valuable, because authors haven't found studies which analyzed these methods in terms of the bioelectric activity of the brain and we described a novel prepared treatment plan.

Conflict of interest: Declared none.

REFERENCES

1. Gupta GP and Massagué J (2006) Cancer Metastasis: Building a Framework. *Cell*, **127**(4): 679–95.
2. Andrews DW, Scott CB, Sperduto PW, Flanders AE, Gaspar LE, Schell MC, Werner-Wasik M, Demas W, Ryu J, Bahary JP, Souhami L, Rotman M, Mehta MP, Curran WJ (2004) Whole brain radiation therapy with or without stereotactic radiosurgery boost for patients with one to three brain metastases: phase III results of the RTOG 9508 randomised trial. *The Lancet*, **363** (9422): 1665–72.
3. Rodrigues G, Eppinga W, Lagerwaard F, de Haan P, Haasbeek C, Perera F, Slotman B, Yaremko B, Yartsev S, Bauman G (2012) A pooled analysis of arc-based image-guided simultaneous integrated boost radiation therapy for oligometastatic brain metastases. *Radiother Oncol*, **102**: 180–6.
4. Rodrigues G, Zindler J, Warner A, Bauman G, Senan S, Lagerwaard F (2013) Propensity-score matched pair comparison of whole brain with simultaneous in-field boost radiotherapy and stereotactic radiosurgery. *Radiother Oncol*, **106**: 206–9.
5. Rodrigues G, Yartsev S, Yaremko B, Perera F, Dar AR, Hammond A, Lock M, Yu E, Ash R, Caudrelier JM, Khuntia D, Bailey L, Bauman G (2011) Phase I trial of simultaneous in-field boost with helical tomotherapy for patients with one to three brain metastases. *Int J Radiat Oncol Biol Phys*, **80**: 1128–33.
6. Rodrigues G, Eppinga W, Lagerwaard F, de Haan P, Haasbeek C, Perera F, Slotman B, Yaremko B, Yartsev S, Bauman G (2012) A pooled analysis of arc-based image-guided simultaneous integrated boost radiation therapy for oligometastatic brain metastases. *Radiother Oncol*, **102**: 180–6.