

# The role of ferulic acid in the amelioration of kidney changes of rats exposed to electromagnetic radiation

N.F. Khattab and E.S. Marei\*

Health Radiation Research Department National Centre for Radiation Research and Technology, Atomic Energy Authority, Cairo, Egypt

## ABSTRACT

### ► Original article

#### \*Corresponding authors:

Elham Marei, Ph.D.,

Fax: +22 313 9485

E-mail:

[elhammarei@yahoo.com](mailto:elhammarei@yahoo.com)

Revised: February 2018

Accepted: May 2018

Int. J. Radiat. Res., January 2019;  
17(1): 75-85

DOI: 10.18869/acadpub.ijrr.17.1.75

**Background:** Electromagnetic radiation (EMR) is responsible for many hazardous impacts on living organisms. We aimed to investigate the effects of EMR on kidney tissue in rats in order to predict possible effects on human kidneys and to study the radioprotective effect of ferulic acid (FA). **Materials and Methods:** Six rats were used as controls, six rats were used as treated group with FA, six rats were used as irradiated group and six rats were given both FA and exposed to EMR. Blood samples were taken from the heart for IL6, IL10 and TNF- $\alpha$  analysis in the sera, and a part of rat kidneys was homogenized for analysis of total antioxidant capacity (TAC) and lactate dehydrogenase (LDH). Another part of kidney tissue was used for histopathological studies. **Results:** Irradiated rats showed a significant increase in the level of renal markers (urea and creatinine) and inflammatory markers (IL6, IL10 and TNF $\alpha$ ). However, these effects were ameliorated in the group which was exposed to EMR and treated with ferulic acid (FA + EMR). TAC and LDH measured in kidney tissues were significantly decreased in irradiated rats and in FA+ EMR treated group, while significantly increased in FA treated group. **Conclusion:** According to our biochemical and histopathological findings, administration of FA reduced the renal injury effects of EMR.

**Keywords:** Electromagnetic radiation (EMR), Kidney, Rat, ferulic acid (FA).

## INTRODUCTION

Electromagnetic radiation (EMR) cause adverse effects on some physiological processes, cause many concerns about their effects on human health<sup>(1)</sup>, it affects DNA damage, genomic instability, apoptosis, and inflammation by the generation of reactive oxygen species (ROS)<sup>(2)</sup>. The endogenous ROS is normally produced by lipoxygenase and nicotinamide adenine dinucleotide (NAD) oxidase enzyme. It is also produced through leakage of electrons from the mitochondrial respiratory chain<sup>(3)</sup>.

The relationship between biological health effects and electromagnetic fields (EMF) exposure has been widely recognized from epidemiological and experimental studies<sup>(4)</sup>. Assessments of potential risks of electromagnetic frequency include numerous uncertainties referred to as 'idiopathic

environmental intolerance' in order to avoid the implication of causation<sup>(5)</sup>.

The risk level of exposure to radiation depends on the type, frequency of exposure, amount of energy absorbed and duration<sup>(6)</sup>. Although, some exposure may affect people differently depending on age and pre-existing health conditions<sup>(7)</sup>.

Advances in science and technology have introduced many newly developed devices which emit electromagnetic radiation (EMR). These devices include radars, cell phones, radio and television Transmitters, microwave ovens and certain devices used in medical and industrial practice. The most frequent sources of EMR are mobile phones and cell towers. Mobile phones and related telephony technologies transmit information that is encoded into electromagnetic waves in the microwave range around 900 MHz and 1800

MHz<sup>(8)</sup>.

Acute renal failure is characterized by deterioration of renal function over a period of hours to days. This results in the failure of the kidney to excrete nitrogenous waste products to maintain fluid and electrolyte homeostasis<sup>(9)</sup>. The kidneys filtrate 20% of the body blood in every minute and are thereby at high risk of being affected by harmful substances<sup>(10)</sup>. Generally, radiation emitted by the cell phones that are mostly carried on the belts is mostly absorbed by the kidneys as compared to other organs<sup>(11)</sup>.

The mechanism of induced nephrotoxicity is not completely known. However, studies have implicated that reactive oxygen metabolites proved to be the key mediators of tissue injury, abnormal production of such metabolites may damage macromolecules, induce cellular injury as well as necrosis via several mechanisms<sup>(12)</sup>. Accordingly, administration of compounds with antioxidant activity has been successfully used to ameliorate EMR-induced nephrotoxicity. However, none of these strategies were found to be suitable for clinical practice<sup>(13)</sup>.

Several synthetic radioprotectors were tested and found to be good radioprotectors<sup>(14)</sup>. However, high systemic toxicity at their optimum protective dose limits their practical application. These consequences further demand the search for less or non-toxic compounds such as polyphenols (hydroxybenzoic acids and hydroxycinnamic acids flavonoids)<sup>(15)</sup>.

Ferulic acid (4-hydroxy-3-methoxycinnamic acid) is reported to have many pharmacological effects such as anti-inflammatory, anticancer, antidiabetic, anti-atherogenic and neuroprotective<sup>(16)</sup>.

Ferulic acid (FA) is a phenolic compound commonly found in fruits and vegetables such as tomatoes, sweet corn, and rice bran. It arises from metabolism of phenylalanine and tyrosine by Shikimate pathway in plants. FA exhibit a wide range of pharmacological effects including anti-ageing, anti-inflammatory, anticancer, antidiabetic, antiapoptotic, and neuroprotective<sup>(17)</sup>. Ferulic acid possesses antioxidant property by virtue of its phenolic hydroxyl group in its

structure. It is an effective scavenger of free radicals<sup>(18)</sup>.

In the present study, we aimed to investigate the effects of EMR emitted by the cell phones on the rat kidney tissue and to study the radioprotective effect of Ferulic acid against EMR mediated systemic inflammation in rats.

## MATERIALS AND METHODS

The research ethics committee for experimental studies (Human & Animal subject) at National center for research and technology – Egyptian Atomic Energy Authority, Cairo, Egypt has approved the research which carried in compliance with the relevant national laws relating to the conduct of animal experimentation following the 3Rs Principles for animal experimentation (Replace, Reduce and Refine) and is organized and operated according to the CIOMS and ICLAS International Guiding Principles for Biomedical Research Involving Animals 2012.

### *Animals*

Twenty-four Swiss male albino rats were purchased from a suitable supplier and used for this study. The rats were allowed an adaptation period of two weeks in the animal house at the Egyptian Atomic Energy Authority (EAEA). The rats were of similar weight (120 g) and age (three weeks) after the adaptation period. The rats were fed a standard laboratory chow.

### *Electromagnetic waves (EM)*

The whole body of the rats was exposed to 1800 MHz mobile phone-like electromagnetic field, using a microwave generating device, at a power 27 dpm, with an average specific absorption rate (SAR) of two watts per kilogram, at the Egyptian Atomic Energy Authority (EAEA). The exposure was for four hours daily for seven weeks. The microwave generating device was formed of three parts: 1- Hewlett Packard radio-frequency generator 83712B (10 MHz-20 GHz). 2- Hewlett Packard spectrum analyzer 8592L (9 KHz-26.5 GHz). 3- Two horn antennae. The device was placed in a 3 m<sup>2</sup> room.

During exposure to electromagnetic waves the plastic cages containing rats were placed at a distance of 50 cm away from the antennae <sup>(19)</sup>.

### **Treatments**

Ferulic acid was used as the protective and antioxidant agent in the experiment. It was purchased from Sigma-Aldrich, USA as a powder that reconstitutes into a crystal-like suspension in distilled water. Half of the rats used in this experiment were given ferulic acid as a protective agent at a dose of 20 mg/ kg body weight <sup>(18)</sup> orally for two weeks prior to the start of the electromagnetic wave irradiation sessions.

### **Experimental design**

Six rats were used as a control group were neither irradiated by EM waves nor given FA all through the experiment.

Six rats (treated group) were given FA orally 20mg/kg once daily, two weeks before the irradiation sessions starting time. However, as they were considered a positive control they were not exposed to any irradiation throughout the experiment.

Six rats were exposed to EMR (irradiated group), and were not given FA before and they were exposed to electromagnetic irradiation in the manner describe above for 7 weeks.

Six rats were given both FA 20 mg/kg (for two weeks before irradiation) and exposed to electromagnetic irradiation for 7 weeks as described above (treated and irradiated group).

All the experimental rats were sacrificed the day after the last irradiation dose. Blood samples were taken from the heart and centrifuged at 1000 rpm to obtain sera. Both kidneys were perfused then dissected and a part was frozen prior to homogenization, and another part was fixed in paraffin blocks prior to histopathological examination.

Homogenization of these tissues was carried out according to the method described by Graham <sup>(20)</sup> using Potter-Elvehjem homogenizer.

### **These analyses were carried out to specifically detect tissue damage**

1. Lactate Dehydrogenase (LDH) was carried

out using a calorimetric method with kits purchased from Gamma trade, co. Egypt

2. Total Antioxidant capacity (TAC) was carried out using a calorimetric method <sup>(21)</sup> with kits purchased from gamma trade, Egypt.

### **Analysis of the serum**

Estimation of urea: Urea was estimated by the method described previously by Natelson *et al.* 79 to 4.5 mL of serum and kidney homogenates, 3.3 mL of double-distilled water, 0.3 mL of 10% sodium tungstate and 0.3 mL of 0.67 N sulfuric acids were added. The samples were centrifuged (4000 rpm, 15 min, 4 C) and to 1 mL of the supernatant, 1 mL of double-distilled water, 0.4 mL of diacetyl monoxime reagent and 0.6 mL of sulfuric acid– phosphoric acid mixture were added. The samples were incubated in a boiling water bath for 30 min, cooled to room temperature and the absorbance was read at 480 nm in a Shimadzu UV-160 A spectrophotometer. A set of standard urea solutions was also treated similarly and the values were expressed in milligram per deciliter samples <sup>(22)</sup>.

Estimation of creatinine: Creatinine was estimated using the method described previously by Broad and Sirota<sup>37</sup> using Jaffe's reaction. To 1.0 mL of serum and kidney homogenates, 8.0 mL of double-distilled water, 0.5 mL of 2/3 N sulfuric acid and 0.5 mL of 10% sodium tungstate were added. This mixture was centrifuged at 4000 rpm for 15 min at 4 C, 5.0 mL of the clear supernatant was taken to which 1.5 mL of saturated picric acid and 1.5 mL of 0.75 N sodium hydroxide were added. The absorbance was read at 460 nm after 15 min in a Shimadzu UV-160 A spectrophotometer. Standard and blank were also processed similarly and the creatinine levels were expressed in milligram per deciliter <sup>(23)</sup>.

Estimation of TNF- $\alpha$ : TNF- $\alpha$  was measured by enzyme-linked immunosorbent assay (ELISA) technique (enzyme-am-plified sensitivity immunoassay (EASIA) kits, from Sigma-Aldrich, USA <sup>(24)</sup>.

Estimation of interleukin-6 and interleukin-10: To quantify the cytokines interleukin-6 and interleukin-10 in the different

serum samples in the times proposed, the technique used was that of enzyme immunoassay quantitative "sandwich" type (ELISA) using a monoclonal antibody specific for the cytokine to be dosed, enzyme reagent and substrate. We used the kit eBioscience's™ ELISA Ready-SET-Go! for both for interleukin-6 and interleukin-10, with a sensitivity to 2pg/ml and variation of standard curve between 2 and 200 pg/ml for interleukin-6 and sensitivity of 2 pg/ml and variation of standard curve between 2 and 300 pg/ml for interleukin-10<sup>(25-26)</sup>.

**Histopathology of rat kidney tissues**

Dissected rat kidney tissues were fixed in 10% buffered formalin solution followed by dehydration, clearing, embedding in paraffin blocks and cut into fine sections using a microtome. The sections were mounted on glass slides and stained with hematoxylin and eosin according to the method described by Bancroft and Stevens <sup>(27)</sup>. The stained sections were examined by oil immersion light microscopy and several digital images were taken using Kodak digital camera.

**RESULTS**

Exposure of rats to EMR for 4 weeks leads to

significantly increase (<0.001) in urea and creatinine in irradiated group, followed by the (treated and irradiated) and was significantly decreased (<0.001) in the treated group as compared to controls as shown in table1.

Exposure of rats to EMR for 4 weeks leads to significantly increase (<0.001) of IL-6 and TNF-α in irradiated group followed by the (treated and irradiated) group, and significantly decreases in the treated group as compared to controls. However IL-10 was significantly decrease (<0.001) in irradiated group, followed by the( treated and irradiated) group and significantly increase in the treated group as compared to controls as shown in table 2.

Exposure of rats to EMR for 4 weeks leads to significantly decrease (<0.001) in TAC and LDH in the irradiated group followed by the (treated and irradiated) group and significantly increase (<0.001) in the treated group as compared to control as shown in table 3.

The histopathological studies of rat kidney tissues after 4 weeks exposure to EMR show that Hyaline casts, necrosis, apoptosis and swelling were significantly high only in the irradiated group. Dilatation (Bowman's capsule and tubules) was significantly high in irradiated and treated & irradiated groups (with no significant difference between them) as illustrated in table 4 and figures 3a-c.

**Table 1.** Effect of EMR on Urea and Creatinine in sera of experimental rats.

		Groups				P
		Control	Treated	Irradiated	Treated & Irradiated	
Urea (mg/dL)	Mean±SD	34.9±5.5	37.0±9.3	81.4±14.0	53.3±4.8	<0.001*
	Range	25.2–40.8	26.2–48.6	58.7–101.5	47.2–60.1	
	95% CI	29.1–40.7	27.3–46.8	66.7–96.1	48.2–58.4	
	HG	a	A	C	B	
Creatinine (mg/dL)	Mean±SD	0.19±0.06	0.23±0.05	1.58±0.42	0.58±0.08	<0.001*
	Range	0.12–0.26	0.16–0.28	0.97–2.03	0.47–0.68	
	95% CI	0.13–0.25	0.18–0.28	1.15–2.02	0.49–0.67	
	HG	a	A	C	b	

ANOVA test with post hoc Tukey test, CI: Confidence interval, HG: Homogenous groups, \*Significant

**Table 2.** Effect of EMR on IL-6, IL-10 and TNF- $\alpha$  in sera of rats of the experimental groups.

		Groups				P
		Control	Treated	Irradiated	Treated & Irradiated	
IL-6 (pg/mL)	Mean $\pm$ SD	31.6 $\pm$ 3.7	33.7 $\pm$ 5.5	111.8 $\pm$ 14.2	74.5 $\pm$ 15.5	<0.001*
	Range	25.9–36.1	26.6–40.5	84.5–123.7	60.9–102.8	
	95% CI	27.7–35.4	27.9–39.5	96.9–126.6	58.2–90.7	
	HG	A	A	C	b	
IL-10 (pg/mL)	Mean $\pm$ SD	165.0 $\pm$ 24.6	168.2 $\pm$ 21.3	96.1 $\pm$ 15.4	133.0 $\pm$ 13.6	<0.001*
	Range	143.5–205.0	138.6–193.8	75.6–113.4	119.3–152.7	
	95% CI	139.1–190.8	145.8–190.5	79.9–112.3	118.8–147.3	
	HG	A	A	C	b	
TNF- $\alpha$ (pg/mL)	Mean $\pm$ SD	31.1 $\pm$ 4.0	38.2 $\pm$ 3.6	138.8 $\pm$ 9.7	87.8 $\pm$ 13.2	<0.001*
	Range	26.9–37.5	32.6–42.5	125.5–149.2	73.9–108.2	
	95% CI	26.8–35.3	34.5–42.0	128.6–148.9	74.0–101.6	
	HG	A	A	C	b	

ANOVA test with post hoc Tukey test, CI: Confidence interval, HG: Homogenous groups, \*Significant

**Table 3.** Effect of EMR on TAC and LDH in rats.

		Groups				P
		Control	Treated	Irradiated	Treated & Irradiated	
TAC (nmol/mL)	Mean $\pm$ SD	25.0 $\pm$ 3.8	29.7 $\pm$ 5.1	11.0 $\pm$ 2.9	17.8 $\pm$ 2.0	<0.001*
	Range	21.2–30.2	24.2–38.4	8.0–16.1	14.5–19.7	
	95% CI	21.1–29.0	24.3–35.0	8.0–14.0	15.7–19.9	
	HG	a	a	c	b	
LDH (IU/L)	Mean $\pm$ SD	195.5 $\pm$ 10.8	179.9 $\pm$ 25.1	123.3 $\pm$ 11.6	154.9 $\pm$ 5.9	<0.001*
	Range	181.4–213.1	150.4–216.7	112.4–145.7	148.3–162.7	
	95% CI	184.1–206.8	153.6–206.2	111.1–135.5	148.6–161.1	
	HG	a	a	c	b	

ANOVA test with post hoc Tukey test, CI: Confidence interval, HG: Homogenous groups, \*Significant

**Table 4.** Renal pathology of the study groups.

		Groups				P
		Control	Treated	Irradiated	Treated & Irradiated	
Hyaline	Mean $\pm$ SD	0 (0.0%)	0 (0.0%)	6 (100.0%)	1 (16.7%)	<0.001*
	HG	A	A	b	a	
Necrosis	Mean $\pm$ SD	0 (0.0%)	0 (0.0%)	6 (100.0%)	1 (16.7%)	<0.001*
	HG	A	A	b	a	
Apoptosis	Mean $\pm$ SD	0 (0.0%)	0 (0.0%)	6 (100.0%)	1 (16.7%)	<0.001*
	HG	A	A	c	b	
Swelling	Mean $\pm$ SD	0 (0.0%)	0 (0.0%)	6 (100.0%)	1 (16.7%)	<0.001*
	HG	A	A	b	a	
Dilatation	Mean $\pm$ SD	0 (0.0%)	0 (0.0%)	6 (100.0%)	5 (83.8%)	<0.001*
	HG	A	A	b	b	

Fisher's Exact test with post hoc Bonferroni test, HG: Homogenous groups, \*Significant

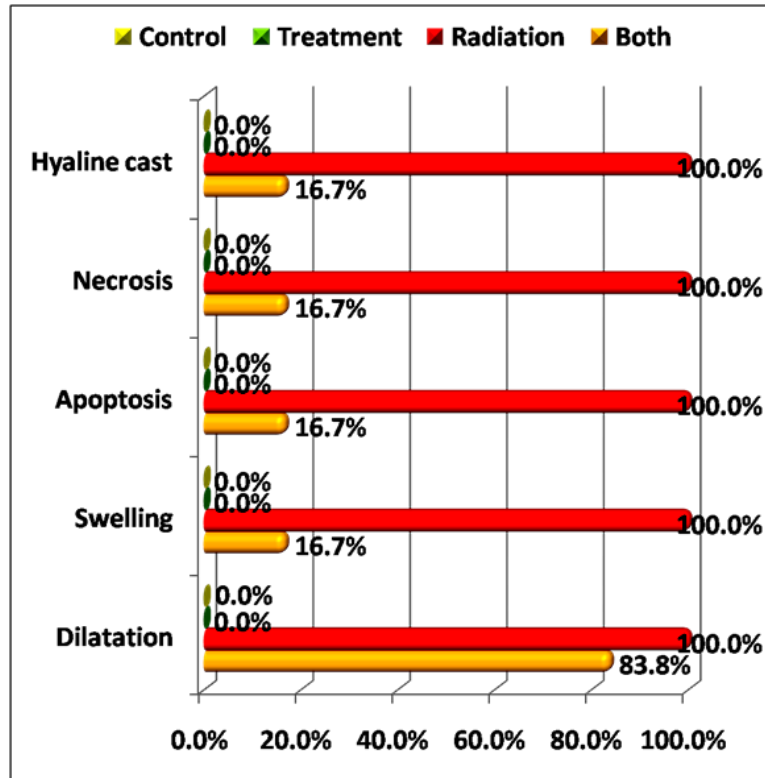


Figure 1. Comparison between the experimental groups regarding renal pathology.

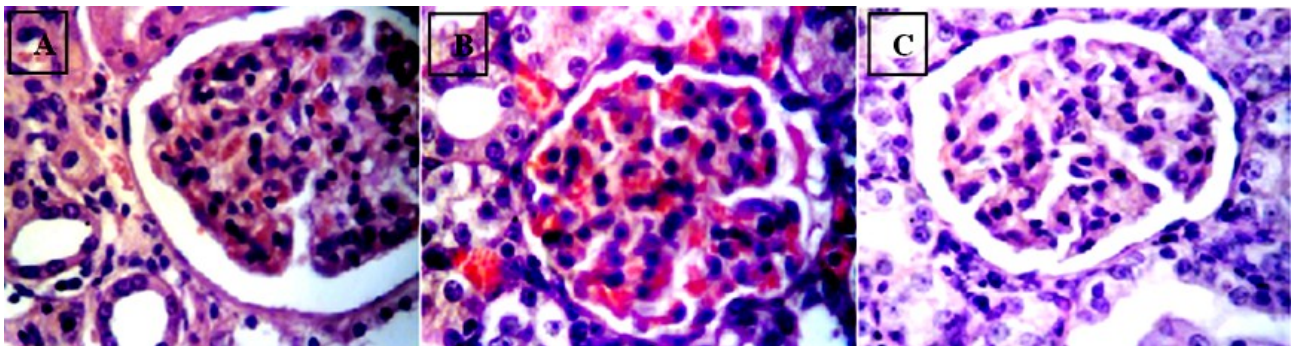
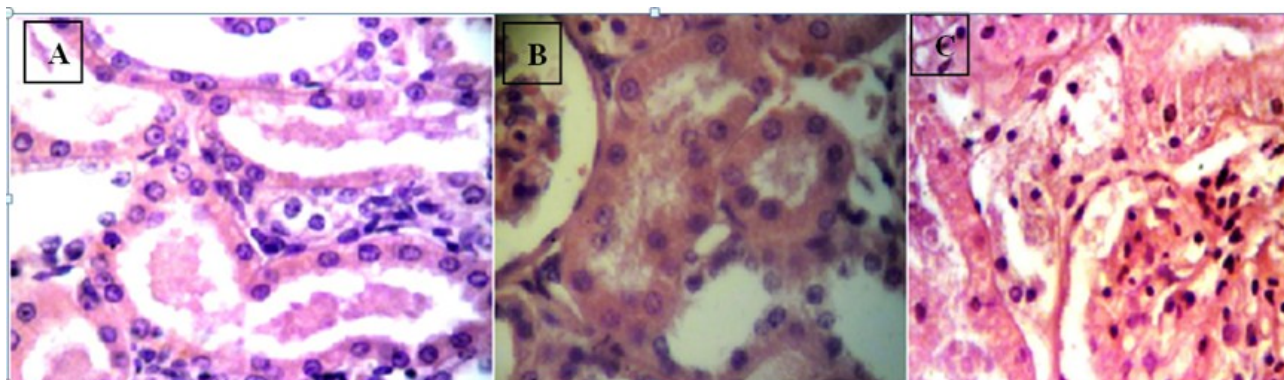


Figure 2. A. Kidney of control rat showing normal structure (H& E × 400). B. Kidney of FA treated rat with no radiation showing normal renal structure (H& E × 400). C. Kidney of irradiated treated rat showing normal structure with dilation of some tubules (H& E × 400).



**Figure 3.** Kidney of irradiated rat showing: **A)** Necrotic renal tubule with hyaline cast inside the tubule, tubular damage with hyaline deposition **B)** Dilatation of Bowman's capsule, formation of large spaces between tubules, perivascular oedema and inflammatory cellular infiltrate. Apoptosis.

## DISCUSSION

Cell phones are the leading devices that emit EMR and have an increasing use worldwide. The effects of EMR emitted by these devices and base stations on human body have still not been clarified<sup>(28)</sup>. Radiofrequency waves emitted by cell phones are thought to cause detrimental effects at cellular and molecular level<sup>(29)</sup>. Devrim and coworkers<sup>(30)</sup> reported that EMR led to an increase in the levels of oxygen radicals in the kidney tissue. Other studies have indicated that the kidneys are radiation-sensitive organs. In our study, negative effects of EMR on the kidney tissue were shown by light microscopic examination. This tissue damage was thought to be associated with oxygen radicals. We showed tubular damage in our study which plays an important role in all causes of acute renal failure<sup>(31)</sup>.

Several synthetic radioprotectors like lipoic acid, deoxyspergualin, cysteine, cysteamine, 2-mercaptopyruvate (2-MPG) were tested and found to be good radioprotectors<sup>(32)</sup>. However, high systemic toxicity at their optimum protective dose limits their practical application. These consequences further demand the search for less or non-toxic

compounds from biological origin. These compounds include polyphenols such as hydroxybenzoic acids, hydroxycinnamic acids, anthocyanins, proanthocyanidins, and flavonoids. Phenolic compounds from dietary plants are known to be good scavengers of reactive oxygen species<sup>(33)</sup>.

The aim of the present study was to find out the protective role of FA against EMR radiation mediated systemic inflammation and to assess whether the nephrotoxic effect by exposure to EMR (1800 MHz) is treated or ameliorated with FA which is a herbal compound possessing a strong antioxidant property, and which is physiologically safe but tough against the oxidative species.

Serum levels of urea and creatinine were estimated in all groups; urea and creatinine being significantly high in group of irradiated rats followed by group that treated with FA then irradiated and significantly decrease in control group and group that treated with FA only with no significant difference between them. The results of this study show that, irradiated group produced a typical pattern of nephrotoxicity which was manifested by increase in renal function parameters. On the other hand, FA administration pre irradiation showed a

significant decrease in the levels of creatinine, urea in serum compared to irradiated group. These results were also reported by Manikandan *et al.*,<sup>(34)</sup> who detected an elevation in serum urea and creatinine post irradiation also. The protective effect of FA on the kidney markers can be attributed to its antioxidant properties as it has been found that reactive oxygen species may be involved in the impairment of glomerular filtration rate<sup>[35-36]</sup>. In the present study the effect of FA as an agent that confers protection against the systemic inflammation induced by radiation has been elaborated. We analyzed the expression of different inflammatory markers such as TNF- $\alpha$ , IL-6 and IL-10 in sera of all groups. The results explored the anti-inflammatory role of FA against EMR induced systemic inflammation mediated by oxidative stress. IL-6 and TNF- $\alpha$  were significantly high in irradiated group, followed by FA treated group and is significantly low in control and in FA treated then irradiated group with no significant difference between them. IL-10 was significantly low in irradiated group, followed by FA +IR and significantly high in control group and FA treated group with no significant difference between them. Similar results of this study were also reported by Das and colleagues<sup>(37)</sup> who studied the effect of FA and its protective role in irradiated mice. They found that the levels of proinflammatory cytokines such as IL-6 and TNF- $\alpha$  in serum were decreased by administration of FA to irradiated group. Given that IL-10 is a critical regulatory cytokine, decreased levels have the potential to influence hyper immune situations. The development of an IL-10 knock out mouse model has been a great tool for assessing IL-10 deficiencies and the potential for hypersensitive responses and autoimmunity<sup>(38)</sup>. In our work, IL-10 was significantly low in irradiated group, followed by FA+IR group and significantly high in control and FA treated groups with no significant difference between them showing the protective effect of FA which is detected by increasing serum levels of IL-10 in irradiated and treated group. Several studies

reported that long-term exposure to radiation leads to enhancement of free radical presence after electromagnetic field exposure<sup>(38)</sup>. Excessive production of free radical specifically reactive oxygen species (ROS), have been reported in wide variety of clinical disorders<sup>(39)</sup>. This may show that FA exerts its protective effects by effectively quenching the free radicals, preventing them from attacking the membrane, protecting the membrane, inhibiting the leakage of marker enzymes into circulation, and improving the antioxidant status in circulation<sup>(39)</sup>. In this study, total antioxidant capacity (TAC) was measured in the sera of the 4 groups. It was significantly decrease in irradiated rats followed by treated +IR group and was significantly increase in control and FA treatment groups. These were in agreement with Raggy 2015<sup>[1]</sup> who reported that total antioxidant capacity decrease after exposure to 900-MHz-electromagnetic waves in brain, kidney and liver of male rats. Other studies showed that chronic exposure to RF-EMW decreases the activity of catalase (CAT), superoxide dismutase (SOD) and glutathione peroxidase (GSH-Px), and thus decreases the total antioxidant capacity. The present study showed significant decrease in LDH in the tissues both kidneys after exposure to EMR. The Enzyme LDH is considered as a general marker of cellular health, these observations indicate that exposure to the radiofrequency radiation increases cell death and changes the homeostasis of the tissues leading to increase in LDH in serum and a simultaneous decrease in their levels in the liver and intestinal tissues<sup>(40)</sup>. Janakiraman *et al.*,<sup>(41)</sup> studied the radioprotective efficacy of Ferulic acid (FA) against whole body gamma radiation in Swiss albino mice. A significant increase in the antioxidant enzymatic status and decreased lipid peroxidation marker levels were observed in FA pretreated group, when compared to the irradiated animals.

The biochemical and histopathological findings of induced renal injury in this study have produced persuasive evidence incriminating oxidative stress determined by

measurements of cytotoxic inflammatory cells (IL6, TNF $\alpha$ ), TAC and LDH shows the role of Ferulic acid in ameliorating such effects<sup>(41)</sup>. Several studies have indicated that the kidneys are radiation-sensitive organs<sup>(42)</sup>. In our study, light microscopy of kidney tissue revealed tubular damage with hyaline deposition, glomerular damage, dilatation of Bowman's capsule, formation of large spaces between tubules, perivascular oedema and inflammatory cellular infiltrate. These changes were found to be ameliorated in FA treated and irradiated group showing reduced dilated renal tubules with reduced inflammatory cellular infiltrate and disappearance of intratubular hyaline casts. Our results are in coordination with Koca *et al.*,<sup>(43)</sup> which detected similar histological findings in irradiated rats before and after FA treatment. Furthermore, Koca *et al.*,<sup>(44)</sup> had stated that electron microscopic examination of the kidney tissues in irradiated rats revealed that podocytes had a regular appearance, whereas irregular thickening of the basement membrane, irregularity of the capillary endothelium, and large dissociation of the junctions between the tubule cells were detected. In addition, they stated that observation of glomerular damage indicates the severity of this damage.

In summary, we have confirmed that FA has a protective role against nephrotoxicity induced by EMR exposure. According to our biochemical findings, which were supported by histopathological analysis, administration of FA reduced the effects of EMR on rat renal tissues, thus reducing renal injury.

**Conflicts of interest:** Declared none.

## REFERENCES

1. Ragy MM (2015) Effect of exposure and withdrawal of 900-MHz-electromagnetic waves on brain, kidney and liver oxidative stress and some biochemical parameters in male rats. *Electromagn Biol Med*, **34(4)**: 279-284.
2. Sinha M, Das K, Manna K, Datta S, Ray T, *et al.* (2012) Epicatechin ameliorates ionising radiation-induced oxidative stress in mice liver. *Free Radic Res*, **46**: 842-849.
3. Chen Q, Olashaw N, Wu J (1995) Participation of reactive oxygen species in the lysophosphatidic acid-stimulated mitogen-activated protein kinase activation pathway. *J Biol Chem*, **270**: 28499-28502.
4. Abdel Rassoul G, El-Fateh OA, Salem MA, Michael A Farahat F, El Batanouny M, *et al.*, (2007) Neurobehavioral effects among inhabitants around mobile phone base stations. *Neurology and Toxicology*, **28(2)**: 434-440.
5. WHO, 2000. Electromagnetic fields and Public health. Fact sheet No193
6. Balmori A (2005) Possible effects of electromagnetic fields from phone masts on a population of white stork (*Ciconia ciconia*). *Electromagnetic Biology and Medicine*, **24**: 109-119.
7. Santini R, Santini P, Danze JM, LeRuz P, Seigne M (2003) Symptoms experienced by people in vicinity of base stations: 11/ incidences of age, duration of exposure, location of subjects in relation to the antennas and other electromagnetic factors. *Pathology and Biology*, **51**: 412-415.
8. Aberumand M, Esrafil Mansouri E, Pourmotahari F, Mirlohi M, Abdoli Z (2016) Biochemical and Histological Effects of Mobile Phone Radiation on Enzymes and Tissues of Mice. *RJPBCS*, **7(5)**: 1963.
9. Finn WF (1990) Diagnosis and management of acute tubular necrosis. *Med Clin North Am*, **74**: 873-891.
10. Leszczynski D, Joenvaara S, Reivinen J, Kuokka R (2002) Non thermal activation of the hsp27/p38MAPK stress pathway by mobile phone radiation in human endothelial cells: molecular mechanism for cancer- and blood-brain barrier-related effects. *Differentiation*, **70**: 120-129.
11. Parlakpinar H, Ozer MK, Sahna E, Vardi N, Cigremis Y, Acet A (2003) Amikacin-induced acute renal injury in rats: protective role of melatonin. *J Pineal Res*, **35**: 85-90.
12. Cuzzocrea S, Mazzon E, Dugo L, *et al.* (2002) A role for superoxide in gentamicin-mediated nephropathy in rats.

- Eur J Pharmacol*, **450**: 67–76.
13. Karahan I, Atessahin A, Yilmaz S, Ceribasi AO, Sakin F (2005) Protective effect of lycopene on gentamicin-induced oxidative stress and nephrotoxicity in rats. *Toxicology*, **215**: 198–204.
  14. Chander V, Singh D, Chopra K (2005) Reversal of experimental myoglobinuric acute renal failure in rats by quercetin, a bioflavonoid *Pharmacology*, **73**: 49–56.
  15. Rodrigo R, Bosco C, Herrera P, Rivera G (2004) Amelioration of myoglobinuric renal damage in rats by chronic exposure to flavonol rich red wine. *Nephrol Dial Transplant*, **19**: 2237–2244.
  16. Srinivasan M, Sudheer AR, Menon VP (2007) Ferulic Acid: therapeutic potential through its antioxidant property. *J Clin Biochem Nutr*, **40**: 92–100.
  17. Kashmira JG, Shashank B, Kshirsagar, Rajkumari SS (2012) Ferulic acid a comprehensive pharmacology of an important bioflavonoid. *IJPSR*, **3(1)**: 700–710.
  18. Krasteva I, Nikolova I, Danchev N, Nikolov S (2004) Phytochemical analysis of ethyl acetate extract from *Astragalus corniculatus* Bieb. and brain antihypoxic activity, *Acta Pharm*, **54**: 151–156.
  19. Manikandan R, Beulaja M, Thiagarajan R, Pandi M, et al. (2013) Ameliorative effect of ferulic acid against renal injuries mediated by nuclear factor kappa B during glycerol-induced nephrotoxicity in wister rats. *Renal failure*, 1–12.
  20. Graham JM (2002) Homogenization of Mammalian tissue. *Scientific World Journal*, **13(2)**: 1626–9.
  21. Ruszkiewicz J and Albrecht J (2015) Changes of the thioredoxin system, glutathione peroxidase activity and total antioxidant capacity in rat brain cortex during acute liver failure: modulation by L-histidine. *Neurochem Res*, **40(2)**: 293–300.
  22. Natelson S, Scott ML, Beffa C (1951) A rapid method for the estimation of urea in biological fluids. *Am J Clin Path*, **21**: 275–281.
  23. Broad J and Sirota JH (1948) Renal clearance of endogenous creatinine in man. *J Clin Invest*, **27**: 646.
  24. Ahn J, Kim SG, Kim MK, Kim DW, Lee JH, Seok H, Choi JY (2016) Topical delivery of hexylresorcinol promotes wound healing via tumor necrosis factor- $\alpha$  suppression. *Burns*, **42**: 1534–1541.
  25. Barton, B.E. (1997) Marker data were analyzed in relation to protocol-defined clinical disease progression. *Clin Immunol Immunopathol* **85**: 16.
  26. Moore K, Vieira P, Fiorentino D, Trounstein M, Khan T, Mosmann R (1990) Homology of cytokine synthesis inhibitory factor (IL-10) to the Epstein-Barr virus gene BCRF1. *Science*, **248(4960)**: 1230–1234.
  27. Bancroft JD and Stevens A (1992) Theory and Practice of Histological Techniques, 3<sup>rd</sup> Edition, Churchill Livingstone. Edinburg, London, Melbourne and New York.
  28. Meral I, Mert H, Mert N (2007) Effects of 900-MHz electromagnetic field emitted from cellular phone on brain oxidative stress and some vitamin levels of guinea pigs. *Brain Res*, **1169**: 120–4.
  29. Oral B, Guney M, Ozguner F (2006) Endometrial apoptosis induced by a 900-MHz mobile phone: preventive effects of vitamins E and C. *Adv Ther*, **23**: 957–973.
  30. Devrim E, Erguder IB, Kilicoglu B, Yaykasli E, Cetin R, Durak I (2008) Effects of Electromagnetic Radiation Use on Oxidant/Antioxidant Status and DNA Turn-over Enzyme Activities in Erythrocytes and Heart, Kidney, Liver, and Ovary Tissues From Rats: Possible Protective Role of Vitamin C. *Toxicol Mech Methods*, **18**: 679–83.
  31. Cassady JR (1995) Clinical radiation nephropathy. *Int J Radiat Oncol Biol Phys*, **31**: 1249–56.
  32. Hensley ML, Schuchter LM, Lindley C, Meropol NJ, Cohen GI, et al. (1999) American Society of Clinical Oncology Clinical practice guidelines for the use of chemotherapy and radiotherapy protactants. *J Clin Oncol*, **17**: 3333–55
  33. Hughes AK, Stricklett K, Padilla E, Kohan DE (1996) Effect of oxygen species on endothelin-1 production by human mesangial cells. *Kidney Int*, **49**: 181–9.
  34. Manikandan R, Manikandan B, Thiagarajan R, Asokan P, Subramanian P, Velaytham M, et al. (2012) Protective effect of ferulic acid and resveratrol against alloxan-induced diabetes in mice. *Eur J Pharmacol*, **690**: 226–235.
  35. Sarumathy K, Vijay T, Jayakanthia J, Dhana Rajan MS (2011) A protective effect of *Caesalpinia sappan* (CS) on acetaminophen induced nephrotoxicity and oxidative stress in male albino rats. *J Pharmacol Toxicol*, **2**: 2229–6859.
  36. Liu B, Tonkonogy SL, Sartor RB (2011) Antigen-presenting cell production of IL-10 inhibits T-helper 1 and 17 cell responses and suppresses colitis in mice. *Gastroenterology*, **141**: 653–62.
  37. Das DK, Chakraborty A, Sinha M, Manna K, Mukherjee D, et al. (2013) Modulatory role of quercetin against gamma radiation mediated biochemical and morphological alterations of Red Blood Cell. *Int J Radiat Biol*, **89(6)**: 471–81.
  38. Berg DJ, Leach MW, Kuhn R, et al. (1995) Interleukin 10 but not interleukin 4 is a natural suppressant of cutaneous inflammatory responses. *J Exp Med*, **182**: 99–108.
  39. Roy S NY, Eckert V, Traber M G, Mori A, Liburdy R, Packer L (1995) The phorbol 12-myristate 13-acetate (PMA)-induced oxidative burst in rat peritoneal neutrophils is increased by a 0.1 mT (60Hz) magnetic field. *FEBS Lett*, **376(3)**: 164–6.
  40. Shivashankara AR (2015) Effect of cell phone use on salivary total protein, enzymes and oxidative stress markers in young adults: A pilot study. *J Clin Diagnostic Res*, **9(2)**: 19–22.
  41. Janakiraman S, Arumugam K, Venkata RB, Nagarajan RP (2012) Ferulic acid, a dietary phenolic acid, modulates radiation effects in Swiss albino mice. *Eur J Pharmacol*, **691**: 268–74.
  42. Sudheer AR, Kalpana C, Srinivasan M, Menon VP (2005)

### *Khattab and Marei / amelioration effect of ferulic acid*

Ferulic acid modulates lipid profiles and prooxidant/ antioxidant status in circulation during nicotine-induced toxicity: A dose dependent study. *Toxicology Mechanisms and Methods*, **15(6)**: 375–81.

43. Ozguner F, Oktem F, Ayata A, Koyu A, Yilmaz HR (2005) A novel antioxidant agent caffeic acid phenethyl ester prevents longterm mobile phone exposure-induced renal

impairment in rat. Prognostic value of malondialdehyde, N-acetyl-beta-Dglucosaminidase and nitric oxide determination. *Mol Cell Biochem*, **277**: 73-80.

44. Koca O, Gökçe AM, Öztürk MI, Ercan F, Yurdakul N, Karaman MI ( 2013) Effects of intensive cell phone (Philips Genic 900) use on the rat kidney tissue. *Urol J*, **10 (2)**: 886-91.

