

Protective capacity of Rosemary extract against radiation induced hepatic injury in mice

D. Soyal, A. Jindal, I. Singh, P.K. Goyal*

Radiation and Cancer Biology Laboratory, Department of Zoology, University of Rajasthan, Jaipur, India

Background: This study was carried out to observe the radioprotective effects of *Rosemarinus officinalis* leaves extract (ROE) against radiation-induced histopathological alterations in liver of mice. **Materials and Methods:** Adult Swiss albino mice were exposed to 6 Gy gamma radiation in the presence (experimental) or absence (control) of ROE to study the qualitative and quantitative alterations in the liver. **Results:** Normal hepatocyte counts were found to be declined up to day 10th post-irradiation in both the groups but thereafter such cells increased reaching to near normal level at the last autopsy interval, only in experimental group. Contrary, frequency of abnormal hepatocytes increased up to day 10th after irradiation in both the groups. Binucleate hepatic cells showed a biphasic mode of elevation after irradiation, first at 12 hrs and second on day 10th in control group; whereas in experimental group, the elevation was comparatively less marked and even the second peak was not evident. Irradiation of animals resulted in an elevation in lipid peroxidation (LPx) and a significant decrease in glutathione (GSH) concentration in liver as well as in blood. Conversely, experimental group showed a significant decline in LPx and an elevation in GSH concentration. **Conclusion:** These results indicate that *Rosemarinus officinalis* leaves extract (ROE) is able to protect the liver of Swiss albino mice against radiation induced histopathological alterations. Iran. J. Radiat. Res., 2007; 4 (4): 161-168

Keywords: Irradiation, liver, *Rosemarinus officinalis*, Swiss albino mice, hepatic cell counts.

INTRODUCTION

It is well known that high doses of radiation are hazardous for living systems but they are inseparable from human beings because their uses are unlimited in the various fields for the benefits of mankind. Earlier the clinical substances, which could minimize the pathological change in the living systems after exposure to ionizing radiation, were looked into. Therefore, attempts were made in this direction from

early 50's but the agents discovered so far are not safe to use for human beings due to high toxicity at their effective dose level. Some of them are 2-mercaptopropionylglycine⁽¹⁾ WR-2721⁽²⁾, deoxyspergualin⁽³⁾, estradiol⁽⁴⁾, beer⁽⁵⁾ and diltiazem⁽⁶⁾.

Medicinal plants are the local heritage with global importance. World is enclosed with a rich wealth of medicinal plants. Herbs have always been the principle form of medicine in India and presently they are becoming popular throughout the developed world, as people strive to stay healthy in the face of chronic stress and pollution, and to treat illness with medicines that work in concert with the body's own defense. The ethnic people have provided several miraculous plants of medicinal value to modern civilization. Herbal drugs offer an alternative to the synthetic radioprotective compounds which are either non-toxic or less toxic.

The study of plants as modifiers of radiation effects is a relatively new area of research. Many phytochemicals are known to be antioxidants, and are consumed in the diet and thus may help to protect humans from damages induced by radiation. Most of these plant extracts and phytochemicals are non-toxic and inhibit radiation-induced lipid peroxidation in animal model systems⁽⁷⁻¹¹⁾.

Rosemary (*Rosemarinus officinalis* Linn.), belonging to family labiateae, is widely found along the north and south coasts of the Mediterranean sea and also in the sub-Himalayan areas in India, is a well reputed aromatic and medicinal herb⁽¹²⁾. Rosemary is

*Corresponding author:

Dr. P. K. Goyal, Radiation and Cancer Biology Laboratory, Department of Zoology, University of Rajasthan, Jaipur 302004, India.

E-mail: pkgoyal2002@rediffmail.com

an evergreen branched bushy shrub, attaining a height of about one meter with upright stems, whitish blue flowers and dark green leaves. Rosemary, also called as "Dew of the sea", has a long history of medicinal use⁽¹³⁾. It is used for flavoring food, a beverage drink, as well as in cosmetics; in folk medicine it is used as an anti-spasmodic in renal colic and dysmenorrhoea, in relieving respiratory disorders and to stimulate growth of hairs. It has also been used as an analgesic, anti-rheumatic, carminative, diuretic, expectorant, anti-epileptic, hepato-protective, anti-mutagenic, anti-oxidant and anti-cancer but its radioprotective potential is not yet known⁽¹⁴⁻¹⁹⁾. Leaves of *Rosemarinus officinalis* (known for their antioxidant activity) are not only used in food industry but also have been shown to be safe and anti-toxic in animal tests^(20, 21).

Liver is the primary organ of drug metabolism. It plays a key role as detoxification agency in the body. Any damage to this organ may cause serious disorders in the form of various diseases which can be observed in the form of histopathological and biochemical lesions. Therefore, the present investigation is an attempt to study the possible modulatory role of rosemary plant against radiation-induced histopathological lesions in the liver of mice.

MATERIALS AND METHODS

Animal care and handling

Adult male Swiss albino mice (6-8 weeks old) weighing 25 ± 2 gm from an inbred colony were used for the present study. They were maintained under controlled conditions of temperature and light (light: dark, 10h:14h), and were fed with balanced food in the form of pellets manufactured by Hindustan Lever's Ltd., India and water was provided *ad libitum*. Animal care and handling were performed according to guidelines issued by World Health Organization (Geneva, Switzerland) and the Indian National Science Academy (New Delhi, India). Four to

six animals were housed in a polypropylene cage containing sterile paddy husk (procured locally) as bedding throughout the experiment. Tetracycline water was given once a fortnight as preventive measure against infection. The departmental ethical committee approved the study.

Irradiation

The Cobalt Teletherapy Unit (ATC-C9, supplied by Atomic Energy Agency Ltd., Canada) at Cancer Treatment Centre, Department of Radiotherapy, SMS Medical College and Hospital, Jaipur, was used for irradiation. Unanesthetized mice were restrained in a well ventilated perspex box and whole-body exposed to 6 Gy gamma radiation at a distance (SSD) of 77.5 cm from the source to deliver the dose rate of 0.85 Gy/min.

Preparation of *Rosemarinus officinalis* extracts (ROE)

Rosemarinus officinalis Linn. was identified by a competent botanist from Herbarium, Department of Botany, University of Rajasthan, Jaipur. Fresh leaves of this plant were collected during October through December of the year. These leaves were carefully cleaned, shade dried, powdered in an electronic mixer grinder and extracted with double distilled water (DDW) by refluxing for 36 hrs (12 hrs \times 3). The ROE thus obtained was vacuum evaporated so as to get in powder form. For the experiment, ROE was redissolved in the sterile double distilled water and the dose of required concentration was prepared.

Selection of optimum dose of ROE

Dose selection of ROE was done in a separate experiment based on drug tolerance study⁽²²⁾. Various doses of *Rosemarinus officinalis* extract (100, 200, 400, 800, 1000, 1500 and 2000 mg/kg.b.wt/day) were orally administered for 5 consecutive days against gamma irradiation (8 Gy) and from which 1000 mg/kg.b.wt/day was found as optimum dose, and the same was used for further experimentation.

Modification of radiation response

Swiss albino mice, for this study, were divided into four groups. Animals in Group-I were administered orally with DDW (volume equal to ROE) to serve as normal (vehicle treated) while animals in Group-II were given ROE orally at a dose of 1000 mg/kg b.wt., once in a day for 5 consecutive days. Animals of Group-III received an equal volume of DDW (as in Group-I) while animals in Group-IV (experimental) were given ROE (as in Group-II). After 30 minutes of DDW or ROE administration on 5th day, animals of Group III and IV were whole-body irradiated to Co⁶⁰ gamma rays.

Animals of all the groups were monitored daily for weight change, behavioral changes, mortality, morbidity, sickness, and food and water consumption till their sacrifice or survival.

Animals were autopsied at 12 hrs, 24 hrs, 3rd day, 5th day, 10th day, 20th day and 30th day post-treatment and their livers were removed and processed for routine histology. The tissue was fixed in Bouin's fixative for 24 hrs and dehydrated in alcohol grades, cleared in xylene and embedded in paraffin. Routine 5 µm thick sections were cut, fixed on clean glass slides, stained with hematoxylin-eosin and mounted in DPX. Ten good transverse sections per animal were observed under binocular research microscope for quantitative as well as qualitative study. For this purpose, the total numbers of hepatocytes, in 1 mm² area of the section, were counted with the help of a planimeter and were classified as normal, binucleated and abnormal (hepatocytes showing karyolysis, pycnosis, necrosis, karyorrhexis, cytoplasmic degranulation and vacuolation were considered as abnormal) hepatocytes and their numbers were expressed in percentages.

Biochemical estimation

Glutathione (GSH) assay: Liver and blood glutathione (GSH) levels were estimated, after 1 hr. of DDW/ROE/radiation treatment, according to the methods of Moron *et al.* ⁽²³⁾ and Beutler *et al.* ⁽²⁴⁾ respectively. The

absorbance was read at 412 nm using a Systronic UV-VIS-108 Spectrophotometer.

Lipid peroxidation assay: The lipid peroxidation (LPx) level in liver and serum was measured by the assay of thiobarbituric acid reactive substances (TBARS) using the method of Ohkhawa *et al.* ⁽²⁵⁾ in which the absorbance was read at 532 nm with a Systronic UV-VIS-108 Spectrophotometer.

Statistical analysis

The statistical significance of the differences between normal and DDW+ irradiated (control) as well as control and ROE + irradiated (experimental) set ups were evaluated by using the Student's *t*-test.

RESULTS

The animals of DDW+irradiation group (control) showed signs of radiation sickness within 3-5 days after exposure to 6 Gy of gamma irradiation. Reduction in food and water intake, watering of eyes, weight loss, epilation, irritability, lethargy, diarrhea, ruffling of hairs and slow gait in animals were the main symptoms appeared after irradiation.

No toxic effects were observed in terms of sickness, body weight, urination, defecation pattern and mortality in animals treated with ROE alone, once daily for 5 consecutive days. The pretreatment of mice with ROE (experimental group) delayed the onset of radiation-induced mortality and symptoms of sickness as compared to control group.

Figure 1 shows insignificant variations in the number of different types of hepatocytes in the animals treated with ROE alone as compared to normal group (without any treatment). In 6 Gy irradiated group, the number of normal hepatocytes decreased significantly and progressively from 12 hrs to day 10th. Thereafter, the percentage of such cells increased slightly from 20th day and later improved considerably on 30th day. When ROE was administered prior to irradiation, a remarkable recovery in normal cells was revealed with a highly significant

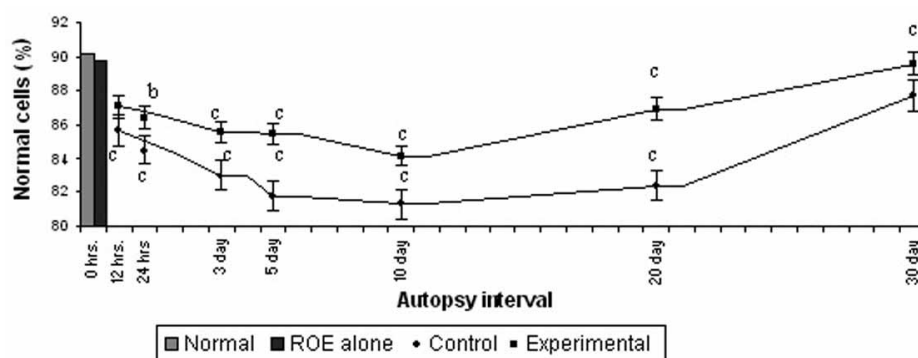


Figure 1A. Variations in Normal hepatocytes (%) in mice after exposure to 6 Gy gamma radiation in the presence (Experimental) or absence (Control) of *Rosemarinus officinalis* extract (ROE).

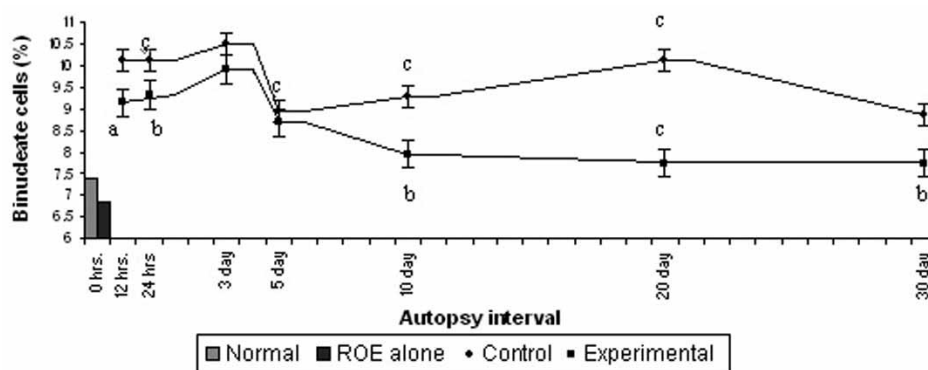


Figure 1B. Variations in Binucleate hepatocytes (%) in mice after exposure to 6 Gy gamma radiation in the presence (Experimental) or absence (Control) of *Rosemarinus officinalis* extract (ROE).

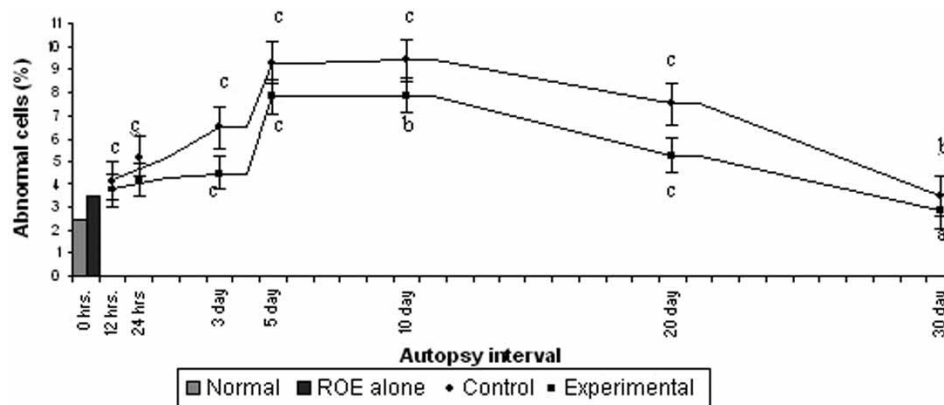


Figure 1C. Variations in Abnormal hepatocytes (%) in mice after exposure to 6 Gy gamma radiation in the presence (Experimental) or absence (Control) of *Rosemarinus officinalis* extract (ROE). Significance level between Normal V/s Control and Control V/s Experimental (p value: a= 0.05, b= 0.01, c=0.001).

difference at all the autopsy intervals. A normal count of such hepatocytes was scored at the end of experimentation (i.e. 30th day) in experimental group; whereas in control group, such number was significantly lesser than normal at this interval. The reduction in normal hepatocytes was observed maximum

(9.44%) on day 10th in without ROE irradiated mice; while in protected mice (with ROE), it was 6.70%.

Percent increase in binucleated hepatocytes number was found to be biphasic in 6 Gy irradiated control mice. The first elevation was observed at 12 hrs and second

on day 10th with a subsequent increase on day 20th. However, the number of such cells decreased later, but the normal level could not be regained even till the end of experimentation. In ROE treated animals (experimental), the frequency of such hepatocytes increased from 12 hrs to 3rd day. After 5th day, their counts decreased gradually by reaching near normal level on day 30th post-treatment.

The counts of abnormal cells exhibited an initial rise up to day 10th in both the groups, but thereafter they showed a declining trend. In ROE treated irradiated group, almost normal counts of such cells were restored on day 30th; whereas in irradiated group, it could not be ever regained normal. The frequency of such cells observed to be significantly lower from 12 hrs to day 10th post-irradiation autopsy intervals than their corresponding

controls. Total number of abnormal hepatocytes increased by 3.92 folds on day 10th after irradiation but on contrary it decreased by 1.19 times in experimental group than the control.

Figure 2 shows that no significant difference in the hepatic and blood GSH contents was observed between normal and ROE treated animals. However, a statistically significant ($p < 0.001$) decrease in GSH was evident in radiation treated control animals. ROE treated irradiated animals showed a significant increase in GSH content (blood and liver) with respect to control, but the values remained below normal. Administration of ROE when compared with DDW treatment did not alter the lipid peroxidation (LPx). Exposure of animals to gamma radiation increased LPx in Groups III and IV. ROE pretreatment significantly

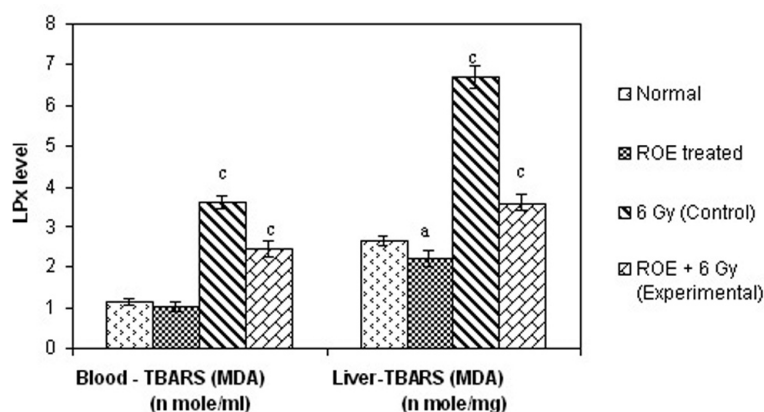


Figure 2A. Lipid peroxidation (LPx) level in Swiss albino mice after exposure to 6 Gy gamma radiation in the presence (Experimental) or absence (Control) of *Rosemarinus officinalis* extract (ROE).

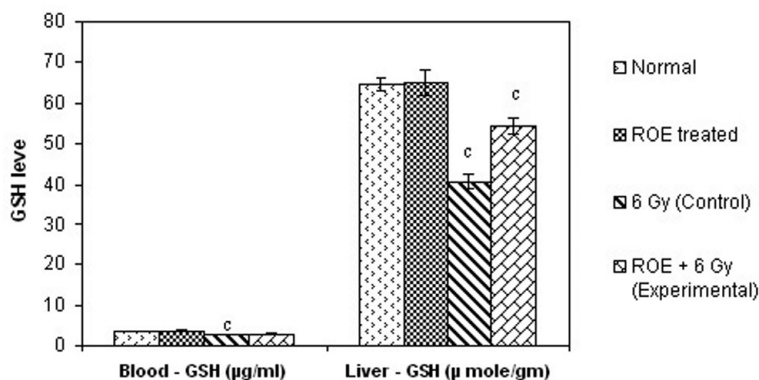


Figure 2B. Glutathione (GSH) level in Swiss albino mice after exposure to 6 Gy gamma radiation in the presence (Experimental) or absence (Control) of *Rosemarinus officinalis* extract (ROE). Significance level between Normal V/s Control, Control V/s Experimental ($a=0.05$, $b=0.01$, $c=0.001$).

reduced LPx induction in the ROE + irradiation group, thereby protecting liver and blood against radiation induced LPx.

DISCUSSION

Irradiation of animals to 6 Gy in the present study resulted in radiation sickness within 3-5 days after exposure. The symptoms included reduction in food and water intake, irritability, weight loss lethargy, diarrhoea and ruffling of hairs. The similar symptoms have been observed in mice after gamma irradiation by others also (8, 26-28). Whole-body irradiation primarily affects rapidly proliferating germinal epithelium, gastro-intestinal epithelium, bone marrow and spleen progenitor cells. While the germinal epithelium does not have a life supporting function for the exposed individual, but the bone marrow, spleen progenitor cells and gastro-intestinal epithelium cells are crucial for the sustenance of life, and any damage to these cells will impair normal physiological host defense processes drastically, causing an adverse impact on survival. Pretreatment of mice with ROE provided protection against radiation-induced sickness and mitigated suffering. Similarly, plants such as *Ocimum sanctum*, *Moringa oleifera*, *Mentha arvensis*, *Emblica officinalis* have been reported to provide protection against sickness induced by radiation (10, 11, 29, 30).

The radiation induced damage in the liver with or without ROE treatment was expressed as the change in the percentage of abnormal and binucleated hepatocytes. The change in the percentage of these hepatocytes is good parameter for indicating the severity of radiation induced damage.

The histopathological observations revealed that the reason for an early increase of the binucleated cells before degeneration is due to the fusion of liver cells. Observations on day 5th post-irradiation exhibit that the radiation exposure caused the death and removal of binucleate cells which results in the depletion of such cells and some of these

even form mononucleate giant cells. The second elevation in the number of binucleated cells in control group (6 Gy radiation) caused during the recovery period may be due to failure of complete telophase separation of a post-mitotic cell or inhibition of cell division by radiation induced G₂ block. These findings confirm the reports of other workers (31-35).

The increase in abnormal and binucleated hepatocytes indicates the severity of the radio-pathology produced by radiation generated free-radicals. Free radicals are regularly formed in normal physiological as well as pathological processes and are destroyed spontaneously due to their unstable nature. The rate of spontaneous destruction is determined by the action of certain enzymatic antioxidants (SOD, catalase and glutathione peroxidase). Therefore, the net effect of free-radical injury depends upon the rate of their elimination.

In the present study, liver of mice exhibits various radio-lesions in the form of destroyed hepatic architecture, crenated nuclei, wider sinusoids, enucleation, cytoplasmic granulation and vacuolization and excessive number of kupffer cells. These nuclear and cytoplasmic changes may be produced due to the lipid peroxidation and destruction of protein, DNA, cytoskeleton and organelles. Free-radicals generated by ionizing radiation, especially the hydroxyl radical (OH), attack polyunsaturated fatty acids (PUFA) in cell membranes to yield highly destructive PUFA radicals (lipid hydroperoxy radicals and lipid hydroperoxides) that damage the cell membranes^(36, 37).

Results from the present study indicate that ROE offers protection against radiation-induced oxidative stress in mice. It helps in maintaining normal configuration of liver after gamma irradiation. There are 6 main polyphenolic compounds present in rosemary extract carnosic acid, carnosol, 12-O-methyl carnosic acid, rosmarinic acid, genkwanin and isoscutellarein 7-O-glucoside⁽¹⁷⁾. Rosmarinic acid (RA) present in *Rosemarinus officinalis* is a naturally occurring non-steroidal anti-inflammatory

agent with novel properties like free-radical scavenging activity. Hydro-alcoholic extracts of some medicinal plants with high amount of hydroxycinnamic derivative content (of which RA present is more than 3-6% of the dry wt.) were tasted and have shown significant antioxidative activities by free radical scavenging effect on DPPH. The antioxidative activity was attributed partly to the high RA content of these plants ⁽³⁸⁾. In another study, with the use of spin trapping methods, rosemary extract was reported to have a scavenging effect on the active oxygen free radicals in stimulated polymorphonuclear leucocyte system ⁽³⁹⁾.

Ionizing radiation induces lipid peroxidation (LPx) which can lead to DNA damage and cell death ⁽⁴⁰⁻⁴²⁾. Therefore, an agent that protects against such damage can provide protection against radiation injury. The administration of ROE before irradiation significantly reduced the amount of LPx compared to the control group. The inhibition of LPx by ROE may also have been responsible for the observed radioprotection.

An increase in the glutathione (GSH) level by ROE may be responsible for the scavenging of radiation-induced free-radicals including LPx and thereby protecting against radiation-induced mortality. It has been reported that LPx starts to increase as soon as the endogenous GSH is exhausted, and the addition of GSH promptly stops further peroxidation ⁽⁴³⁾. The ROE is found effective in altering the sensitivity to radiation possibly by protecting the biological molecules against radiation-induced oxidation of water by decreasing the oxygen tension in the organism.

CONCLUSION

From the present study, it can be concluded that *Rosemarinus officinalis* leaves extract provides a significant protection against radiation-induced sickness, mortality and histopathological alterations. The exact mechanism of action is not known; however, it may scavenge free radicals produced by

radiation and thus inhibit radiation-induced damage to the cellular DNA. Alternatively, it may also increase GSH levels and reduce radiation-induced LPx.

ACKNOWLEDGMENT

Centre for advanced studies (CAS), Department of Zoology, University of Rajasthan, Jaipur is thankfully acknowledged for providing necessary facilities for this study. Authors are also thankful to Prof. D.P. Agrawal (Head), Dr. K.S. Jheetha and Dr. A.A. Chougule (RSO), Department of Radiotherapy, S.M.S. Medical College and Hospital, Jaipur for radiation facility and dosimetry respectively.

REFERENCES

1. Al-Sereiti MR, Abu-Amer KM, Sen P (1999) Pharmacology of rosemary *Rosemarinus officinalis* Linn. and its therapeutic potentials. *Ind. J. Exp. Biol*, **37**: 124-130.
2. Ashoor A (1985) Medication with herbs and plants. Ebn-Sina library for publication and distribution, Cairo, Egypt.
3. Beutler E, Duron O, Kelly BM (1963) Improved method for the determination of blood glutathione. *J Lab Clin Med*, **61**: 582-888.
4. Coyle JT and Puttfarcken P (1993) Oxidative stress glutamate and neurodegenerative disorders. *Science*, **262**: 689-695.
5. Del Bano MJ, Lorente J, Castillo J, et al. (2003) Phenolic diterpenes, flavones and rosmarinic acid distribution during the development of leaves, flowers, stems and roots of *Rosemarinus officinalis* antioxidant activity. *J Agric Food Chem*, **51**: 4247-4253.
6. Dublineau I, Ksab B, Aigueperse J, Gourmelon P, Griffiths NM (1998) In vivo alteration of fluid and electrolyte fluxes in the rot colon by gamma irradiation. *Dig Dis Sci*, **43**: 652-662.
7. El- Gadi A and Bshina SM (1989) Usage of some plants in Libyan folk medicine. Part I Dar Alkutob Alwatanian ; Benghazi
8. Farber JL, Kyle ME, Coleman JB (1990) Mechanism of cell injury by activated oxygen species. *Lab Invest*, **62**: 670-679.
9. Gajawat S and Goyal PK (2000) Inhibition of lead and radiation induced hepatic lesions by vitamin E in Swiss albino mice. *Ind J Gerontol*, **14**: 81-85.
10. Gajawat S and Goyal PK (2003) Influence of-tocopherol (vitamin E) on hepatic lesions induced by gamma irradiation. *J Tissue Res*, **3**: 52-56.
11. Hussain FTK (1979) Medicinal plants, their cultivation and contents. Arabic Book Shop Libya-Tunisia.
12. Del Bano MJ, Castillo J, Garcia OB, Lorente J, Martin-Gil R, Acevado C, Alcaraz, M (2006) Radioprotective-

- antimutagenic effects of rosemary phenolics against chromosomal damage induced in human lymphocytes by gamma-rays. *J Agric Food Chem*, **54**: (6) 2064-8.
13. Jagetia GC and Baliga MS (2002) Influence of the leaf extract of *Mentha arvensis* Linn. (mint) on the survival of mice exposed to different doses of gamma radiation. *Strahlenther Onkol*, **178**: 91-98.
 14. Jagetia GC, Baliga MS, Malagi KJ, Kamath M (2002) The evaluation of radioprotective effect of Triphala (an ayurvedic rejuvenating drug) in the mice exposed to gamma irradiation. *Phytomedicine*, **9**: 99-108.
 15. Jagetia GC, Baliga MS, Venkatesh P (2005) Influence of seed extract of *Syzygium cumini* (Jamun) on mice exposed to different doses of gamma-radiation. *J Radiat Res*, **46**: 59-65.
 16. Jagetia GC, Venkatesh VA, Ponemone, Baliga Manjeshwar S (2004) Fruit extract of *Aegle marmelos* protects mice against radiation-induced lethality. *Integrative Cancer Therapies*, **3**: 323-332.
 17. Jindal A, Sancheti G, Soyal D, Goyal PK (2006) Radioprotective potential of *Rosemarinus officinalis* against lethal effects of radiation, a preliminary study. *J Environ Pathol Toxicol Oncol*, (in press).
 18. Karida R and Hayata I (1999) Effect of estradiol on radiation-induced chromosome aberrations in human lymphocytes. *J Radiat Res*, **40**: 95-100.
 19. Kilic D, Sayan H, Gonal B, Egcham I (2000) The effects of granulocyte macrophage colony stimulating factor and glutathione and lipid peroxidation in a rat model. *Eur J Surg Oncol*, **26**: 701-704.
 20. Kotb DF (1985) Medicinal plants in Libya. Arab Encyclopedia House, Tripoli, 720.
 21. Lamaison JL, Petitjean-Freytet C, Carnat A (1991) Medicinal lamiaceae with antioxidant properties, a potential source of rosmarinic acid. *Pharm Acta Helv*, **66**: 185-188.
 22. Leyko W and Bortosz G (1956) Membrane effects of ionizing radiation and hypothermia. *Int J Radiat Biol Relat Stud Phys Chem Med*, **49**: 743-770.
 23. Loliger J (1989) In: Rancidity in food, Allen J, Hamiltin R (eds). Elsevier Science: New York, 105.
 24. Maharwal J, Samarth RM, Saini MR (2005) Antioxidative effect of Rajgira leaf extract in liver of Swiss albino mice after exposure to different doses of gamma radiation. *Phytother Res*, **19**: 717-720.
 25. Monobe M and Ando K (2002) Drinking beer reduces radiation induced chromosome aberrations in human lymphocytes. *J Radiat Res*, **43**: 237-245.
 26. Moron MS, Depierre JW, Mannervik B (1979) Levels of GSH, GR and GST activities in rat lung and liver. *Biochem Biophys*, **512**: 67-78.
 27. Nemoto K, Horiuchi K, Miyamoto T (1995) Deoxyspergualin is a new radioprotector in mice. *Radiat Res*, **141**: 223-226.
 28. Noda Y, McGeer PL, McGeer EG, Comporti M (1993) Lipid peroxidation, biopathological Significance. *Mol Aspects Med*, **14**: 199-207.
 29. Nunia V and Goyal P K (2004) Prevention of gamma radiation induced anaemia in mice by diltiazem. *Radiat Res*, **45**: 11-17.
 30. Ohkhawa A, Oshishi N, Yogi K (1979) Assay for lipid peroxidation in animal tissue by thiobarbituric acid reaction. *Anal Biochem*, **95**: 351-358.
 31. Raleigh JA, Kremers W, Gaboury B (1977) Dose rate and oxygen effects in models of lipid membranes linoenic acid. *Int J Radiat Biol Relat Stud Phys Chem Med*, **31**: 203-213.
 32. Rao AV, Devi PU, Kamath R (2001) *In vivo* radioprotective effect of *Moringa oleifera* leaves. *Indian J Exp Biol*, **39**: 858-863.
 33. Sancheti G and Goyal PK (2006) Effect of *Roesmarinus officinalis* in modulating 7, 12-Dimethylbenz (a) anthracene induced skin tumorigenesis in mice. *Phytother Res*, **20**: 981-986.
 34. Schuler P (1990) Natural antioxidants exploited commercially. In: *food antioxidants*; Hudson BJF (ed). Elsevier Applied science: London, chapter 4.
 35. Sharma A and Goyal PK (2004) Influence of *Emblca officinalis* on hepatic lesions induced by gamma irradiation in Swiss albino mice. *Radiat Protect and Environ*, **27**: 82-87.
 36. Sharma S and Kumar A (1997) Histopathological lesions caused by β -irradiation in liver of Swiss albino mice. *Adv Bio*, **16**: 49-56.
 37. Shimoi K, Masuda S, Shan B, Furugori M, Kinane N (1996) Radioprotective effect of antioxidative plant flavonoids in mice. *Mutat Res*, **350**: 153-161.
 38. Singh I, Sharma A, Nunia V and Goyal PK (2005) Radio protection of Swiss albino mice by *Emblca officinalis*. *Phytother Res*, **19**: 444-446.
 39. Sugahara T, Tanaka Y, Nagata N, Kano E (1970) Radiation protection by MPG. Proceedings of International Symposium on Thiola, Osaka, Japan. 267.
 40. Uma Devi P, Ganasoundari A, Rao BSS, Srinivasan KK (1999) *In Vivo* radioprotection by *Ocimum flavonoids*, survival of mice. *Radiat Res*, **151**: 74-78.
 41. Uma Devi P, Ganasoundari A (1995) Radioprotective effect of leaf extract of Indian medicinal plant *Ocimum sanctum*. *Indian J Exp Biol*, **33**: 205-209.
 42. Yuhas JM, Spellman JM, Cullo F (1980) The role of WR-2721 in radiotherapy and/or chemotherapy. *Cancer Clin Trials*, **3**: 221.
 43. Zhao BL, Li XJ, He RG, Ching SJ, Xin WJ (1989) *Cell Biophys*, **14**: 175.