

Protective role of Terminalia against γ -rays induced cardiotoxicity in rats

A.A. Elkady*, R.M. Ebrahim, S.S. Tawfik

Health Radiation Research Department, National Centre for Radiation Research and Technology (NCRRT),
Egyptian Atomic Energy Authority, Nasr City, Cairo, Egypt

ABSTRACT

Background: Gamma-rays-induced cellular damages in the vital organs of rats. The study investigates the protective impacts of Terminalia (*T. arjuna*) against γ -rays induced cardiac injuries in rats. **Materials and Methods:** Dose A dose of 400 mg/kg body weight of *T. arjuna* was administered to male rats via gastric intubation for 30 days before whole body γ -irradiation (8 Gy). **Results:** The animals exposed to γ -rays showed a significant rise in levels of lipid-peroxidation (MDA), cardiac injury markers; Aspartate transaminase (AST) and lactate dehydrogenase (LDH), inflammatory markers; tumor necrosis factor- α (TNF- α) and interleukin-6 (IL-6), and finally, reduced oxidative enzyme markers; superoxide dismutase (SOD) and glutathione peroxidase (GPx) as compared to control group. The histopathological sections from irradiated rat group showed myocardium necrosis, loss of striations in myofibrils and leucocytic infiltration. Pre-treatment with *T. arjuna* reduced the altered levels of these markers, which was further confirmed by histopathological observations. A tendency towards normal architectures of the myocardium was distinguished and a decrease in the degree of damages and inflammations in the myocytes was demonstrated. **Conclusion:** *T. arjuna* modifies antioxidants and inflammatory markers in rat heart and also prevents the myocardium from γ -rays-induced myocardial damages and should have prophylactic value in the prevention of heart toxicity.

Keywords: Terminalia, radioprotector, γ -rays, heart, rats.

► Original article

***Corresponding author:**

Dr. A.A. Elkady

E-mail:

elkadyah13@gmail.com

Revised: January 2019

Accepted: February 2019

Int. J. Radiat. Res., October 2019;
17(4): 643-649

DOI: 10.18869/acadpub.ijrr.17.3.643

INTRODUCTION

Recently, cardiovascular disease (CVD) is estimated to be the main cause of death and loss of disability-adjusted life years worldwide (1,2). The clinical importance of radiation-induced heart toxicity, especially in post-operative mediastinal radiation therapy, has been recognized (3,4). These CVD problems include congestive heart failure, constrictive pericarditis, cardiomyopathy, coronary vascular disease, valvar heart disease, and sudden death (5).

Oxidative stress is well known to be involved in pathophysiology of several complications. Naturally, reactive oxygen species (ROS) are produced within cells to accelerate biochemical

processes nevertheless, when ROS are produced in excess, cellular antioxidant defense mechanisms become overwhelmed, ending in a cascade of ROS generation that finally results in oxidative stress (6,7) as ROS is the major mediators for radiation-induced damages (8). Currently, there is an urgent need for effective drug discovery for the treatment of CVD or controlling the myocardial damages (9). A treatment combining radiation with an antioxidant from remedial herbs might deliver a strategy for hindering radiation injury to normal tissues (10). One such medicinal plant is dried powder of aqueous extract of *T. arjuna* (Family: Combretaceae), which is well known as a cardio stimulant in the ancient Indian Medicine; Ayurveda system of medicine (11). Whether *T.*

arjuna has a cardio protective action against oxidative stress remains unclear ⁽¹²⁾.

T. arjuna is one of the most established and valued herb in the remedial traditional system of prescription for the treatment of various serious disorders as an antioxidant, anti-inflammatory, anti-carcinogenic, anti-mutagenic and a gastro protector ⁽¹³⁾. Safety, low side effects, and popularity of natural products have made them interesting for the researchers as an alternative source of curative agents ⁽¹⁴⁾. No study has yet addressed the cardio protective effect of *T. arjuna* against γ -rays-induced myocardial ailments. The current work is intended to explore the possible protective effect of *T. arjuna* against γ -rays-induced cardiac damages, biochemical and histopathological alterations.

MATERIALS AND METHODS

Animals

Adult male Swiss albino rats (110-120g), n=40 were obtained from the Egyptian Organization for Biological Product and Vaccines, Giza, Egypt. The animals were given standard diet and water *ad libitum*. The animals maintained under standard conditions of humidity (50-60%), temperature (20-24°C), and 12-h light-dark cycle, and handled gently and as little as possible to minimize noises, vibrations and stress.

The study was approved by the National Centre for Radiation Research and Technology, Research Ethics Committee, REC-NCRRT. Serial number of protocol: 17A /18, 16/7/2018. Animals were deprived of food, but not water, overnight before samples collection.

Radiation processing

It was performed by using gamma cell-40 (Cesium-137) located at NCRRT, Cairo, Egypt. Animals were irradiated with a single dose of 8 Gy γ -rays, delivered at a dose rate of 0.42 Gy/min at the time of experimentation. Animals were not anesthetized before irradiation.

Chemicals

Dried powder of aqueous extract of

T. arjuna bark was purchased from Natural Remedies Pvt. Ltd., Bangalore, India.

Experimental design

Animal grouping

Forty rats were divided into four groups (n=10). Control group, rats were administered normal saline (1ml/rat) orally by gastric tube for 30 days as a vehicle. *T. arjuna* group, each rat received 400 mg/kg body weight once daily, orally by gastric tube for 30 days according to Shukla *et al.* ⁽¹⁵⁾. Irradiated group; animals received the vehicle with the same dose and time interval; then subjected to a single dose of the whole body γ -rays (8 Gy), and *T. arjuna* & irradiated group, each rat received *T. arjuna* with the same dose and time interval, then one hour later after the last dose, rats were exposed to a single dose of the whole body γ -rays (8 Gy). The animals were decapitated 24 hours post end of the experiment after an overnight fast.

Biochemical analysis

Blood and heart samples were collected from rats from different groups under standard laboratory conditions. Colorimetric kits (Abcam, UK) were used to measure (AST and LDH) in the cardiac homogenates according to the manufacturer's instructions. Estimation of serum TNF- α and IL-6 was performed using ELISA method (BioSource International, Camarillo, CA, USA) according to the manufacturer's instructions. Assessment of malondialdehyde (MDA) level, and the relative enzyme activity of SOD and GPx in the cardiac homogenates were measured using commercial kits (Zellbio GmbH, Germany) according to the manufacturer's instructions. The absorbance was read at 420nm, 535nm and 412nm, respectively.

Histopathological finding

The cardiac sections were fixed in 10% neutral formalin solution. After 24 hours, tissues were dehydrated through a series of graded alcohol, embedded in paraffin, and cut into 4-micron sections and stained with hematoxylin and eosin (H&E) according to Bancroft *et al.* ⁽¹⁶⁾ and examined with a light microscope (Olympus,

Int. J. Radiat. Res., Vol. 17 No. 4, October 2019

Japan). All grossly abnormal suspicious areas were examined; if no gross abnormalities seen, four random sections were examined. All observes were performed on blinded coded slides.

Statistical analysis

Data were analyzed using one way analysis of variance (ANOVA) followed by least significant difference (LSD) post hoc test. The results obtained were expressed by mean \pm standard deviation (SD). Differences were considered significant at $p \leq 0.05$ (Snecdecor and Cochran, 1989) (17).

RESULTS

As presented in table 1-3, animal group treated with *T. arjuna* showed no significant changes in the levels among all estimated biochemical parameters of the current study. In markers of cardiac tissue damage, there was a significant rise in MDA level and in AST and LDH activities in irradiated rat group as compared to controls. Pre-treatment with *T. arjuna* at a dose of 400 mg / kg exerted significant reduction on these markers (MDA, AST and LDH), when compared to the irradiated group at a dose of 8Gy γ -rays (table 1).

In table 2, markers of inflammation, TNF- α and IL-6 in serum, were elevated following γ -rays-irradiation experiment as compared to

control rat group. Pre-treatment with *T. arjuna* produced significant reduction in their levels when compared to the irradiated group ($p \leq 0.05$).

Table 3 showed a significant reduction in anti-oxidant cardiac marker enzymes; SOD and GPx activity within cardiac tissue in irradiated group as compared to control values. Pre-treatment with *T. arjuna* developed a significant rise in their levels when compared to the irradiated group (table 3).

Histopathological investigation

The control rat group illustrated the structure of the normal heart tissue with characteristic myocardial structure (figure 1). In *T. arjuna* group, the cardiac muscle showed normal structure. In γ -rays-irradiated group, fibrinous necrosis in coronary blood vessels was showed characterized by circumferential bright pink area of necrosis with deposition of protein in the blood vessels endothelium (figure 2A). The myocardial muscles were coagulative necrotic myocytes and infiltrated with leucocytes, edema, associated with loss of striation and disappearance of nuclei, intercalated disks and removal of necrotic myocytes by phagocytosis (figure 2B,C). On the other hand, most cases in *T. arjuna* & γ -rays group, myocardial muscle showed considerably preserved architecture without necrosis, with or without edema, dilated blood vessels and slight hemorrhage (figure 3A,B).

Table 1. The markers of cardiac damage levels of MDA, AST and LDH in heart of different animal groups.

Groups	Control	<i>T. arjuna</i>	γ -rays	<i>T. arjuna</i> & γ -rays
MDA (nmol/ g tissue)	41.11 \pm 2.38	40.14 \pm 2.12	64.15 \pm 4.51 ^a	45.33 \pm 3.24 ^b
AST (U/ g tissue)	32.45 \pm 2.62	31.88 \pm 2.39	70.54 \pm 6.15 ^a	41.17 \pm 3.47 ^b
LDH (U/ g tissue)	62.77 \pm 5.16	61.97 \pm 5.12	150.35 \pm 8.36 ^a	93.23 \pm 6.45 ^b

MDA: malondialdehyde; AST: aspartate transaminase; LDH: lactate dehydrogenase. All values are expressed as mean \pm SD. aSignificant ($p \leq 0.05$) when compared with the control group. bSignificant ($p \leq 0.05$) when compared with the γ -rays group.

Table 2. The inflammatory marker levels of TNF- α and IL-6 in serum of different animal groups.

Groups	Control	<i>T. arjuna</i>	γ -rays	<i>T. arjuna</i> & γ -rays
TNF- α (pg/ mL)	13.84 \pm 2.42	13.52 \pm 2.71	39.16 \pm 5.19 ^a	19.17 \pm 3.05 ^b
IL-16 (pg/ mL)	91.23 \pm 7.32	88.92 \pm 6.54	311.25 \pm 12.16 ^a	178.13 \pm 9.56 ^b

TNF- α : tumor necrosis factor- α ; IL-16: interleukin-6. All values are expressed as mean + SD. aSignificant ($p \leq 0.05$) when compared with the control group. bSignificant ($p \leq 0.05$) when compared with the γ -rays group.

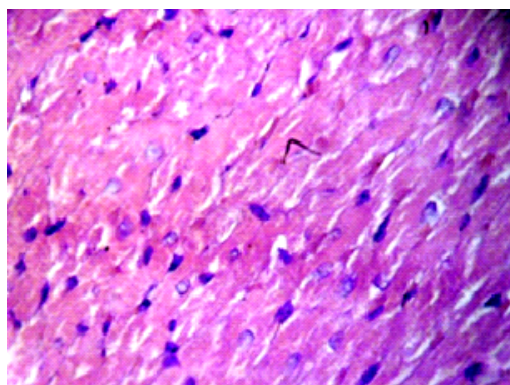


Figure 1. Heart of control rat showing normal myocytes (H&E 400x).

Table 3. The anti-oxidant cardiac marker enzymes levels of SOD and GSHPx in heart of different animal groups.

Groups	Control	<i>T. arjuna</i>	γ -rays	<i>T. arjuna</i> & γ -rays
SOD ($\mu\text{g/g}$ tissue)	72.24 \pm 4.13	70.34 \pm 4.18	35.19 \pm 3.26 ^a	66.45 \pm 5.01 ^b
GPX (nmol/ g tissue)	29.47 \pm 3.17	30.22 \pm 3.15	14.16 \pm 2.07 ^a	23.14 \pm 3.11 ^b

SOD: superoxide dismutase; GPx: glutathione peroxidase. All values are expressed as mean + SD. ^aSignificant ($p \leq 0.05$) when compared with the control group. ^bSignificant ($p \leq 0.05$) when compared with the γ -rays group.

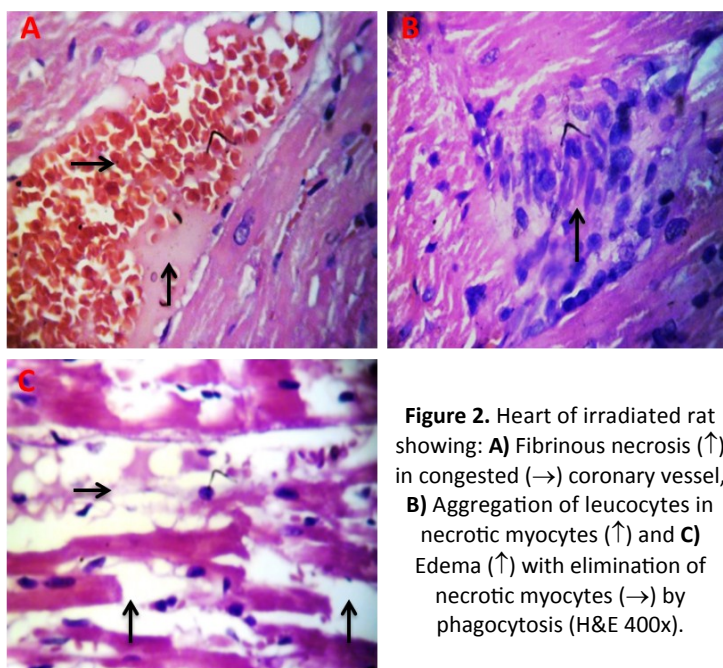


Figure 2. Heart of irradiated rat showing: **A)** Fibrinous necrosis (\uparrow) in congested (\rightarrow) coronary vessel, **B)** Aggregation of leucocytes in necrotic myocytes (\uparrow) and **C)** Edema (\uparrow) with elimination of necrotic myocytes (\rightarrow) by phagocytosis (H&E 400x).

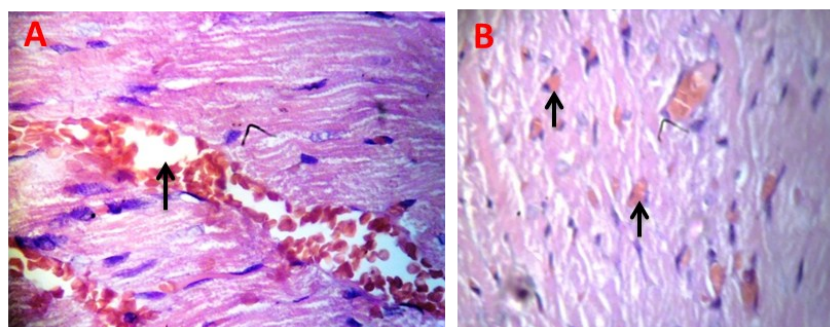


Figure 3. Heart of *T. arjuna* & γ -rays group showing: **A)** Dilated coronary vessels (\uparrow) and **B)** normal myocytes with slight hemorrhage (\uparrow) (H&E 400x).

DISCUSSION

Animals are frequently exposed to low levels of naturally occurring ionizing-radiation. Cells have defense mechanisms against it but cannot survive when exposed to a high dose of radiation which is beyond the ability of the cells to handle thus protection of cells from these ionizing-radiation is important for animals' health⁽¹⁸⁾.

Triphala specie contains three breeds; *Terminalia chebula*, *Terminalia bellirica* and *Emblica officinalis* can provide a novel radio-protector for practical applications⁽¹⁹⁾. Recently, the cardio protective potential of *T. arjuna* was evaluated against surgically induced oxidative stress through left anterior descending coronary artery ligation in dogs⁽²⁰⁾ thus in the present work we attempt to verify the protecting effect of *T. arjuna* in γ -rays-induced cardiac damages, biochemical and histopathological alterations in the rat model.

The rise in lipid peroxidation indicates enhanced oxidative stress. γ -rays exposure raised the cardiac MDA level significantly, as compared to control rat group. Recently, the severe myocardial damages in the rats exposed to γ -rays can be attributed to post-oxidative damage generated by lipid peroxides⁽²¹⁾. This present observation is in accordance with the previous findings of increased lipid peroxidation due to γ -rays challenge, and this was improved by pre-treatment of *T. arjuna*.

It was currently reported that medicinal plants can stimulate the synthesis of cellular antioxidants⁽¹⁰⁾. The cardiac damage markets activities of AST and LDH were elevated in irradiated rats. A significant rise in the levels of these diagnostic markers in the heart following γ -rays exposure is an indication of the severity of the necrotic damage of the myocardium membranes⁽²²⁾. Accordingly, a drop in these cardiac damage markers indicates a decrease in the degree of myocardium injury in rat group pre-treated with *T. arjuna*. In order to evaluate the impact of *T. arjuna* intake on inflammation. The serum levels of TNF- α and IL-6 were measured, which are established inflammatory markers released after myocardial damage⁽²³⁾. A

significant rise in the levels of inflammatory markers in the heart following γ -rays exposure was detected. The novel finding of this study, *T. arjuna* reduces serum indices of oxidative stress, cardiac damages and inflammation. Consumption of *T. arjuna*; 400mg/kg per day for 30 days moderated the raised levels of these inflammatory markers in isoproterenol influenced myocardial damage in rats⁽¹⁵⁾.

There was a significant reduction in cardiac marker enzymes SOD and GPx activities as compared to control rats. *T. arjuna* exerted significant effects on these markers, when compared to the irradiated group. Chandra *et al.*⁽²⁴⁾ reported that stress and emotion are associated with several illnesses from complications to heart diseases. Also, they found that *T. arjuna* revealed protecting success against picrotoxin-provoked anxiety in mice by modulation of SOD and GPx antioxidant enzymes.

The biochemical aspects of the rat model of myocardial injury induced by γ -rays in rats, was clearly obvious by the histopathological findings which represented by fibrinous necrosis in coronary vessels, necrotic myocytes and infiltrated with leucocytes, edema, associated with loss of striation and disappearance of nuclei, intercalated disks and in few cases showed removal of necrotic myocytes by phagocytosis (figure 2A, B and C). Such results are in agreement with the previous findings results observed by Azab *et al.*^(25,26). In the present study, *T. arjunac* prevented myocardial necrosis and showed slight edema, dilated blood vessels and hemorrhage in *T. arjuna* & γ -rays group (figure 3A and B). *T. arjunac* has significantly protected the myocardium from the oxidative stress damages via reduction of lipid peroxidation and enhancement of endogenous antioxidant enzymes⁽²⁰⁾. It was postulated that *T. arjuna* used as a cardio tonic in heart failure, ischemic, cardiomyopathy, atherosclerosis and myocardium necrosis⁽¹³⁾. Also, *T. arjuna* mitigated cardiac illnesses, abbreviated oxidative stress, inflammatory cytokine and myocardium histological changes in diabetic rats⁽²⁷⁾. Moreover, *T. arjuna* significantly prevented the isoprenaline-induced increase in oxidative

stress, decline in endogenous antioxidant level and strengthening in myocardium fibrosis (28).

T. arjuna potency enhanced the cardiac restoration via several mechanisms; controlling hemodynamic and endothelial function through its antioxidant, free radical scavenging, and anti-inflammatory property.

CONCLUSION

The present study shows that the biochemical and histopathological alterations produced by γ -rays was attenuated by pre-treatment with *T. arjuna*. This could be due to its anti-oxidative effect against γ -rays-induced oxidative stress. The results of this study imply that pre-treatment with *T. arjuna* is effective in reducing the extent of myocardial damages by decreasing lipid peroxidation, improving antioxidant power, and hence providing cardio protection.

ACKNOWLEDGEMENTS

We are thankful to our colleagues, Health Radiation Research Department for providing laboratory conveniences, and members of the National Center for Radiation Research and Technology (NCRRT), Egyptian Atomic Energy Authority for providing the necessary irradiation facilities. This work was done in the NCRRT, Egypt.

Funding

This research received no specific grant from any funding agency in the public, commercial, or not-for-profit sectors.

Conflicts of interest: Declared none.

REFERENCES

1. Islam MZ, Islam MN, Bhowmik TK, Saha B, Hossain MS, Ahmed H, Ali MS, Shakil SS (2018) Paul PK. Relationship between triglyceride and HDL-C ratio with acute coronary syndrome. *Mymensingh Med J*, **27(2)**: 289-93.
2. Jafar TH, Tan NC, Allen JC, Finkelstein EA, Goh P, Moey P, Quah JHM, Hwang SW, Bahadin J, Thiagarajah AG, Chan J, Kang G, Koong A (2018) Management of hypertension and multiple risk factors to enhance cardiovascular health in Singapore: The SingHypertension cluster randomized trial. *Trials*, **19(1)**: 180.
3. Cuomo JR, Sharma GK, Conger PD, Weintraub NL (2016) Novel concepts in radiation-induced cardiovascular disease. *World J Cardiol*, **8(9)**: 504-19.
4. Soliman AF, Anees LM, Ibrahim DM (2018) Cardioprotective effect of zingerone against oxidative stress, inflammation, and apoptosis induced by cisplatin or gamma radiation in rats. *Naunyn Schmiedebergs Arch Pharmacol*, May 7. doi: 10.1007/s00210-018-1506-4.
5. Aronson D and Brenner B (2018) Arterial thrombosis and cancer. *Thromb Res*, **164 Suppl 1**: S23-S28.
6. Jain V, Dutta R, Maheshwari DT, Meena DK, Misra K and Yogendra Kumar MS (2018) *Valeriana wallichii* extract inhibits tert-BOOH induced oxidative damage and cytotoxicity. *Front Biosci (Elite Ed)*, **10**: 469-80.
7. Mishra K, Ojha H, Kallepalli S, Alok A, Kumar Chaudhury N (2014) Protective effect of ferulic acid on ionizing radiation induced damage in bovine serum albumin. *Int J Radiat Res*, **12(2)**: 113-21.
8. Castillo H, Li X, Schilkey F, Smith GB (2018) Transcriptome analysis reveals a stress response of *Shewanella oneidensis* deprived of background levels of ionizing radiation. *PLoS One*, **13(5)**: e0196472.
9. Althaf Hussain S, Kareem MA, Rasool SN, Al Omar SY, Saleh A, Al-Fwuairees MA, Daddam JR, Devi KL (2018) Trace Element determination and cardioprotection of Terminalia pallida fruit ethanolic extract in isoproterenol induced myocardial infarcted rats by ICP-MS. *Biol Trace Elem Res*, **181(1)**: 112-21.
10. Yahyapour R, Motevaseli E, Rezaeyan A, Abdollahi H, Farhood B, Cheki M, Rezapoor S, Shabeeb D, Musa AE, Najafi M, Villa V (2018) Reduction-oxidation (redox) system in radiation-induced normal tissue injury: molecular mechanisms and implications in radiation therapeutics. *Clin Transl Oncol*, **20(8)**: 975-88.
11. Rather RA, Malik VS, Trikha D, Bhat O, Dhawan V (2016) Aqueous Terminalia arjuna extract modulates expression of key atherosclerosis-related proteins in a hypercholesterolemic rabbit: A proteomic-based study. *Proteomics Clin Appl*, **10**: 750-59.
12. Bishop S and Liu SJ (2017) Cardioprotective action of the aqueous extract of Terminalia arjuna bark against toxicity induced by doxorubicin. *Phytomedicine*, **36**: 210-16.
13. Amalraj A and Gopi S (2016) Medicinal properties of Terminalia arjuna (Roxb.) Wight & Arn.: A review. *J Tradit Complement Med*, **7(1)**: 65-78.
14. Afshari AR, Sadeghnia HR, Mollazadeh H (2016) A review on potential mechanisms of terminalia chebula in Alzheimer's disease. *Adv Pharmacol Sci*, **2016**: 8964849.
15. Shukla SK, Sharma SB, Singh UR, Ahmad S, Dwivedi S (2015a) Terminalia arjuna (Roxb.) Wight & Arn. augments

- cardioprotection via antioxidant and antiapoptotic cascade in isoproterenol induced cardiotoxicity in rats. *Indian J Exp Biol*, **53(12)**: 810-8.
16. Bancroft D, Stevens A, Turner R (1996) Theory and practice of histological technique, 4th ed. Edinburgh; Churchill Livingstone, pp: 47-67.
 17. Snedecor GW and Cochran WG (1989) Statistical Methods, 8th ed. Wiley-Blackwell, p: 503.
 18. Takauji Y, Miki K, Mita J, Hossain MN, Yamauchi M, Kioi M, Ayusawa D, Fujii M (2016) Triphala, a formulation of traditional Ayurvedic medicine, shows protective effect against X-radiation in HeLa cells. *J Biosci*, **41(4)**: 569-75.
 19. Sandhya T, Lathika KM, Pandey BN, Bhilwade HN, Chaubey RC, Priyadarsini KI, Mishra KP (2006) Protection against radiation oxidative damage in mice by Triphala. *Mutat Res*, **609(1)**: 17-25.
 20. Afsheen N, Khalil-Ur-Rehman, Jahan N, Ijaz M, Manzoor A, Khan KM Hina S (2018) Cardioprotective and Metabolomic Profiling of Selected Medicinal Plants against Oxidative Stress. *Oxid Med Cell Longev*, **2018**: 9819360.
 21. Ashry OM, Hussein EM, Abd El-Azime AS (2017) Restorative role of persimmon leaf (*Diospyros kaki*) to gamma irradiation-induced oxidative stress and tissue injury in rats. *Int J Radiat Biol*, **93(3)**: 324-29.
 22. Shukla SK, Sharma SB, Singh UR (2015b) Pre-treatment with α -tocopherol and Terminalia arjuna ameliorates, pro-inflammatory cytokines, cardiac and apoptotic markers in myocardial infarcted rats. *Redox Rep*, **20(2)**: 49-59.
 23. Yang Z, Cheng F, Yan G, Xiong L, Liu H (2018) Propofol protects against endotoxin-induced myocardial injury by inhibiting NF- κ B-mediated inflammation. *Exp Ther Med*, **15(2)**: 2032-36.
 24. Chandra Sekhar Y, Phani Kumar G, Anilakumar KR (2017) Terminalia arjuna bark extract attenuates picrotoxin-induced behavioral changes by activation of serotonergic, dopaminergic, GABAergic and antioxidant systems. *Chin J Nat Med*, **15(8)**: 584-96.
 25. Azab KS, Bashandy M, Salem M, Ahmed O, Tawfik Z, Helal H (2011) Royal jelly modulates oxidative stress and tissue injury in gamma irradiated male Wister Albino rats. *N Am J Med Sci*, **3(6)**: 268-76.
 26. Mohamed ET, Elkady AA, El Kiki SM (2016) Protective Effect of *Symplocos racemosa* Roxb against gamma radiation induced cardiotoxicity in male albino rats. *Pakistan J Zool*, **48(6)**: 1831-37.
 27. Khaliq F, Parveen A, Singh S, Gondal R, Hussain ME, Fahim M (2013) Improvement in myocardial function by Terminalia arjuna in streptozotocin-induced diabetic rats: possible mechanisms. *J Cardiovasc Pharmacol Ther*, **18**: 481-89.
 28. Kumar S, Enjamoori R, Jaiswal A, Ray R, Seth S, Maulik SK (2009) Catecholamine-induced myocardial fibrosis and oxidative stress is attenuated by Terminalia arjuna (Roxb.). *J Pharm Pharmacol*, **61(11)**: 1529-36.

