

# Comparison of 3D conformal and intensity modulated radiotherapy in early stage oral tongue cancer: dosimetric and radiobiological evaluation

A. Shanei<sup>1</sup>, I. Abedi<sup>1</sup>, P. Saadatmand<sup>1\*</sup>, A.R. Amouheidari<sup>2</sup>,  
H. Akbari-Zadeh<sup>1\*</sup>

<sup>1</sup>Department of Medical Physics, School of Medicine, Isfahan University of Medical Sciences, Isfahan, Iran

<sup>2</sup>Radiation Oncology Department, Isfahan Milad General Hospital, Isfahan, Iran.

## ABSTRACT

**Background:** The aim of this study was to compare the dosimetric and radiobiological efficiency of various intensity modulated radiotherapy (IMRT) techniques with 3D conventional radiotherapy (3D-CRT) technique in the treatment of early stage oral tongue cancer. **Materials and Methods:** This study was performed on 38 CT images of patients who were planned with 3D-CRT and three sets of IMRT treatment plans including five, seven and nine fields with prescribed dose of 66 Gy to planning target volume. The dose volume histograms, homogeneity index (HI), conformity index (CI) and normal tissue complication probability (NTCP) of main organs at risk were derived using Prowess Panther treatment planning system. **Results:** The results of this study indicated an increase in HI and CI for IMRT plans compared to 3D-CRT. Furthermore, IMRT techniques led to a statistically significant reduction in received dose by mandible (up to 10.10 Gy) and thyroid (up to 13.59 Gy) compared to the conventional technique used; whereas, it led to a statistically significant increase in received dose by parotid glands (up to 7.62 Gy) and brain stem (up to 9.87 Gy). In addition, IMRT increased (up to 12.79%) the probability of occurrence of parotid xerostomia and decreased mandibular complications (up to 7.76%) in comparison to conventional treatment. **Conclusions:** It can be concluded that IMRT can be more successful in improving oral tongue cancer treatment with more conformity and homogeneity. However, IMRT may not be required for all patients with oral tongue cancer at early stage of the disease.

**Keywords:** Oral cavity cancer, oral tongue cancer, 3D conformal radiation therapy, intensity modulated radiotherapy.

## ► Original article

### \*Corresponding authors:

Hadi Akbari-Zadeh,

Pegah Saadatmand,

Fax: + 98 313 668 8597

E-mail:

[hadi.akbari.zadeh@gmail.com](mailto:hadi.akbari.zadeh@gmail.com),

[saadatmand.pegah@yahoo.com](mailto:saadatmand.pegah@yahoo.com)

Revised: July 2019

Accepted: August 2019

Int. J. Radiat. Res., January 2020;  
18(1): 33-42

DOI: 10.18869/acadpub.ijrr.18.1.33

## INTRODUCTION

Oral cavity cancer, of which more than 80% of patients become aware at the age of over 50, is one of the most prevalent cancers in the world <sup>(1)</sup> and the average age for detection of this cancer is 62 years <sup>(2)</sup>. Tongue cancer is one of the most common types of cancers in the oral cavity, in which 32% of all patients with oral cavity and oropharynx cancer are included. The estimated incidence rate of tongue cancer in the United States was 17,060 cases in 2019, which resulted

in 3,020 deaths <sup>(3)</sup>.

The main treatment modalities for head and neck cancers are surgery and radiation therapy <sup>(4-6)</sup>. In the early stages of this tumor, one of these modalities can be sufficient for successful treatment, however, combined treatments are commonly used for advanced stages <sup>(4)</sup>. Although local recurrence is an important factor in the failure of the surgical procedure to treat this kind of cancer <sup>(7,8)</sup>, studies have revealed that post-operative radiation therapy shows better local control and overall patient's survival in the

treatment of this type of cancer <sup>(4)</sup>.

Radiotherapy techniques have been tremendously developed in recent decades, and introducing new radiation therapy techniques has been a major step in increasing the efficacy of this therapeutic modality <sup>(9)</sup>. Intensity modulated radiation therapy (IMRT) is one of the therapeutic methods in cancer with a critical role in radiotherapy treatment. Flexibilities in the number of radiation fields and their intensity in IMRT has led to a better dose distribution compared to conventional radiotherapy techniques. Better conformity to the tumor shape causes less damage to the organ at risk (OAR) <sup>(8,10)</sup>. This conformity can improve the quality of patient's life treated with this method compared to the conventional radiotherapy by increasing the efficacy of treatment <sup>(11)</sup>.

Some studies have shown the success of IMRT treatment compared to conventional radiation therapy in patients with oral cavity <sup>(11,12)</sup>. Vergeer *et al.* <sup>(13)</sup> showed superiority of IMRT modality in patients with head and neck cancers, however, Chen *et al.* <sup>(8)</sup> did not observe any significant difference in acute toxicity between IMRT and conventional radiation therapy techniques in oral cavity cancer, and some other studies reported that IMRT may not be required for patients with oral cavity cancer at the early stages of the disease (T1-T2 / N0) <sup>(14)</sup>. Ghosh *et al.* <sup>(15)</sup> believe that the first institution which worked on conventional radiotherapy and IMRT on head and neck cancer was PARSPORT, and they observe that IMRT can reduce xerostomia. However, they concluded that this treatment can not cause any difference in locoregional control and other toxicities after one year follow-up. In addition, there are studies mentioning that IMRT increases the dose of organs such as brain stems in patients with head and neck cancer <sup>(16)</sup>.

While some studies have been conducted recently to evaluate IMRT outcomes in patients with oral cavity cancer, there are still some concerns on the overall superiority of this method over conventional radiotherapy methods. Some of these limitations are related to increased risk of secondary cancers as well as increased cost and time (about three times) for IMRT compared to conventional radiation

therapy <sup>(17,18)</sup>. One of the most important questions with regard to the stated issues is whether IMRT treatment can provide benefits in terms of cost and time compared to 3D conventional radiotherapy (3D-CRT) treatment in oral cavity cancers.

Although IMRT shows promise as a radiation procedure aimed at increasing therapeutic gain, in the head and neck area, it still presents a number of challenges and avenues that have yet to be fully explored. Furthermore, overall superiority of each radiotherapy technique must be expressed based on evaluating both dosimetric and radiobiological outcomes of all the OARs in the vicinity of cancer site because in some competing plans, a similar mean dose, maximum dose, or minimum dose may have significantly different radiobiological outcomes <sup>(19)</sup>. Therefore, it seems that comprehensive comparison of two modalities (IMRT and 3D-CRT) of radiotherapy should be made based on both dosimetric and radiobiological evaluation; and to the best of our knowledge, no specific study has been founded to compare these two modalities (IMRT and 3D-CRT) on oral tongue cancer as the most important type of oral cavity cancer. Hence, the aim of this study was to evaluate the clinical differences between IMRT techniques and 3D-CRT by comparing received dose and radiobiological parameters of all OARs in the vicinity of oral tongue cancer.

## MATERIALS AND METHODS

### Patient selection

Thirty-eight patients (age range: 23 to 59 years) with oral tongue cancer (T1-T2/N0 tumors, according to the American Joint Committee on cancer staging classification) admitted to Milad Hospital, Isfahan, Iran between October 2015 and January 2019 were enrolled to this study. Ethical code of this study, provided by the ethics committee of Isfahan University of Medical Sciences, Isfahan, on October 2018, was IR.MUI.MED.REC.1397.030.

### Treatment method

#### Treatment simulation

The patients were immobilized using head

and neck thermoplastic mask in the supine position and underwent CT (Siemens Somatom Sensation 64 slice, Germany) imaging and IMRT simulation process. Then, the CT images were electronically transferred to the treatment planning system.

### Target volume contouring

Organs' contouring was performed according to the International Commission on Radiation Units and Measurements (ICRU) report 50. The CTV<sub>1</sub> was included by adding a 1 to 1.5 cm margin to the surgical tumor bed, the lymph nodes were involved with extracapsular extension and the CTV<sub>2</sub> was added to both side lymph nodes with low risk (retro, parapharyngeal, cervical nodes level Ib-V). In order to account for the patient's position and motion adjustment errors, the Planning Target Volume (PTV) was defined as the CTV and a circumferential margin of 0.3-0.5 cm (depending on the vicinity to the organ at risk such as the spinal cord or brain stem). Furthermore, the spinal cord, brain stem, parotid glands, chiasm, eyes, optic nerves, mandibular bones, larynx, lens, TM joint, pituitary gland, cochlea, submandibular gland and thyroid gland were considered critical organs.

### 3D conventional radiation therapy (3D-CRT)

Forward treatment planning was performed on patient CT images using the Prowess Panther (Version 5.5, Prowess Inc., Concord, CA, USA) treatment planning system (TPS). All patients received 66 Gy at 2 Gy/fraction with a SIMENS

accelerator (SIMENS-ARTISTE, 5918, Germany) and 6 MV photon beam. The patients were treated with two bilateral opposing fields for the primary tumor site and an anterior lower neck field to cover the neck and supraclavicular lymph nodes. When the spinal cord received the maximum dose, the bilateral opposite fields were limited to areas with high risk regions and the spinal cord was removed from them.

### Intensity modulation radiation therapy (IMRT)

IMRT planning was performed as inverse treatment planning with step and shoot technique using Prowess Panther TPS (Version 5.5, Prowess Inc., Concord, CA, USA). The IMRT plans were designed with three equally spaced gantry angles including F5, F7 and F9 with 5, 7, and 9 radiation fields, respectively, and were generated with a 6 MV SIMENS-ARTISTE linear accelerator (SIMENS-ARTISTE, 5918, Germany). Dose prescriptions were 66 Gy at 2.2 Gy/fraction to the PTV<sub>1</sub>, and 54 Gy at 1.80 Gy/fraction to the PTV<sub>2</sub> delivered as simultaneous integrated boosts. The dose distribution was developed in such a way that the prescribed dose contained at least 95% of the PTV and not more than 20% of each PTV volume received more than 110% of the prescribed dose. The structural constraints that were employed were based on the recommendations of the Quantitative Analysis of Normal Tissue Effects in the Clinic (QUANTEC), and other publications during the IMRT optimization are illustrated in table 1.

Table 1. Dose constraints to the OARs for IMRT planning in this study.

Structure	Constraints	Reference
Spinal Cord	D <sub>max</sub> <45 Gy or 1% of the PRV can't exceed 50 Gy	[14]
Brain Stem, Chiasm and Optic Nerve	D <sub>max</sub> <54 Gy or 1% of the PRV can't exceed 60 Gy	[14]
Mandible AND TM Joint	D <sub>max</sub> <70 Gy or 1 cm <sup>3</sup> of the PRV can't exceed 75 Gy	[14]
Parotid Gland	single gland D <sub>mean</sub> <26Gy; Or at least 50% of the gland will receive <30 Gy	[14]
Larynx	2/3 below 50 Gy V <sub>50</sub> <27%; D <sub>mean</sub> <44 Gy; D <sub>max</sub> <66 Gy	[20] [14]
Eye	D <sub>mean</sub> <35 Gy; D <sub>max</sub> <50 Gy	[14,20]
Lens	D <sub>max</sub> <8 Gy	[21]
Thyroid Gland	D <sub>mean</sub> <30 Gy D <sub>mean</sub> <45 Gy	[22] [23]
Cochlea	D <sub>mean</sub> <45 Gy; V <sub>5%</sub> <55 Gy	[14,24]

### Treatment planning evaluation

According to the ICRU 83 <sup>(25)</sup>, evaluation of therapeutic plans between different techniques were performed based on the cumulative and differential dose-volume histogram (DVH) derived from IMRT and 3D-CRT dose distribution. To evaluate PTVs, the mean dose ( $D_{\text{mean}}$ ) and the volume receiving 100% of the prescribed dose ( $V_{100\%}$ ) were studied. Homogeneity index (HI) was also used to evaluate the homogeneity of the dose delivered to the tumor using equation (1) in which  $D_{2\%}$ ,  $D_{98\%}$ , and  $D_{50\%}$  were equal to the doses received by 2%, 98% and 50% of the PTV volume.

$$HI = (D_{2\%} - D_{98\%}) / D_{50\%} \quad (1)$$

Conformity Index (CI) was used to evaluate the fitness of the isodose curves matching with PTV in treatment plans. Equation 2 shows how to calculate this value, in which  $V_{\text{PTV}}$  is the volume of PTV,  $V_{\text{TV}}$  depicts the treatment volume of prescribed isodose lines, and  $TV_{\text{PV}}$  illustrates the volume of  $V_{\text{PTV}}$  within  $V_{\text{TV}}$ .

$$CI = \frac{V_{\text{PTV}} \times V_{\text{TV}}}{TV_{\text{PV}}^2} \quad (2)$$

In addition, for OARs, the maximum dose ( $D_{\text{max}}$ ) and the mean dose ( $D_{\text{mean}}$ ) were calculated and compared between different

techniques. To derive the normal tissue complication probability (NTCP), an equivalent uniform dose (EUD)-based NTCP formulated by Gay and Niemierko was used <sup>(26,27)</sup>.

The EUD parameter is calculated with equation 3. In this equation 'a' is a unitless parameter and is special for each OARs. In addition,  $v_i$  is unitless and represents the i'th partial volume receiving dose  $D_i$  in Gy. In the NTCP equation, the quantity  $\gamma_{50}$  is a unitless model parameter for each OARs and describes the slope of the dose response curve. In addition,  $TD_{50}$  is the tolerance dose for 50% damage to the organ when the whole organ of interest is homogeneously irradiated (equation 4). The parameters for radiobiological evaluation are listed in table 2 <sup>(27-29)</sup>.

$$EUD = (\sum_i (v_i D_i^a))^{\frac{1}{a}} \quad (3)$$

$$NTCP = \frac{1}{1 + (\frac{TD_{50}}{EUD})^{4\gamma_{50}}} \quad (4)$$

### Data analysis

Data analysis was done using ANOVA test of SPSS statistical software (version 22) to compare the DVH and radiobiological parameters between different techniques. Criterion level of  $P < 0.05$  was considered a significant level.

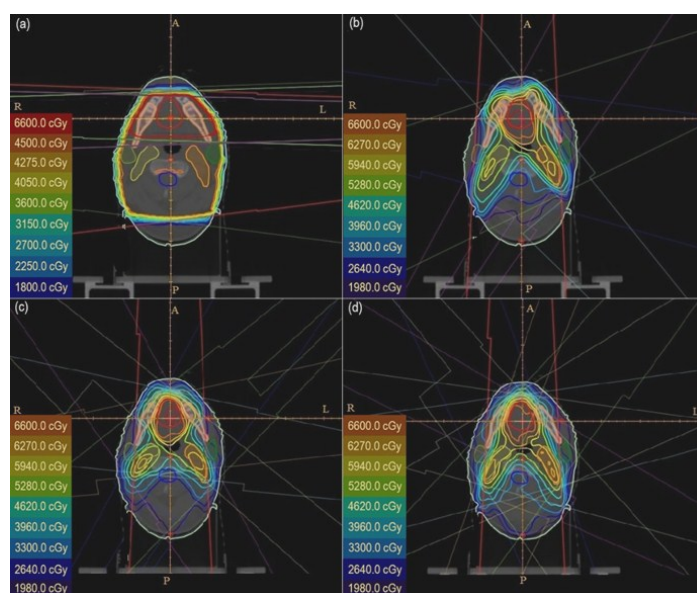
**Table 2.** Parameters used to calculate normal tissue complication probability (NTCP) for oral tongue cancer

Organ	a	$\gamma_{50}$	$TD_{50}$ (Gy)	End point
Spinal cord	7.4	4	66.5	Myelitis
Brain stem	7	3	65	Necrosis
Parotid	1	2.2	28.4	Xerostomia
Mandible	14	4	72	Osteoradionecrosis
TM joint	14	4	72	Limited joint function
Chiasm	4	3	65	Blindness
Eye	5	2	65	Blindness
Optic nerve	25	3	65	Blindness
Lens	3	1	18	Cataract

## RESULTS

The patients' characteristics included in this study are shown in table 3. Treatment planning for all techniques (3D-CRT and IMRT) was

performed in such a way to meet clinical requirements, as stated above. The dose distribution generated by each radiotherapy techniques used in this study are summarized in figure 1.



**Figure 1.** Differences in dose distribution for **(a)** 3D-CRT, **(b)** IMRT-5F, **(c)** IMRT-7F and **(d)** IMRT-9F on representative axial images on oral tongue cancer patients.

Dosimetric comparison of target volume and critical organs between 3D-CRT and IMRT is presented in tables 4-6. Table 4 shows the comparison of the dosimetric parameters of the target volume. According to this table, IMRT results showed an increase in mean received dose in the PTV<sub>1</sub> and PTV<sub>2</sub> compared to the 3D-CRT method, but these changes were not significant ( $P > 0.05$ ). The HI of the target volume dose only showed a significant improvement ( $P < 0.05$ ) in all IMRT techniques for PTV<sub>2</sub> (up to 61.54%) compared to the 3D-CRT treatment. Comparison of the results of the CI index (table 4) showed that using IMRT-9F technique can cause a significant improvement ( $P < 0.05$ ) in PTV<sub>1</sub> and PTV<sub>2</sub> (up to 28.78% and 19.90%, respectively) in comparison to the 3D-CRT. Moreover, all IMRT techniques show a significant increase ( $P < 0.05$ ) in parameter  $V_{100\%}$  in PTV<sub>1</sub> (up to 4.36%) and PTV<sub>2</sub> (up to 3.65%) compared to the 3D-CRT technique.

Table 5 shows the maximum dose of some OARs. As shown in this table, a significant decrease ( $P < 0.05$ ) is observed in the maximum dose of mandible (up to 10.10 Gy), TM joint (up to 16.42 Gy) in all IMRT techniques compared to the 3D-CRT, whereas, the maximum doses of brain stem (up to 9.87 Gy) and pituitary gland (up to 9.54 Gy) were increased for IMRT

techniques in comparison to the 3D-CRT technique used. In addition, the maximum dose information for OARs showed that using the 3D-CRT method can reduce the dose of chiasm up to 5.53 Gy compared to IMRT techniques.

Table 5 shows the OARs mean dose in various radiotherapy techniques. It can be seen that IMRT techniques led to a significant increase ( $P < 0.05$ ) in the mean dose of parotid gland (up to 7.62 Gy) compared to the 3D-CRT. Furthermore, mean dose of the larynx showed a significant reduction (up to 9.38 Gy) in the 3D-CRT method compared to the IMRT techniques, whereas there was no significant difference ( $P > 0.05$ ) in the maximum dose of this organ in different treatment techniques. This result showed that IMRT techniques were better for thyroid protection. In addition, the mean dose of left submandibular gland showed a significant decrease ( $P = 0.024$ ) using IMRT-7F related to 3D-CRT techniques.

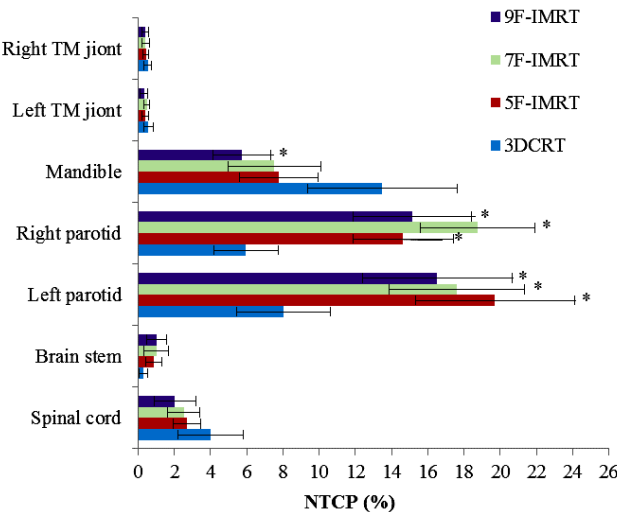
Comparison of the results of some organs such as spinal cord, eyes, lens, optic nerves, cochlea and right submandibular gland did not show any significant changes in all techniques ( $P > 0.05$ ). On the other hand, comparing the dosimetric results of the target volume and critical structure showed that the increase in the number of fields in the IMRT treatment planning

did not lead to any significant changes, except spinal cord dose between the IMRT-5F and IMR-9F ( $P=0.036$ ).

Comparison of the probability of complications in some OARs in the vicinity of the oral tongue cancer at various therapeutic techniques is shown in figure 2. According to this figure, IMRT techniques led to a significant increase ( $P<0.05$ ) in the risk of xerostomia due to more damage in the left (up to 11.66%) and right (up to 12.79%) parotid gland compared to the conventional technique.

In addition, results of NTCP evaluation showed a significant decrease (up to 7.76%) in

the damage risk to the mandible in the IMRT-9F technique compared to the 3D-CRT method ( $P=0.041$ ) (figure 2). Comparison of the probability of damage to the spinal cord indicates that there was no difference ( $P>0.05$ ) between different techniques regarding the occurrence of myelitis. In addition, evaluation of NTCP results in organs such as brain stem, chiasm, lenses, eyes, optic nerves and TM Joint did not reveal any significant difference changes ( $P>0.05$ ). Furthermore, no significant changes in NTCPs were found when changing the number of beams in the IMRT technique ( $P>0.05$ ).



**Figure 2.** Comparison of the probability of complications in OAR in different treatment modalities by Niemierko's models; \* indicated P value  $<0.05$  between 3D-CRT and F5, F7 and F9 IMRT.

## DISCUSSION

More adaptation to target volume and less damage to critical organs are the most important factors for choosing a radiation therapy modality for cancer treatment. The present study is a dosimetric and radiobiological comparison between various IMRT techniques and 3D-CRT technique in the treatment of early stages of oral tongue cancer.

The results of this study showed a significant improvement of 28.78% and 19.90% in the CI index for  $PTV_1$  and  $PTV_2$  and 61.54% improvement in the HI index for  $PTV_2$  by IMRT

**Table 3.** Clinical characteristics of patients with 3D-CRT or IMRT

Patient characteristics		3DCRT or IMRT
Number of patients		38
Age, years	Median	47
	Range	23-59
Gender (No)	Males	22
	Females	16
Cancer site	tongue	38
TNM classification		
T Stage	T1	7
	T2	31
N Stage	N0	38
M Stage	M0	38
Cancer stage	I	7
	II	31
Treatment	RT alone	38

techniques compared to 3D-CRT (table 4) ( $P<0.05$ ). Previously, Ahmed *et al.* <sup>(30)</sup> showed 8.54% improvement for HI index of  $PTV_2$ ; moreover, Cozzi *et al.* <sup>(31)</sup> found a significant improvement of 12.57% in the CI index for the target volume in the IMRT techniques in comparison with 3D-CRT treatment for patients to oral cavity cancer.

Comparing the dosimetric evaluation of the OARs indicated that although the IMRT techniques resulted in significant decrease in the received dose of mandible, TM joint and thyroid gland compared to the 3D-CRT method, this technique significantly increased the dose of the

brain stem, parotid glands, larynx, pituitary gland and chiasm (tables 5 and 6). The significant increase in the mean dose of the right parotid was up to 46.60% whereas for the left parotid, it is up to 33.20% in IMRT techniques compared to the 3D-CRT method. Ahmed et al. [30] reported that for patients with oral cavity cancer (including oral tongue patients with T2-4/N0-2 staging), IMRT techniques resulted in up to 38.68% and 40.69% decrease in the mean dose of the right and left parotid, respectively. Furthermore, Vergeer *et al.* <sup>(13)</sup> showed a significant reduction in parotid (up to 43.99%) and submandibular gland (up to 7.38%) in the IMRT techniques compared to 3D-CRT that was compatible with reduction of submandibular gland dose (up to 17.79%) in IMRT-7F technique related to 3D-CRT reported in our study.

However, Perez *et al.* <sup>(14)</sup> stated an increase in parotid dose in the IMRT technique over 3D-CRT, and concluded that IMRT may not be needed for patients at T1-2/N0 stage for oral cavity cancer. This significant increase in mean dose of parotid gland by IMRT occurred in a situation that we provided more protection from parotid gland (mean dose up to 2.57 Gy) compared to similar studies such as those conducted by Gomez *et al.* <sup>(32)</sup>.

In addition, the results of Ahmed *et al.* <sup>(30)</sup>

showed a significant reduction (up to 3.27%) in mandible doses in the IMRT techniques compared to 3D-CRT. This dose reduction was comparable to our study (up to 15.16%). Nonetheless, the decrease in mandible dose in IMRT techniques in this study was comparable to that in other studies such as Gomez *et al.* <sup>(32)</sup> due to the increased sparing of the mandibular bone (up to 10.88 Gy) in the optimization process.

The results of this study showed that although the change in the beam numbers and their direction in the IMRT technique could result in small improvements of received dose by organs compared to 3D-CRT, this improvement did not compensate the significant increase in doses of organs such as the brain stem, parotid glands, and the larynx by IMRT technique. This finding indicated that the change in the number and direction of the IMRT field beams caused no significant results in the organ dose, and only a significant decrease ( $P=0.036$ ) in the maximum doses of the spinal cord (up to 9.61%) was observed between the IMRT-9F technique and IMRT-5F. This result has also been previously observed in some other publications so that they have not considered differences in the beam number <sup>(30,33)</sup>.

**Table 4.** Comparison of the dosimetric parameters of the target volume between 3D conventional radiotherapy and three IMRT plans.

Target	Parameter	3D-CRT	IMRT-5F	IMRT-7F	IMRT-9F	P value		
						3D & 5F	3D & 7F	3D & 9F
PTV <sub>1</sub>	D <sub>mean</sub>	67.72 ± 2.70	68.69 ± 2.24	68.91 ± 2.37	68.71 ± 2.42	0.301	0.142	0.264
	V <sub>100%</sub>	93.19 ± 1.15*	95.71 ± 1.34*	97.56 ± 1.47*	97.37 ± 1.53*	0.032	0.003	0.011
	HI	0.21 ± 0.06	0.19 ± 0.04	0.18 ± 0.03	0.17 ± 0.03	0.320	0.184	0.068
	CI	2.71 ± 0.34*	2.19 ± 0.43	2.05 ± 0.47	1.93 ± 0.35*	0.074	0.059	0.012
PTV <sub>2</sub>	D <sub>mean</sub>	58.73 ± 2.66	60.55 ± 2.45	60.63 ± 2.68	61.07 ± 2.28	0.111	0.103	0.084
	V <sub>100%</sub>	92.75 ± 1.13*	95.91 ± 1.36*	95.25 ± 1.25*	96.40 ± 1.28*	0.026	0.041	0.014
	HI	0.65 ± 0.07*	0.26 ± 0.03*	0.26 ± 0.02*	0.25 ± 0.03*	<0.001	<0.001	<0.001
	CI	4.12 ± 0.43*	3.98 ± 0.38	3.59 ± 0.42	3.30 ± 0.36*	0.414	0.123	0.037

\* indicated P value <0.05 between 3D-CRT with various IMRT techniques.

According to our results, IMRT techniques led to a significant increase ( $P<0.05$ ) in the risk of xerostomia due to more damage in parotid gland (up to 12.79%) compared to the conventional technique in early stage of cancer but Lambrecht

*et al.* <sup>(34)</sup> showed that IMRT led to less xerostomia (up to 9%) in IMRT than 3D-CRT in advanced stages of head and neck cancer.

Although the results of this study showed an increase in the dose of some organs in the IMRT

techniques in the oral tongue cancer patients, Chen *et al.* <sup>(11)</sup> concluded the superiority of IMRT for control of the three local regional recurrences in oral cavity cancer patients. This study indicated that the three local regional controls of IMRT and 3D-CRT were 76.3% and 53.5% respectively. In addition, Studer *et al.* <sup>(12)</sup>

indicated the superiority of IMRT modality in patients with oral cavity cancer by increasing two years local control from 70-80% in 3D-CRT to 92% in IMRT technique while Lambrecht *et al.* <sup>(34)</sup> showed no significant differences in three years local control between 3D-CRT and IMRT techniques.

**Table 5.** Maximum dose of organs at risk in different treatment modalities.

Organ at risk (OAR)	3D-CRT	IMRT-5F	IMRT-7F	IMRT-9F	P value		
					3D & 5F	3D & 7F	3D & 9F
Spinal Cord	39.76 ± 2.24	41.01 ± 2.07**	40.38 ± 2.21	37.07 ± 1.74**	0.054	0.560	0.074
Brain Stem	30.70 ± 2.94*	39.61 ± 2.85*	40.57 ± 2.79*	39.28 ± 2.58*	<0.001	<0.001	<0.001
Mandible	66.62 ± 2.58*	57.10 ± 1.91*	57.04 ± 2.11*	56.52 ± 2.26*	<0.001	<0.001	<0.001
TM Joint (L)	44.12 ± 2.97*	31.71 ± 2.39*	29.91 ± 2.83*	29.67 ± 2.46*	<0.001	<0.001	<0.001
TM Joint (R)	45.54 ± 2.98*	32.82 ± 2.25*	29.12 ± 2.22*	32.00 ± 2.31*	<0.001	<0.001	<0.001
Chiasm	2.69 ± 1.07*	8.22 ± 3.28*	7.10 ± 2.45*	6.30 ± 2.24*	<0.001	0.002	0.009
Eye (L)	3.01 ± 1.07	4.27 ± 0.90	4.08 ± 1.08	4.39 ± 0.91	0.065	0.078	0.058
Eye (R)	3.72 ± 0.93	4.43 ± 1.03	4.01 ± 1.16	4.68 ± 0.98	0.145	0.598	0.089
Optic Nerve (L)	2.64 ± 0.45	3.36 ± 0.64	3.61 ± 0.75	3.08 ± 0.69	0.354	0.098	0.497
Optic Nerve (R)	2.48 ± 1.02	4.51 ± 1.34	4.43 ± 1.27	4.21 ± 1.71	0.058	0.067	0.074
Lens (L)	0.75 ± 0.55	1.85 ± 0.75	1.75 ± 0.50	1.62 ± 0.73	0.187	0.275	0.421
Lens (R)	0.99 ± 0.068	2.07 ± 0.79	1.75 ± 0.58	1.86 ± 0.61	0.274	0.512	0.341
Larynx	42.76 ± 2.92	43.11 ± 2.63	40.46 ± 2.95	40.39 ± 2.46	0.754	0.546	0.489
Pituitary Gland	11.08 ± 3.08*	20.62 ± 3.98*	19.54 ± 3.27*	18.08 ± 3.15*	<0.001	<0.001	<0.001

\* indicated P value <0.05 between 3D-CRT and IMRT techniques; \*\* indicated P value <0.05 between different IMRT techniques.

**Table 6.** Mean dose of organs at risk in various treatment modalities

Organ at risk (OAR)	3D-CRT	IMRT-5F	IMRT-7F	IMRT-9F	P value		
					3D & 5F	3D & 7F	3D & 9F
Parotid (L)	17.71 ± 1.79*	23.59 ± 1.83*	23.51 ± 2.09*	23.07 ± 1.72*	0.020	0.037	0.047
Parotid (R)	16.35 ± 1.23*	23.07 ± 2.18*	23.97 ± 1.52*	23.03 ± 1.66*	0.007	<0.001	0.011
Eye (L)	1.26 ± 0.28	1.64 ± 0.34	1.56 ± 0.29	1.54 ± 0.33	0.460	0.531	0.576
Eye (R)	1.23 ± 0.21	1.71 ± 0.36	1.67 ± 0.31	1.58 ± 0.35	0.251	0.441	0.501
Submandibular Gland (L)	32.14 ± 2.95*	28.71 ± 2.04	26.42 ± 2.20*	28.35 ± 2.60	0.158	0.024	0.089
Submandibular Gland (R)	32.44 ± 2.30	30.52 ± 2.86	30.63 ± 2.20	31.15 ± 2.47	0.304	0.203	0.424
Thyroid Gland	25.43 ± 1.66*	12.05 ± 1.51*	12.33 ± 1.61*	11.84 ± 1.56*	<0.001	<0.001	<0.001
Cochlea (L)	15.60 ± 3.77	11.37 ± 3.03	10.47 ± 3.95	10.86 ± 3.69	0.246	0.073	0.126
Cochlea (R)	16.30 ± 3.82	12.88 ± 3.93	11.07 ± 3.47	11.67 ± 3.33	0.154	0.084	0.189
Larynx	17.84 ± 2.89*	26.30 ± 2.47*	27.22 ± 2.46*	25.27 ± 2.69*	<0.001	<0.001	<0.001

\* indicated P value <0.05 between 3D-CRT and F5, F7 and F9 IMRT.

It should also be noted that the use of more fields and increased scattered radiation in IMRT techniques can increase the volume of tissues exposed to low level doses. It can be expected that this increase will lead to an increase in secondary malignancies and complications of organs such as parotid (up to 12.79%) from the 3D-CRT technique to the IMRT technique (figure 2). Most portion of the scattered radiation is from head leakage due to the increase in Monitor Unit (MU), and the amount of leakage in these areas is in a way that its effects cannot be ignored<sup>(35)</sup>. However, it should be noted that although in this study, IMRT resulted in an increase in parotid dose, brain stem and larynx, this increase was not higher than the specified dose constraint of these organs.

## CONCLUSION

The results of this study indicated that the IMRT techniques can lead to a better conformity and homogeneity dose distribution to target volume and reduction in the probability of mandibular complications compared with the 3D-CRT method, but choosing this method for oral tongue in the T1-T2/N0 stage cancer patients leads to an increase in the dose of some other organs and xerostomia risk. Selection of the best treatment plan is a compromise between advantages and disadvantages of IMRT and 3D-CRT for each patient.

### Funding/Support

This study was supported by the Isfahan University of Medical Sciences (Grant No. 197011).

### Ethical statements

This study is retrospective and doesn't involve the treatment of patients, it did not violate ethics.

**Conflicts of interest:** Declared none.

## REFERENCES

1. Jemal FDA, Bray F, Center MM, Ferlay J, Ward E (2011) Global cancer statistics. *Cancer J Clin*, **61**: 69–90.
2. Miller KD, Siegel RL, Lin CC, Mariotto AB, Kramer JL, Rowland JH, Stein KD, Alteri R, Jemal A (2016) Cancer treatment and survivorship statistics, 2016, CA. *Cancer J Clin*, **66**: 271–289.
3. Siegel RL, Miller KD, Jemal A (2019) Cancer statistics, 2019, CA. *Cancer J Clin*, 7-34.
4. Collan J, Lundberg M, Vaalavirta L, Bäck L, Kajanti M, Mäkitie A, Tenhunen M, Saarilahti K (2011) Patterns of relapse following surgery and postoperative intensity modulated radiotherapy for oral and oropharyngeal cancer. *Acta Oncol, (Madr)*, **50**: 1119–1125.
5. De Felice F, Musio D, Terenzi V, Valentini V, Cassoni A, Tombolini M, De Vincentiis M, Tombolini V (2014) Treatment improvement and better patient care: which is the most important one in oral cavity cancer? *Radiat Oncol*, **9**: 263.
6. Chen CC, Lin JC, Chen KW (2015) Lymph node ratio as a prognostic factor in head and neck cancer patients. *Radiat Oncol*, **10**: 181.
7. Huang TY, Hsu LP, Wen YH, Huang TT, Chou YF, LeeCF, Yang MC, Chang YK, Chen PR (2010) Predictors of locoregional recurrence in early stage oral cavity cancer with free surgical margins. *Oral Oncol*, **46**: 49–55.
8. Chen WC, Hwang TZ, Wang WH, Lu CH, Chen CC, Chen CM, Weng HH, Lai CH, Chen MF (2009) Comparison between conventional and intensity-modulated post-operative radiotherapy for stage III and IV oral cavity cancer in terms of treatment results and toxicity. *Oral Oncol*, **45**: 505–510.
9. Khan FM and Gibbons JP (2014) Khan's the physics of radiation therapy, Lippincott Williams & Wilkins, .
10. Daly ME, Le QT, Kozak MM, Maxim PG, Murphy JD, Hsu A, Loo Jr BW, Kaplan MJ, Fischbein NJ, Chang DT (2011) Intensity-modulated radiotherapy for oral cavity squamous cell carcinoma: patterns of failure and predictors of local control. *Int J Radiat Oncol Biol Phys*, **80**: 1412–1422.
11. ChenPY, Chen HHW, Hsiao JR, Yang MW, Hsueh WT, Tasi ST, Lin FC, Wu YH (2012) Intensity-modulated radiotherapy improves outcomes in postoperative patients with squamous cell carcinoma of the oral cavity. *Oral Oncol*, **48**: 747–752.
12. Studer G, Zwahlen RA, Graetz KW, Davis BJ, Glanzmann C (2007) IMRT in oral cavity cancer. *Radiat Oncol*, **2**: 16.
13. Vergeer MR, Doornaert PAH, Rietveld DHF, Leemans CR, Slotman BJ, Langendijk JA (2009) Intensity-modulated radiotherapy reduces radiation-induced morbidity and improves health-related quality of life: results of a nonrandomized prospective study using a standardized follow-up program. *Int J Radiat Oncol Biol Phys*, **74**: 1–8.
14. Halperin EC, Brady LW, WazerDE, Perez CA (2013) Perez & Brady's principles and practice of radiation oncology, Lip-

- pincott Williams & Wilkins, .
15. Ghosh G, Gupta G, Malviya A, Saroj D (2018) Comparison three-dimensional conformal radiotherapy versus intensity modulated radiation therapy in local control of head and neck cancer. *J Cancer Res Ther*, **14**: 1412.
  16. Rosenthal DI, Chambers MS, Fuller CD, Rebueno NCS, Garcia J, Kies MS, Morrison WH, Ang KK, Garden AS (2008) Beam path toxicities to non-target structures during intensity-modulated radiation therapy for head and neck cancer. *Int J Radiat Oncol Biol Phys*, **72**: 747–755.
  17. Yong JHE, McGowan T, Redmond-Misner R, Beca J, WardeP, Gutierrez E, Hoch JS (2016) Estimating the costs of intensity-modulated and 3-dimensional conformal radiotherapy in Ontario. *Curr Oncol*, **23**: e228.
  18. Morgan WF, Naqvi SA, Yu C, Smith LE, Bose M (2002) Does the time required to deliver IMRT reduce its biological effectiveness. *Int J Radiat Oncol Biol Phys*, **54**: 222.
  19. Lee S, Cao YJ, Kim CY (2015) Physical and radiobiological evaluation of radiotherapy treatment plan, evolution of ionizing radiation research. Dr. Mitsuru N (Ed.), Croatia.
  20. Eisbruch A, Chao KC, Garden A, (2004) Phase I/II study of conformal and intensity modulated irradiation for oropharyngeal cancer (RTOG 0022). *Radiat Ther Oncol Gr Am Coll Radiol*, 1-29.
  21. Chen BB, Huang SM, Xiao WW, Sun WZ, Liu M, Lu TX, Deng XW, Han F (2018) Prospective matched study on comparison of volumetric-modulated arc therapy and intensity-modulated radiotherapy for nasopharyngeal carcinoma: dosimetry, delivery efficiency and outcomes. *J Cancer*, **9**: 978–986.
  22. Fujiwara M, Kamikonya N, Odawara S, Suzuki H, Niwa Y, Takada Y, Doi H, Terada T, Uwa N, Sagawa K (2015) The threshold of hypothyroidism after radiation therapy for head and neck cancer: a retrospective analysis of 116 cases. *J Radiat Res*, **56**: 577–582.
  23. Zhai R, Kong F, Du C, Hu C, Ying H (2017) Radiation-induced hypothyroidism after IMRT for nasopharyngeal carcinoma: clinical and dosimetric predictors in a prospective cohort study. *Oral Oncol*, **68**: 44–49.
  24. Marks LB, Ten Haken RK, Martel MK (2010) Guest editor's introduction to QUANTEC: a users guide. *Int J Radiat Oncol Biol Phys*, **76**: S1–S2.
  25. IC on RU and Measurements? (2010) ICRU Report 83 Prescribing, Recording, and Reporting Photon-beam Intensity-modulated Radiation Therapy (IMRT)-Journal of the ICRU- Vol 10 No 1 2010, Oxford University Press.
  26. Sanchez-Nieto B and Nahum AE (1999) The delta-TCP concept: a clinically useful measure of tumor control probability. *Int J Radiat Oncol Biol Phys*, **44**: 369–380.
  27. Gay HA and Niemierko A (2007) A free program for calculating EUD-based NTCP and TCP in external beam radiotherapy. *Phys Medica*, **23**: 115–125.
  28. Lee TF, Ting HM, Chao PJ, Fang FM (2012) Dual arc volumetric-modulated arc radiotherapy (VMAT) of nasopharyngeal carcinomas: a simultaneous integrated boost treatment plan comparison with intensity-modulated radiotherapies and single arc VMAT. *Clin Oncol*, **24**: 196–207.
  29. Emami B (2013) Tolerance of normal tissue to therapeutic radiation. *Reports Radiother Oncol*, **1**:35-48.
  30. Ahmed M, Hansen VN, Harrington KJ, Nutting CM (2009) Reducing the risk of xerostomia and mandibular osteoradionecrosis: the potential benefits of intensity modulated radiotherapy in advanced oral cavity carcinoma. *Med Dosim*, **34**: 217–224.
  31. Cozzi L, Fogliata A, Bolsi A, Nicolini G, Bernier J (2004) Three-dimensional conformal vs. intensity-modulated radiotherapy in head-and-neck cancer patients: comparative analysis of dosimetric and technical parameters. *Int J Radiat Oncol Biol Phys*, **58**: 617–624.
  32. Gomez DR, Zhung JE, Gomez J, Chan K, Wu AJ, Wolden SL, Pfister DG, Shaha A, Shah JP, Kraus DH (2009) Intensity-modulated radiotherapy in postoperative treatment of oral cavity cancers. *Int J Radiat Oncol Biol Phys*, **73**: 1096–1103.
  33. Vallard A, Guy J, Mengue Ndong S, Vial N, Rivoirard R, Auberdia P, Méry B, Langrand-Escure J, Espenel S, Moncharmont C (2016) Intensity-modulated radiotherapy or volumetric-modulated arc therapy in patients with head and neck cancer: Focus on salivary glands dosimetry. *Head Neck*, **38**: 1028–1034.
  34. Lambrecht M, Nevens D, Nuyts S (2013) Intensity-modulated radiotherapy vs. parotid-sparing 3D conformal radiotherapy. *Strahlentherapie Und Onkol*, **189**: 223–229.
  35. McQuaid D, Dunlop A, Nill S, Franzese C, Nutting CM, Harrington KJ, Newbold KL, Bhide SA (2016) Evaluation of radiotherapy techniques for radical treatment of lateralized oropharyngeal cancers. *Strahlentherapie Und Onkol*, **192**: 516–525.