

Protective effect of L-carnitine and vitamin E on gastrointestinal tract organs on male rats post radiation exposure

N.F. El Fouly^{1*} and H.H. Ali²

¹Lecturer, Health Radiation Research Department, National Center for Radiation Research and Technology, Atomic Energy Authority, Cairo, Egypt

²Lecturer, Department of Clinical Pathology, Faculty of Medicine, Ain Shams University, Egypt

ABSTRACT

Background: Although ionizing radiation is a risk factor, it is a therapeutic agent for cancer. **Objectives:** The protective and defensive effect of L-Carnitine and vitamin E on gastrointestinal tract organs (liver, spleen and intestine) post whole body gamma irradiation exposure. **Material and methods:** 56 male albino rats, which were divided into four groups (14 rats per group); group (I): Control group, group (II): rats were irradiated with a single dose of whole body gamma rays (6 Gy) and left 4 weeks. Group (III): rats were given L- Carnitine for five days, then irradiated by same dose. Group (IV): rats were received L- Carnitine and vitamin E for five days then irradiated by same dose. At 1 and 4 weeks post radiation exposure, seven rats from each group were scarified, blood and GIT tissue samples were collected. **Results:** Liver and blood samples: radiation related degenerative damage was obviously higher in the radiation group than the control group with elevated liver enzymes, however pretreatment groups revealed reduced radiation induced acute liver damage compared to the radiation group with significant improvement in liver enzymes. Spleen and intestinal samples: radiation induced damage were significantly higher in the radiation group versus the control group, however, in pre-treatment groups no significant improvement in radiation induced effects were noted compared with radiation group. **Conclusion:** A great radio protective effect of both L- carnitine and vitamin E after radiation exposure mainly in liver tissue and its enzymes but not in both spleen and intestinal tissue.

Keywords: L-carnitine, γ -irradiation, liver, spleen, Intestine.

► Original article

*Corresponding authors:

Nevien Fouad El Fouly, PhD.,

E-mail:

novaelfouly@yahoo.com

Revised: April 2020

Accepted: June 2020

Int. J. Radiat. Res., January 2021;
19(1): 205-211

DOI: 10.29252/ijrr.19.1.205

INTRODUCTION

Ionizing radiation (IR) is a risk factor and a therapeutic agent for cancer ⁽¹⁾. IR induces oxidative stress (OS) and cell death ⁽²⁾.

During the development of liver cell carcinogenesis, OS has a significant role in disrupting either normal cell function or genetic materials. So antioxidant drugs in form of L-carnitine and vitamin E can control this damage ⁽³⁾.

Radiation-related acute/chronic colitis

induced by the cytotoxic effect of the ionizing radiation on the intestinal mucosa by increasing the levels of free oxygen radicals, antioxidant drugs as L-carnitine and vitamin E prevent free oxygen radical formation, no peroxidative stress effect on the cell and protect against radiation-induced colitis ⁽⁴⁾.

Radiation-related liver damage observed in 5- 10% of patients post radiation exposure by a dose exceeding 30 Gy ⁽⁵⁾. In 5-15% of patients, treatment is stopped or changing the dose due to colonic mucosal damage caused by

abdominopelvic radiotherapy ⁽⁶⁾.

Serum L-carnitine levels reduced in patients with gastrointestinal cancer due to compromised nutrition and deregulation of lipid and carbohydrate metabolism ⁽⁷⁾. Also antioxidant drug especially carnitine reduce radiation related fatigue syndrome in patients with abdominopelvic malignances ⁽⁸⁾.

The aim of this study was to determine the protective and beneficial effect of L-carnitine and vitamin E on GIT organ (liver, spleen and intestine) post whole body gamma irradiation exposure.

MATERIALS AND METHODS

Source of chemicals

L-Carnitine (LC) and vitamin E (VE) were obtained from Sigma-Aldrich chemical company, Italy, the products were provided as L-Carnitine (300mg/kg b wit) was dissolved in 0.8% physiological saline ⁽⁹⁾ and vitamin E (α -tocopherol acetate) was dissolved in corn oil, all other chemicals used of analytical grade.

Experimental animals

The experiments were performed on 56 male Albino rats ranging from 120-150 gram, gained from National Center for Radiation Research and Technology (NCRRT) animal house (Atomic Energy Authority, Cairo, Egypt), in which animals were staying in a designed cage (5 rats per cage) and were kept under standard conditions; in a room with a 12-h day-night cycle, temperature of 24 - 28C, humidity of 45-64%. All animals were fed with semi purified diet and water ad libitum for 10 days before the start of the experiment. The study was approved by the institutional ethical committee board with Registration number: 2A/19, dated 8/1/2019.

Irradiation

Whole-body gamma-irradiation exposure to a single dose level of 6 Gy delivered at a dose rate of 0.689 Gy/s was done at the National Centre for Radiation Research and Technology

(NCRRT), Atomic Energy Authority, Cairo, Egypt, using (137 cesium) Gamma Cell-40 biological radiator.

Experimental design

The rats were divided randomly into four groups (14 rats in each group):

Group I: control group, Rats were used as negative control.

Group II: IR group, Rats were used as positive control; rats were irradiated with a single dose of whole-body γ -rays (6 Gy) and left for 4 weeks.

Group III: IR& LC group, rats were received L-Carnitine 300mg/kg via intra peritoneal injection daily for five days and irradiated with a single dose of whole-body γ -rays (6 Gy) 30 minutes after the last treatment dose.

Group IV: IR, LC & VE group, rats were received L-Carnitine 300mg/kg via intra peritoneal injection and vitamin E 40 mg/kg intramuscular daily for five days and irradiated with a single dose of whole-body γ -rays (6 Gy) 30 minutes after the last treatment dose.

Biochemical and Histopathological analysis

At 1 and 4 weeks after radiation exposure, seven rats from each group were sacrificed by decapitation. By cardiac puncture blood samples were collected in each group and centrifuged at 3000 RPM for 10 min at 4°C and liver function were evaluated (AST, ALT, albumin and Total bilirubin)

The collected samples (colon, liver and spleen) were fixed in 10% formalin overnight. After processing the tissues in alcohol, all tissues were fixed into paraffin, divided into five micrometer thick sections the stained by hematoxylin-eosin.

Statistical analysis

The data were analyzed using standard statistical methods (statistical version 7 program). All data were expressed as mean \pm SD. One-way analysis of variance (ANOVA) was used for statistical comparisons between the groups. The differences were considered significant when the probability was less than 0.05.

Histopathological results

Liver

Histopathological examinations of liver sections of control rats showed the normal structure of hepatic tissues (figure 1A). Histopathological examination of liver of rats one week after irradiation (6 Gy) (figure 1B & 1C) showed loss of hepatic details with apoptotic changes, hemorrhage, necrosis and edema with leukocyte infiltration of hepatic tissues (H& E \times 400). Liver of rats treated with LC for 5 consecutive days prior to irradiation (6 Gy), one week after irradiation showing degenerative

changes of hepatic tissues and edema (H& E \times 400) (figure 1D). Hepatic tissue of rats in group IV showed congested central vein with leukocyte infiltration (H& E \times 400) (figure 1E). Liver of irradiated rats, 4 weeks after irradiation showed focal coagulative necrosis (figure 1F). (H& E \times 400). Liver of rats treated with LC for 5 consecutive days prior to irradiation (6 Gy), 4 weeks after irradiation showing normal hepatic tissues (figure 1G). Hepatic tissue of rats of group IV, 4 weeks after irradiation showed normal arranged hepatic cells (figure 1H).

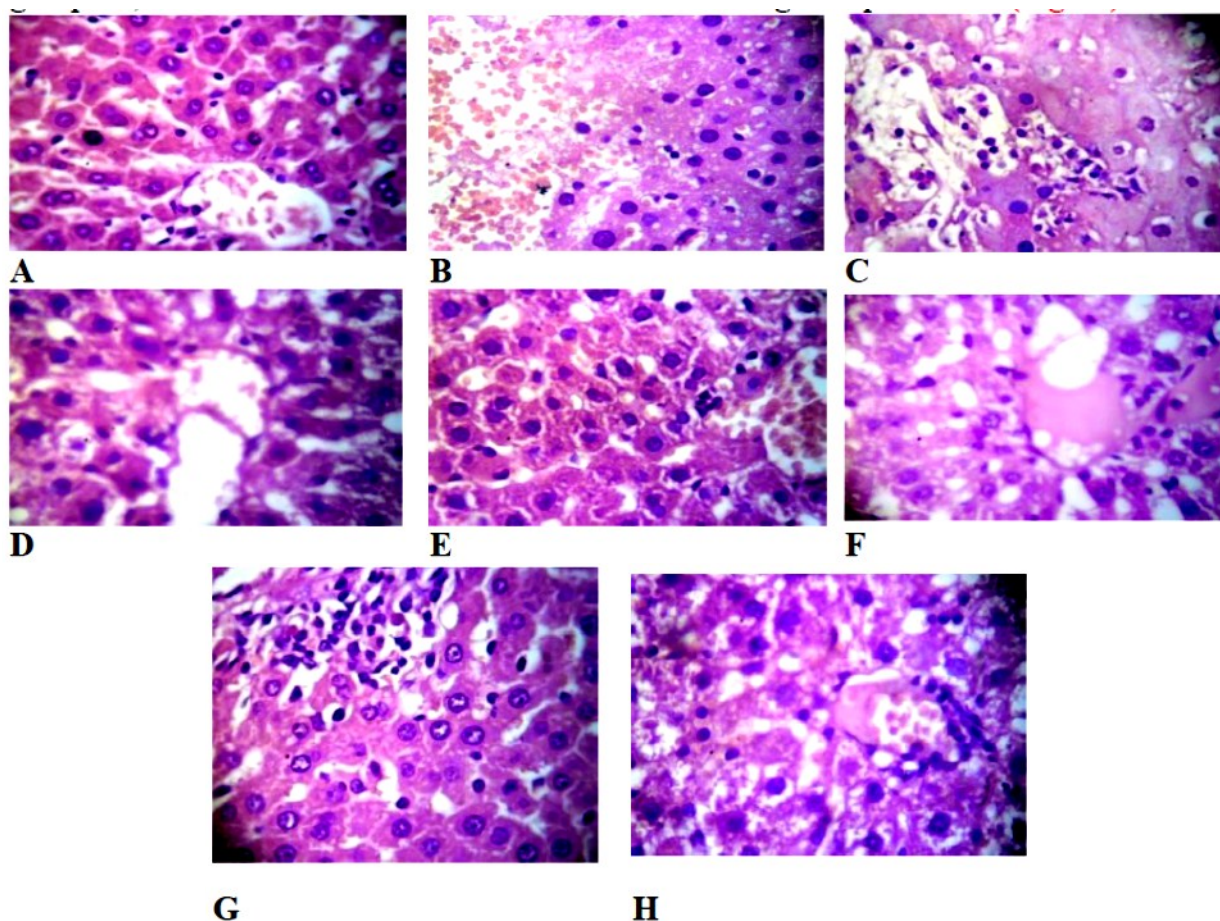


Figure 1. Hepatic toxicity post (IR), (LC) & (VE) exposure; (A): Control, one week after IR; (B & C): IR; (D): LC&IR; (E): LC, VE & IR. 4 weeks after IR; (F): IR. (G): LC&IR (H): LC, VE & IR.

Spleen

Histo-pathological examinations of spleen section of the control group showed normal histological structure (figure 2A). Histopathologic examination of spleen of group (II) after one week, showed hyalinization and

fibrinoid necrosis of splenic vessels (figure 2B). Spleen of rat treated with LC for 5 consecutive days prior to irradiation (6 Gy), one week after irradiation showed depletion of lymphoid tissues and focal coagulative necrosis (figure 2C). However, Spleen of rat of group IV after one

week showing serofibrinous necrosis (figure 2D). Spleen of irradiated rat, 4 weeks after irradiation showed edema with atrophy of splenic lymphoid tissues (figure 2E). (H& E $\times 400$). Spleen of rat treated with LC for 5 consecutive days prior to irradiation (6 Gy), 4

weeks after irradiation showing regenerative of lymphoid tissues beside edema (figure 2F). Spleen tissue of rat of group IV, 4 weeks after irradiation showed showing the regeneration of lymphoid tissues (H& E $\times 400$) (figure 2G).

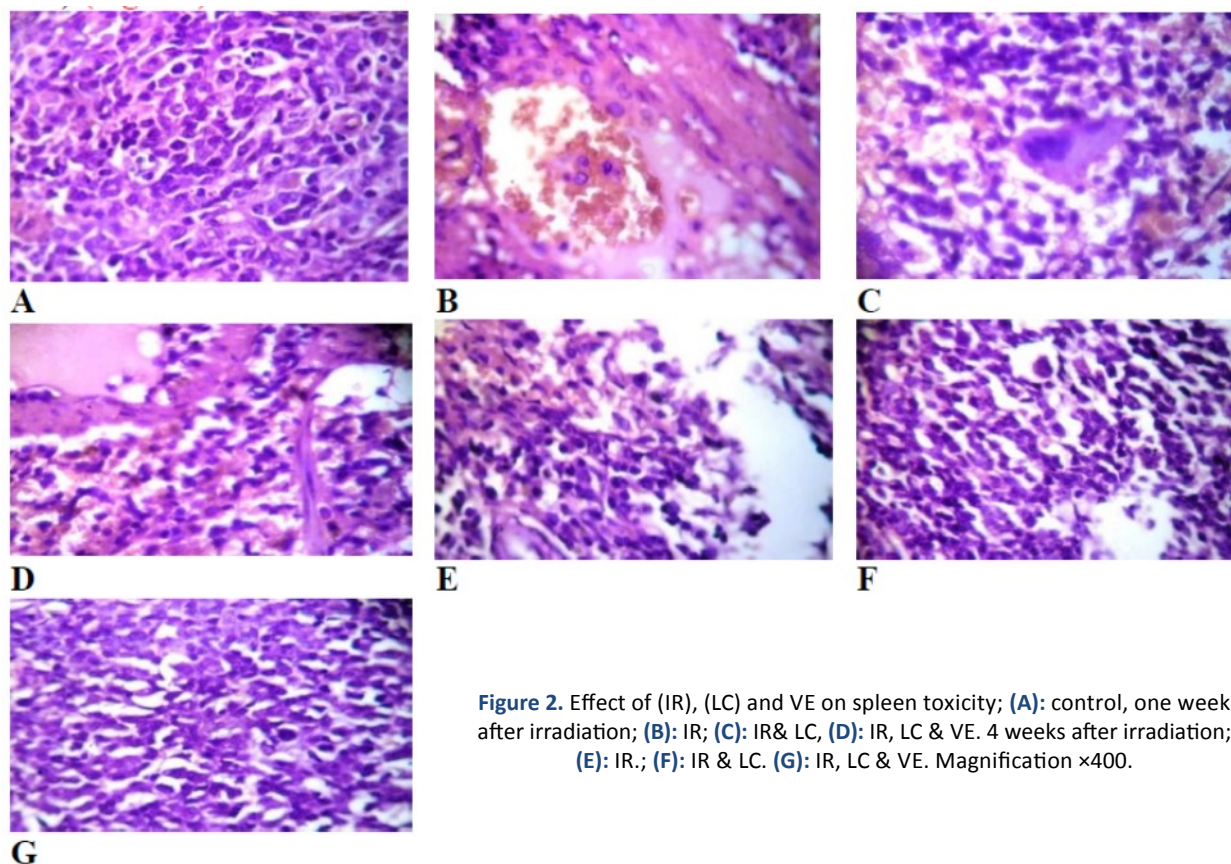


Figure 2. Effect of (IR), (LC) and VE on spleen toxicity; (A): control, one week after irradiation; (B): IR; (C): IR& LC, (D): IR, LC & VE. 4 weeks after irradiation; (E): IR.; (F): IR & LC. (G): IR, LC & VE. Magnification $\times 400$.

Intestine

Histological examinations of intestinal sections of control rats detect the normal intestinal villi (figure 3A). Histopathological examination of intestine of rat one week after irradiation (6 Gy) (figure 3B) showing severe erosion, necrosis of the mucosal layer, swelling and invasion of inflammatory cells of the submucosal layer (H&E $\times 400$). Intestine of rat treated with LC for 5 consecutive days prior to irradiation (6 Gy), one week after irradiation showing mucosal ulceration with submucosal edema and dense inflammatory infiltrate, edematous and dystrophic external muscular layers. (H& E $\times 400$) (figure 3C). Intestine tissue of rat in group IV showing leuckocyte infiltration around degenerated Bruner's glands. (H&E

$\times 400$) (figure 3D). Intestine of irradiated rat, 4 weeks after irradiation showing ulcerative intestinal villi with leuckocyte infiltration (H& E $\times 400$). (figure 3E). (H& E $\times 400$). Intestine of rat treated with LC for 5 consecutive days prior to irradiation (6 Gy), 4 weeks after irradiation showing mild degenerated changed in the mucosa of the intestinal villi (H& E $\times 400$). (figure 3F). Intestine of rat of group IV, 4 weeks after irradiation showed showing increase the goblet cells in the mucosa of the intestinal villi (H& E $\times 400$) (figure 3G).

So we concluded that co- supplementation of both L-carnitine and vitamin E drugs had a radio protective effect and improved radiation induced damage to the liver, spleen and intestine but more significantly in liver tissue.

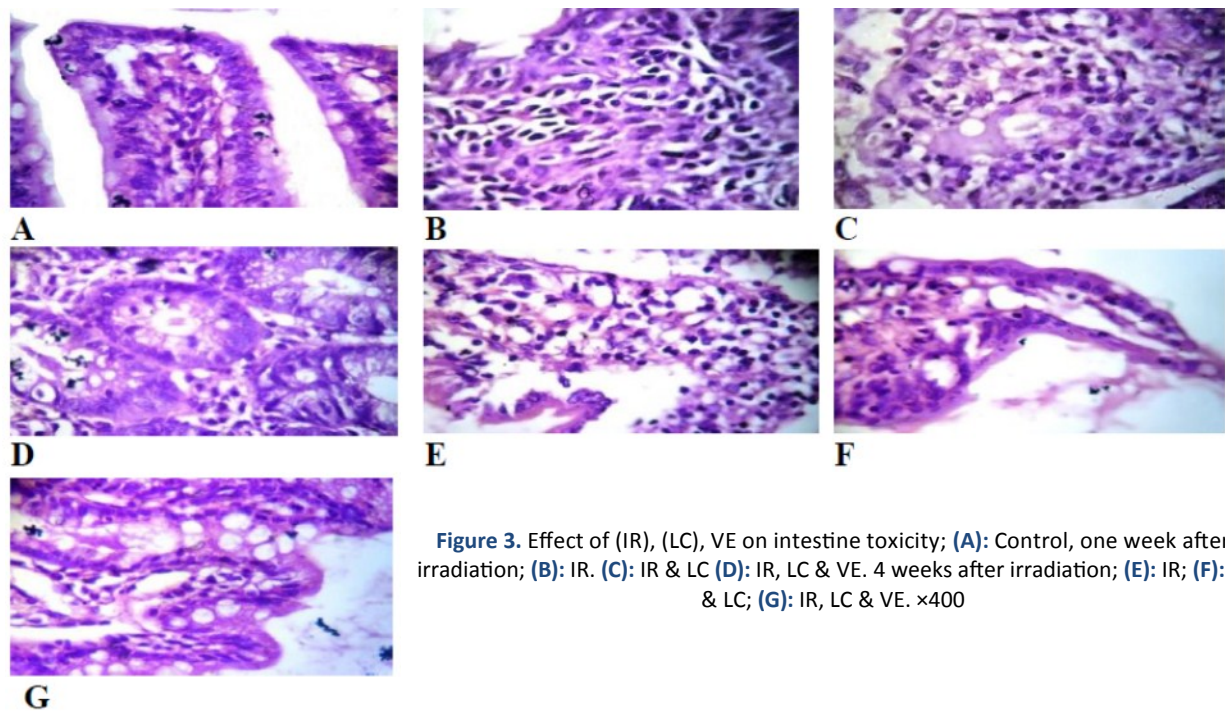


Figure 3. Effect of (IR), (LC), VE on intestine toxicity; **(A):** Control, one week after irradiation; **(B):** IR. **(C):** IR & LC **(D):** IR, LC & VE. 4 weeks after irradiation; **(E):** IR; **(F):** IR & LC; **(G):** IR, LC & VE. $\times 400$

RESULTS

As shown in table (1), there is a significant change between radiation group versus control group regarding liver enzymes (AST & ALT) after one-week post radiation exposure, also a significant change by improving levels of liver

enzyme in both groups of radiation exposure post radio protective materials (III & IV) versus radiation group only (II). However, regarding the synthetic function of the liver (serum albumin & Total bilirubin) no changes between all groups, as it needs a large cumulative dose of radiation over a longer period to be affected.

Table 1. Effect of irradiation (IR), L-carnitine (LC) and/or Vitamin E (E) and their combination (LC+IRR) on serum alanine transaminase (ALT), aspartate transaminase (AST), total bilirubin and albumin in male albino rat serum.

Biochemical Parameters	Groups	Days Post Radiation	
		7	30
ALT (IU/L)	Control	38.2 \pm 3.8	38.2 \pm 4.6
	IR	113.6 \pm 2.2 ^a	39.2 \pm 2.0
	LC+IR	36.5 \pm 5.6 ^b	34.2 \pm 1.2 ^b
	E+LC+IR	29.7 \pm 1.2 ^b	36 \pm 0.71 ^b
AST (IU/L)	Control	150.3 \pm 4.02	149.3 \pm 3.4
	IR	404 \pm 18.3 ^a	149.8 \pm 25.2
	LC+IR	97.7 \pm 7.5 ^{ab}	157.2 \pm 6.5
	E+LC+IR	97.7 \pm 4.2 ^{ab}	159.7 \pm 6.7
Bilirubin (mg/dL)	Control	0.1 \pm 0.0	0.1 \pm 0.0
	IR	0.17 \pm 0.02	0.1 \pm 0.0
	LC+IR	0.1 \pm 0.0	0.15 \pm 0.03
	E+LC+IR	0.2 \pm 0.04 ^a	0.15 \pm 0.03
Albumin (g/dL)	Control	3.6 \pm 0.04	3.6 \pm 0.04
	IR	3.77 \pm 0.08	3.77 \pm 0.09
	LC+IR	3.35 \pm 0.11	3.77 \pm 0.11
	E+LC+IR	3.2 \pm 0.11	3.67 \pm 0.16

DISCUSSION

In this research work, the co-supplementation of vitamin E (VE), an antioxidant, with L-carnitine (LC) were evaluated to decrease the damaging effects in rat exposed to irradiation.

Liver of irradiated rat treated with LC alone versus LC and VE for 5 consecutive days prior to irradiation (6 Gy), showed less degenerative changes of hepatic tissues, edema and leukocyte infiltration than the irradiated group without any pre exposure supplements, also Co-supplementation of VE and LC had more beneficial effects than LC alone. This was supported by biochemical marker of liver, by improving levels of liver enzymes in both LC alone and LC&VE supplementation. Results of our study is in a harmony with Sally and her colleague ⁽⁹⁾, who investigated the radio protective efficacy of L - carnitine (LC) and α - Lipoic acid (LA) on radiation-promote liver damages in a rat model, the liver sections of the treated rats showed a hepatic architecture with no abnormalities. Also Demiroren with his colleagues ⁽¹⁰⁾; concluded that A significant protective effects of L-carnitine, N-acetylcysteine and genistein on liver fibrosis induced by carbon tetrachloride CCl₄ by improving ALT and AST levels. Also concluded a therapeutic effect on liver fibrosis by N-acetylcysteine and genistein, as well as L-carnitine has a preventive effect on liver pathology. Also Hepatotoxicity induced by chemotherapeutic agent in management of liver cancer could be reduced by L-carnitine (LC) without affecting its anti-cancer therapeutic efficacy which evaluated by reducing liver enzymes as reported by Hashemi and his colleagues ⁽¹¹⁾.

Spleen; in the present study, spleen of irradiated rat treated with LC alone versus LC and VE for 5 consecutive days prior to irradiation (6 Gy), showing less depletion of lymphoid tissue and less splenic tissue necrosis, this result supported by (Mohamed and Farghaly) ⁽¹²⁾, who reported that L-carnitine induced an increased glutathione level in both cardiac and spleen

tissues which is obviously associated with decrease in lipid peroxidation in the same tissue in male mice exposed to fractionated dose of 6 Gy, also L-carnitine has a potential effect of washing out reactive oxygen species (ROS) related to radiation exposure and protect cells from per oxidative stress.

Intestine; histopathological examination showed less mucosal ulceration, submucosal edema and inflammatory cell infiltrate in irradiated rat treated with LC alone versus LC and VE for 5 consecutive days prior to irradiation (6 Gy), this results in agreement with (Caloglu, *et al.*) ⁽¹³⁾; who reported that radiation-promote degenerative damage was definitely higher in the RT group, a radio protective effect of amifostine against all histopathological changes in small intestinal tissue was concluded; however LC has limited radio protective effects regarding vascular damage post radiation exposure. Also Akpolate and his colleagues ⁽¹⁴⁾ reported that ibuprofen and L-carnitine after oral administration had a protective effect by decreasing the severity of radiotherapy-induced duodenal mucosal injury in histopathological evaluation. L-carnitine significantly reduced the radiation induced histopathological damage caused to the colonic mucosa in rats and had a preventive effect on radiation colitis as reported by (Tas *et al.*) ⁽¹⁵⁾.

Finally, we concluded that co-supplementation of L carnitine and vitamin E drugs had a radio protector effect and improve radiation induced damage to the liver, spleen and intestine, but more significant and evident in liver tissue and its enzyme improvement which were supported by others.

Conflicts of interest: Declared none.

REFERENCES

1. Parihar VK, Dhawan J, Kumar S, Manjula SN, Subramanian G, Unnikrishnan MK, Mallikarjuna, Rao C (2007) Free radical scavenging and radioprotective activity of dehydrozingerone against whole body gamma irradiation in Swiss albino mice. *Chem Biol Interact*, **170**: 49–58.

2. Boerma M and Hauer Jensen M (2011) Preclinical research into basic mechanisms of radiation- induced heart disease. *Cardiology Research and Practice Journal*, **8**: 1-8.
3. Wang Z, Li Z, Ye Y, Xie L, Li W (2016) Oxidative stress and liver cancer: etiology and therapeutic targets, oxidative medicine and cellular longevity, review article, *Oxidative Medicine and Cellular Longevity*, Identify its volume by year of publication, article ID and number of pages = 10
4. Tasl S , Faruk Ozkan O, Cikman O, Kiraz A, Akgun Y, Karaayvaz M (2016) L-carnitine has a protective effect on the colonic mucosa during abdominopelvic radiotherapy in rats. *Acta Cirúrgica Brasileira*, **31(9)**: 615-620.
5. Dawson LA, Ten Haken RK, Lawrence TS (2001) Partial irradiation of the liver. *Semin Radiat Oncol*, **11**: 240-246.
6. Hauer Jensen M, Fink LM, Wang J (2004) Radiation injury and the protein C pathway. *Crit Care Med*, **32(5)**: 325-30.
7. Malaguarnera M, Risino C, Gargante MP, Oreste G, Barone G, Tomasello AV, Costanzo M, Cannizzaro MA (2006) Decrease of serum carnitine levels in patients with or without gastrointestinal cancer cachexia. *World J Gastroenterol*, **12(28)**: 4541-5.
8. Graziano F, Bisonni R, Catalano V, Silva R, Rovidati S, Men-carini E, Ferraro B, Canestrari F, Baldelli AM, De Gaetano A, Giordani P, Testa E, Lai V (2002) Potential role of levocarnitine supplementation for the treatment of chemotherapy-induced fatigue in non-anaemic cancer patients. *Br J Cancer*, **86(12)**: 1854-7.
9. Sally S Alam, Aziza M, Hassan, Nermin El-Halawany, Dalia E. El-Nashar, Mona G. Abd El-Azeem (2010) Radioprotective activity of L- Carnitine and α -Lipoic acid against whole body γ - irradiation in rats. *Journal of American Science*, **6(12)**: 865-879.
10. Demiroren K, Dogan Y, Kocamaz H, Ozercan I. H, Ilhan S, Ustundag B, Bahcecioglu I. H (2014) Protective effects of L-carnitine, N-acetylcysteine and genistein in an experimental model of liver fibrosis. *Clin Res Hepatol Gastroenterol*, **38(1)**: 63-72.
11. Hashemi A, Souzani A, Meshkani M, Osia S, Shahvazian N, Keshavarzi Sm Atefi A (2011) Efficacy of L-carnitine on liver function in children's under chemotherapy with acute lymphoblastic leukemia. *Iranian Journal of Pediatric Hematology Oncology*, **1(2)**: 43-47.
12. Mohamed NE and Farghaly AA (2009) Evaluation of the protective effect of L-carnitine on radiation induced free oxygen radicals and genotoxicity in male mice. *Researcher*, **1(6)**: 7-15.
13. Caloglu M, Caloglu VY, Yalta T, Yalcin O, Uzal C (2012) The histopathological comparison of L-carnitine with amifostine for protective efficacy on radiation-induced acute small intestinal toxicity. *Journal of Cancer Research and Therapeutics*, **8(2)**: 260-265.
14. Akpolat M, Topcu-Tarladaçalışır Y, Dokmeci D, Turan FN, Uzal MC (2011) Protective Effects of Ibuprofen and L-Carnitine Against Whole Body Gamma Irradiation-Induced Duodenal Mucosal Injury. *Balkan Med J*; 28: 80-85
15. Tas I S , Faruk Ozkan O, Cikman O, Kiraz A, Akgun Y, Karaayvaz M (2016) L-carnitine has a protective effect on the colonic mucosa during abdominopelvic radiotherapy in rats, *Acta Cirúrgica Brasileira*, **31(9)**: 615-620.

