

Effects of Pentoxifylline on the healing of irradiated wounds in pig skin

M. Rezvani*, G.A. Ross, K. Lamb, J. H. Wilkinson

Research Institute (University of Oxford) Churchill Hospital, Oxford. OX3 7LJ, UK

ABSTRACT

Background: This study was designed to investigate the efficacy of Pentoxifylline (PTX) in the treatment of irradiated wounds.

Materials and Methods: Ten female pigs of the Large White strain were used in these investigations. Six skin fields, 4 x 4 cm and separated from each other by 4 cm, were marked out on each flank and those on left flank were irradiated with 18Gy single dose of 250 kV X-rays. The animals were then randomly allocated to one of three groups. Ten weeks after irradiation a 2'2cm surgical wound was produced, by removing the skin up to fascia level, at the centre of the original skin fields. This was done on both irradiated (left flank) and unirradiated control (right flank) fields. Two groups of animals were treated by daily oral gavaging, with 13.3mg/kg/day PTX dissolved in 10 ml water while a group of control animals received only 10 ml water by oral gavage as placebo. PTX treatment started either two weeks prior to wounding or at the day of wounding. The progression of the healing of excision wounds were evaluated periodically by assessment of wound contraction.

Results and Conclusion: Overall, irradiated wounds healed much slower than unirradiated wounds. While PTX treatment had no effect on the healing rate of unirradiated wounds it appeared that treating the animals with PTX delayed the healing of irradiated wounds. This was true whether PTX treatment started two weeks prior to or at the time of wounding.

Key words: X-Irradiation, wound healing, Pentoxifylline, pig skin.

INTRODUCTION

I ncreasing experimental and clinical evidence supports the effectiveness of Pentoxifylline (PTX) in the treatment of radiation injury; particularly late effects of radiation (Dion et al. 1989, Dion et al. 1990, Gottlöber et al. 1996, Futran et al. 1997, Delanian 1998). Since ionising radiation is frequently used in combination with surgery in the treatment of cancer and radiation accident patients may suffer from trauma as well as radiation injury it is important to investigate the efficacy of PTX in the treatment of radiation lesions combined with surgery or trauma.

This paper reports on the efficacy of PTX in combination with radiation and surgery in an irradiated wound model.

MATERIALS AND METHODS

Ten female pigs of the Large White strain were used in these investigations. Animals were brought into the Animal House when they were approximately 12 weeks of age (weight 20-25 kg) and allowed an acclimatisation period of two weeks before any experimental procedures were undertaken. All experimental procedures were carried out with the animals under anaesthesia, maintained with a 2% halothane, ~30% nitrous oxide, and ~70% oxygen mixture (Dickinson and Hubbard 1990). The animals were maintained, and all experimental procedures performed in compliance with the Animal (Scientific Procedures) Act 1986.

* **Corresponding author:**

Dr. M. Rezvani, Research Institute (University of Oxford)
Churchill Hospital, Oxford. OX3 7LJ, UK. Fax: +44-1865
225847

E-mail: mohi.rezvani@resin.ox.ac.uk

Prior to X-irradiation the hair on the flanks of the animals was clipped and six fields, 4 x 4 cm and separated from each other by 4 cm, were marked out on each flank. Two weeks after planning, the fields on the left flank of the animals were irradiated with 18Gy single dose of 250 kV X-rays at a dose-rate of 1.4Gy/min from a machine operating at 14mA, with 0.5 mm Cu and 1 mm Al added filtration, half value layer of 1.32 mm Cu. For irradiation a Perspex- ended applicator was used. The focus skin distance (FSD) was 50 cm and a 4 mm lead cut-out was employed to protect the adjacent tissue. This dose of X-rays normally produces impairment of blood flow with minimum risk of the development of ischaemic dermal necrosis in this animal model (Hopewell and Young 1982). Skin sites on the right flank were used as unirradiated controls.

The animals were then randomly allocated to one of three groups (I-III); Groups I and II consisted of three pigs each and group III consisted of four pigs. Ten weeks after irradiation a 2.2cm surgical wound was produced, by removing the skin up to fascia level, at the centre of the original skin fields. This was done on both irradiated (left flank) and unirradiated control (right flank) fields. Then the wounds were dressed with an application of Metrotop (0.8% metronidazole, Second Healthcare, UK). Dressing the wounds was carried out twice weekly until the wounds were completely healed. Surgical procedures were carried out under deep halothane anaesthesia and all animals received an intramuscular injection of Temgesic (0.3mg buprenorphine, Reckitt& Colman, UK) at the end of the procedure and following day. Two groups of animals (groups II and III) were treated, by daily oral gavaging, with 13.3mg/kg/day PTX dissolved in 10 ml water and the control animals (group I) received only 10 ml water by oral gavage as placebo. PTX treatment started two weeks prior to wounding (Group II) or at the day of wounding (group III), respectively. In every event, PTX treatment continued until the wounds were healed. Animals in group I received no PTX

treatment.

The progression of the healing of excision wounds were evaluated periodically by assessment of wound contraction. This was achieved by tracing wound area onto tracing paper once a week. Wound area was quantified by a digitiser.

RESULTS

The average area of wound against time after wounding in both irradiated and unirradiated fields are shown in **figure 1**. Overall, irradiated wounds healed much slower than unirradiated wounds. There was a distinct difference in the shape and the healing pattern of irradiated and unirradiated wounds. The area against time after wounding in unirradiated wounds follow a biphasic shape with complete closure time of 21-28 days. However, the area against time after wounding in irradiated wounds follow an almost straight line with complete closure time of 42 days. These wounds healed with a constant rate but much slower than the unirradiated wounds in the same animals. Mean healing time, the time required for 50% of the wounds to heal, was 23.3 ± 0.8 days for the unirradiated wounds which was significantly ($p < 0.001$) shorter than the mean healing time of 34.2 ± 1.7 for the irradiated wounds. A more representative indicator of the wound healing, the ratio of the area under the

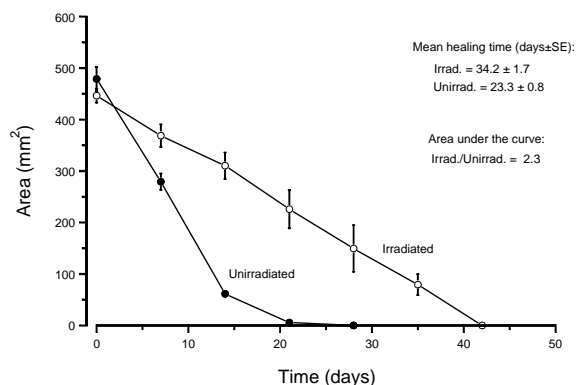


Figure 1. Average area of wound against time after wounding in unirradiated (●) and irradiated (○) fields in control animals (Group I). Error bars ±SE.

curve for irradiated wounds over unirradiated wounds, was 2, 3.

The effect of PTX treatment on the healing of irradiated and unirradiated wounds is shown in figures 2, 3. It appeared that PTX not only prevented wound healing but caused gaping of the wounds when given before wounding. **Figure 2** shows that when PTX treatment (13.3mg/kg/day orally) started two weeks prior to wounding the wound area in irradiated fields progressively increased by time to reach over 150% of the original area at two weeks after wounding. However, the rate of healing was much faster than that of the unirradiated wounds between the second and fourth weeks after

wounding. Overall, the ratio of area under the curve was 3.4 indicating the slow healing of irradiated wounds.

When PTX started at the time of wounding (**figure 3**) healing of irradiated wounds was delayed by almost three weeks. However, when the healing process was initiated the rate of healing was comparable to the rate of healing of unirradiated wounds in the same animals. The ratio of the area under the curve (irradiated/unirradiated) was 3.9.

Mean healing time and the ratio of the area under the curve (irradiated to unirradiated) in different treatment groups are given in **table 1**.

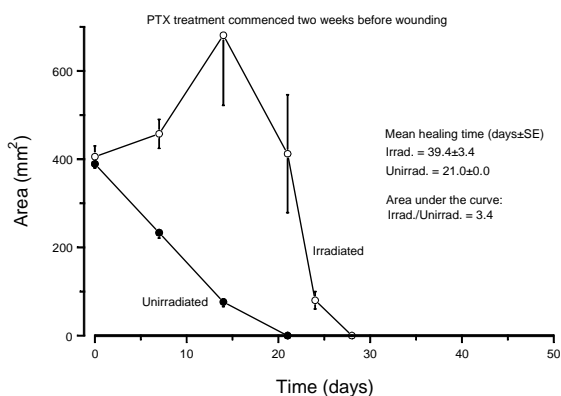


Figure 2. Average area of wound against time after wounding in unirradiated (●) and irradiated (○) fields in animals that received PTX treatment starting two weeks prior to wounding (Group II). Error bars ±SE.

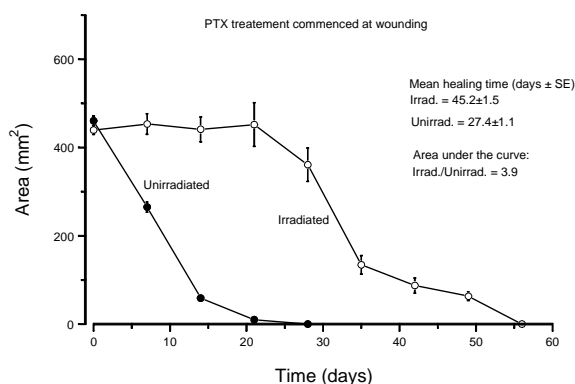


Figure 3. Average area of wound against time after wounding in unirradiated (●) and irradiated (○) fields in animals that received PTX treatment starting at the day of wounding (Group III). Error bars ±SE.

Table 1. Mean healing time and the ratio of the area under the curve (irradiated to unirradiated) as a measure of wound healing in different treatment groups.

	Group I		Group II		Group III	
	Irradiated	Unirrad	Irradiated	Unirrad	Irradiated	Unirrad
Control animals			PTX – 2 wks		PTX – at	
			pre-wounding		wounding	
Mean healing time (days±SE)	34.2±1.7	23.3±0.8	39.4±3.4	21.0±0.0	45.2±1.5	27.4±1.1
Ratio of area under the curve (irrad./unirrad.)	2.3		3.4		3.9	

DISCUSSION

There are marked differences in the anatomy and structure of the skin of fixed skin species such as pig and human and loose skin animals such as rodent species, and these differences influence the response of the skin to wounding and radiation. In fixed skin animals, the vascular supply to the dermis is largely via a series of segmental arteries, each of which supplies a relatively small area of skin. These vessels (perforating vessels) pass through the deep muscular fascia and subdivide at the junction of the fat and dermis, the deep dermal plexus. From this plexus, vessels supply the subcutaneous fat and the skin appendages. Other major vessels cross the reticular dermis and divide at the junction of the papillary and reticular dermal layers to form the superficial subpapillary plexus. Arterioles from superficial plexus further divide to smaller vessels to form the capillaries, which loop at the top layer of the dermal papillae. In loose skin animals, although the deep muscular fascia is supplied by segmental arteries, the dermis is independently supplied via direct cutaneous arteries. Pig skin, due to these anatomical similarities to human skin, provides a very good model to study the process of wound healing and development of radiation injury; particularly late effects of irradiation.

Irradiated wounds in all animals healed much slower than the un-irradiated wounds. This is in accord with the general view that pre-operative irradiation impairs the healing of the wounds (Tibbes 1997) The comparison of all unirradiated wounds, in both control and PTX-treated animals, revealed that the healing rate and pattern of the unirradiated wounds were comparable and remarkably reproducible in both control and PTX-treated animals (figure 4). This implied that PTX-treatment had no effect on the healing rate of unirradiated wounds in normal pig skin.

Treating the animals with 13.3mg/kg/day PTX clearly affected the rate of healing of

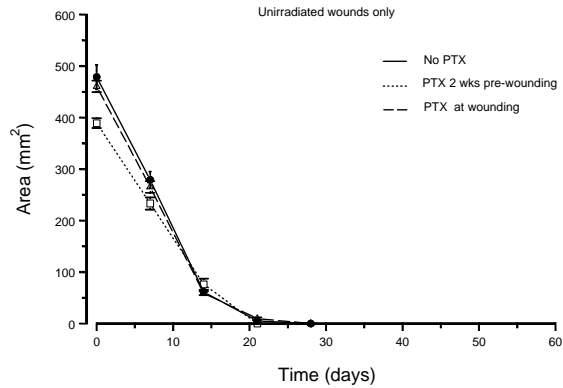


Figure 4. Average area of wound against time after wounding in unirradiated skin fields in control animals (●—●) and those that received PTX-treatment starting 2 wks before wounding (□—□) or at the time of wounding (△—△).

irradiated wounds in all cases (figure 5). The rate of wound closure was steady in control animals that did not receive PTX-treatment. However, in all animals that received PTX-treatment this pattern was altered to an initially delayed and later rapid closure. The biggest effect was seen when the PTX-treatment commenced on the day of wounding. The healing was initially delayed for three weeks with no sign of wound closure. When PTX-treatment started two weeks before wounding wounds

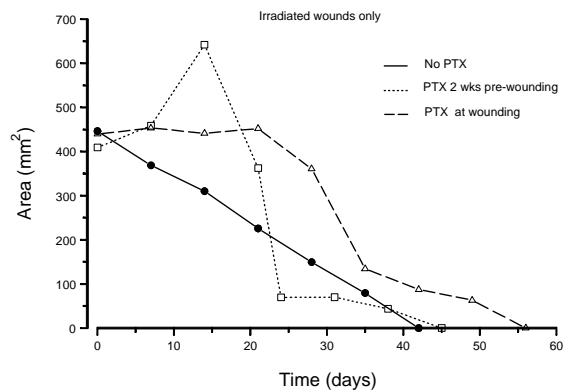


Figure 5. Average area of wound against time after wounding in irradiated skin fields in control animals (●—●) and those that received PTX-treatment starting 2 wks before wounding (□—□) or at the time of wounding (△—△).

gaped even further within the first 2-3 weeks after wounding. However, when the closure of the wound was initiated the rate of closure of irradiated wounds was much faster in PTX treated animals compared with that of control animals. Overall the values of 3.4 and 3.9 were obtained for the ratio of the areas under the curve (irradiated/unirradiated) for irradiated wounds in animals treated with PTX two weeks prior to or at the time of wounding, respectively. These values were significantly greater than the value of 2.3 for control animals. This implied that PTX, an inhibitor of TNF- α , treatment overall delayed the healing of the irradiated wounds. This is in accord with the observations of Lee et al. (2000) who demonstrated that inhibition of TNF- α by TNF-binding protein compromised wound healing.

Pentoxifylline, which is an analogue of the methylxanthine-theobromine, was introduced as a vasoactive drug with significant hemorrheological effects in 1984. PTX has been used for the treatment of vascular disorders, including intermittent claudication, venous stasis ulcers, cerebrovascular insufficiency and hyperviscosity associated with polycythemia (Muller 1979). It has also been used for the treatment of skin disorders such as necrobiosis lipoidica (Noz et al. 1993) cutaneous polyarteritis nodosa (Calderon et al. 1993) and morphea (Wong and Holt 1992). The first study of pentoxifylline on the effects of radiation on cutaneous tissue was in a mouse foot model (Dion et al. 1989) It was reported that pentoxifylline had no effect on acute radiation injury to mouse foot but it demonstrated a significant beneficial effect on the development of late radiation damage. This was followed by further experimental and clinical studies (Dion et al. 1990, Gottlöber et al. 1996, Futran et al. 1997, Delanian 1998) that revealed significant beneficial effects of PTX particularly combined with α -tocopherol in the treatment of radiation injury as a palliative and preventive medicine. However, there is always a possibility, particularly in cases of radiation accidents, that

the patients exposed to radiation suffer from trauma or surgical wounds. The results suggest that administration of PTX might delay the healing of irradiated wounds. It must be noted that this applies only to irradiated wounds as PTX demonstrated no effect in the healing of unirradiated wounds in normal pig skin.

PTX possesses several mechanisms of action. Clinical studies have demonstrated that it lowers blood viscosity by inhibition of platelet aggregation, enhances erythrocyte deformability and tissue oxygenation. It has been shown to inhibit the proliferation of fibroblasts derived from keloids, scleroderma and normal skin. Pentoxifylline also inhibits the production of collagen, glycosaminoglycans and fibronectin by these cells without reducing collagenase activity (Berman and Duncan 1989, Berman and Duncan 1990).

PTX inhibits the production of macrophage and keratinocyte derived cytokines such as TNF- α , IL-1 and IL-6 (Strieter et al. 1988, Sullivan et al. 1988, Bruynzeel et al. 1995). Production of these cytokines is an important step in adhesion molecule activation that is a major component of wound healing. The injured keratinocyte turns on wound healing responses by releasing interleukin-1 (IL-1) that activates endothelial cells causing them to express selectins. These molecules slow down passing lymphocytes and adhere them to endothelial cells. Meanwhile IL-1 draws lymphocytes into the epidermis. IL-1 also activates keratinocytes by binding to their IL-1 receptors. It also activates fibroblasts in the dermis. Activated keratinocytes and fibroblasts migrate, proliferate and secrete extracellular matrix and additional cytokines as part of wound healing process. Activated keratinocytes, besides other cytokines, produce TNF- α that further activates and keeps them in an activated state. TNF- α , predominantly synthesized by macrophages and lymphocytes, increases significantly during the postoperative days following wounding (Vesaluoma et al. 1997, Schäffer et al. 2002). This suggests a role for this cytokine in wound healing for which conflicting reports have been

published. It has been shown that TNF- α down regulates wound healing and application of this cytokine causes decreased collagen deposition in the wound diminishes wound breaking strength and inhibition of its activity promotes wound healing (Schäffer et al.2002, Regan et al. 1993, Bettinger et al.1994). On the other hand TNF- α has been shown to stimulate dermal fibroblast proliferation in vitro (Sugarman et al.1985, Vilcek et al. 1986) and significantly improve the strength and markedly enhanced the inflammation and granulation tissue formation in experimental wounds (Schlenger et al. 1994). In fact administration of exogenous TNF- α has both enhanced and attenuated wound breaking strength (Salomon et al. 1991, Mooney et al. 1990). While limited suppression of TNF- α bioactivity at various time points within the first 7 days after wounding did not have any effect on breaking wound strength continuous suppression of its activity was associated with reduced wound breaking strength in mice (Lee et al. 2000).

Wound healing is a complex response to injury and it requires coordinated integration of cellular, physiologic and biochemical events. Normal healing depends on a well-defined balance of promoting and compromising inflammatory factors. TNF- α appears to be an important mediator in wound healing. A steady rise in TNF- α levels was observed between postoperative days 3-7 in rodent skin (Lee et al. 2000). Suppression by PTX of TNF- α might be an explanation for the delay in initial healing of PTX- treated irradiated wounds in the present study. However, the pattern of closure of PTX-treated wounds (figure 5) suggests that possible suppression of TNF- α by PTX increases the rate of recovery at later stages. This might be an explanation for conflicting results reported on the effects of TNF- α on wound healing. However, the process appears to be important only in irradiated wounds because the healing of unirradiated wounds in both control and PTX-treated animals were the same. While, the exact

mechanism of delayed healing of irradiated wounds by PTX need to be elucidated, this effect of PTX should be taken into consideration in the treatment of radiation injury by PTX in patients bearing wounds, caused by trauma or surgery, on irradiated areas of their body.

REFERENCES

1. Berman B. and Duncan M.R. (1989). Pentoxifylline inhibits normal human fibroblast in vitro proliferation, collagen, glycosaminoglycan and fibronectin production and increases collagenase activity. *J. Inves. Dermatol.*, **92**: 605.
2. Berman B. and Duncan M.R. (1990). Pentoxifylline inhibits the proliferation of human fibroblasts derived from keloid, scleroderma and morphea skin and their production of collagen, glycosaminoglycans and fibronectin. *Brit. J. Dermatol.*, **123**: 339.
3. Bettinger D.A., Pellicane J.V., Tarry W.C., Yager D.R. (1994). The role of inflammatory cytokines in wound healing: Accelerated healing in endotoxin-resistant mice. *J. Trauma.*, **36**: 810.
4. Bruynzeel I, van der Raaij LMH, Stoof TJ, Willemze R. (1995). Pentoxifylline inhibits T-cell adherence to keratinocytes. *J. Invest. Dermatol.*, **104**:1004.
5. Calderon M.J., Landa N., Aguirre A., Diaz-Perez J.L. (1993). Successful treatment of cutaneous PAN with pentoxifylline. *Br. J. Dermatol.*, **128**: 706.
6. Delanian S. (1998). Striking regression of radiation-induced fibrosis by a combination of pentoxifylline and tocopherol. *Brit. J. Radiol.*, **71**: 892.
7. Dickinson F. and Hubbard N. (1990) The Large White female pig in research related to cancer treatment: General husbandry and anaesthesia. *Animal. Technol.*, **41**: 35.
8. Dion M.W., Hussey D.H., Osborne J.W. (1989). The effect of pentoxifylline on early and late radiation injury following fractionated irradiation in C3H mice. *Int. J. Radiat.*

- Oncol. Biol. Phys.*, **17**: 101.
9. Dion W., Hussey D.H., Doornbos J.F., Vigliotti A.P., Wen B.C., Anderson B. (1990). Preliminary results of a pilot study of pentoxifylline in the treatment of late radiation soft tissue necrosis. *Int. J. Radiat. Oncol. Biol. Phys.*, **19**: 401.
 10. Futran N.D., Trotti A., Gwede C. (1997). Pentoxifylline in the treatment of radiation-related soft tissue injury: preliminary observations. *Laryngoscope*, **107**: 391.
 11. Gottlöber P., Korting H., Stock W., Peter R. (1996). Behandlung der kautanen Strahlenfibrose mit Pentoxifyllin und Vitamin E. *Strahlenther Onkol.*, **172**: 34.
 12. Hopewell J.W. and Young C.M.A. (1982). The effect of field size on the reaction of pig skin to single doses of X rays. *Br. J. Radiat.*, **55**: 356.
 13. Lee R.H., Efron D.T., Tantry U., Stuelten C., Moldawer L.L., Abouhamze A., Barbul A. (2000). Inhibition of tumour necrosis factor- α attenuates wound breaking strength in rats. *Wound Rep. Reg.*, **8**: 547.
 14. Mooney D., O'Reilly M., Gamelli R (1990). Tumour necrosis factor and wound healing. *Ann. Surg.*, **211**: 124.
 15. Muller R. (1979). Pentoxifylline, a biomedical profile. *J. Med.*, **10**: 307.
 16. Noz K.C., Korstanje M.J., Vermeer B.J. (1993). Ulcerating necrobiosis *Lipoidica* effectively treated with pentoxifylline. *Clin. Exp. Dermatol.*, **18**: 78.
 17. Regan M.C., Kirk S.J., Hurson M., Sodeyama M., Wasserkrug H.L., Barbul A. (1993). Tumor necrosis factor- α inhibits in vivo collagen synthesis. *Surgery*, **113**: 173.
 18. Salomon G.D., Kasid A., Cromack D.T., Director E., Talbot T.L., Sank A., Norton J.A. (1991). The local effects of cachectin/tumour necrosis factor on wound healing. *Ann. Surg.*, **214**: 175.
 19. Schäffer M., Weimer W., Wider S., Stülten C., Bongartz M., Budach W., Becker H.D. (2002). Differential Expression of Inflammatory Mediators in Radiation-Impaired Wound Healing. *J. Surg. Res.*, **107**: 93.
 20. Schlenger K., Hockel M., Schwab R., Frischmann-Berger R. Vaupel P. (1994). How to improve the uterotomy healing I Effects of fibrin and tumor necrosis factor- α in the rat uterotomy model? *J. Surg. Res.*, **56**: 235.
 21. Strieter R.M., Remick D.G., Ward P.A., Spengler R.N., Lynch J.P., Larrick J., Kunkel S.L. (1988). Cellular and molecular regulation of tumor necrosis factor- α production by pentoxifylline. *Biochem. Biophys. Res. Commun.*, **155**: 1230.
 22. Sugarman B., Aggarwal B., Hass P., Figari I., Palladino M., Shepard H. (1985). Recombinant human tumour necrosis factor- α effects on proliferation of normal and transformed cells in vitro. *Science*, **230**: 943.
 23. Sullivan G.W., Carper H.T., Novick W.J., Mandell G.L. (1988). Inhibition of the inflammatory action of interleukin-1 and tumour necrosis factor (alpha) on neutrophil function by pentoxifylline. *Infect. Immun.*, **56**: 1722.
 24. Tibbs M.K. (1997). Wound healing following radiation therapy: a review. *Radiother. Oncol.*, **42**: 99.
 25. Vesaluma M., Teppo A.M., Gronhagen-Riska C., Tervo T. (1997). Increased release of tumour necrosis factor- α in human tear fluid after excimer laser induced corneal wound. *Br. J. Ophthalmol.*, **1**: 145.
 26. Vilcek J., Palombella, V.J., Henriksen-DeStefano D., Swenson C., Feinman R., Hirai M. Tsujimoto M. (1986). Fibroblast growth enhancing activity of tumour necrosis factor and its relationship to other polypeptide growth factors. *J. Exp. Med.*, **63**: 632.
 27. Wong S.S. and Holt P.J.A. (1992). Generalized morphea and primary biliary cirrhosis: a rare association and improvement with oxypentifylline. *Clin. Exp. Dermatol.*, **17**: 371.