

Intramuscular hemangioma with immature ossification: a case report and literature review

M. Huang^{1*}, Y. Li¹, H. Li², C. Liao¹, X. Luo¹, N. Guo¹

¹Department of Orthopaedics, Air Force Hospital of Southern Theater Command of PLA, Guangzhou, China

²Department of Medical Insurance Office, Air Force Hospital of Southern Theater Command of PLA, Guangzhou, China

► Case Report

ABSTRACT

Intramuscular hemangioma is a rare type of hemangioma. Ossification of an intramuscular hemangioma is even rarer. This study reports the case of a young man admitted to our hospital with complaints of pain and swelling in the right buttock. We were unable to confirm the type of tumor on evaluation of X-ray, ultrasound, magnetic resonance imaging, and needle biopsy examination. The mass was excised and histopathology confirmed the diagnosis of an ossified intramuscular hemangioma with immature ossification. This case report demonstrates that the diagnosis of an immature ossified intramuscular hemangioma should be considered as differential diagnosis in patients presenting with a soft tissue tumor.

Keywords: *Intramuscular hemangioma, ossification, magnetic resonance imaging.*

*Corresponding authors:

Mengquan Huang, M.D.,

E-mail:

mcquery2019@sina.com

Revised: April 2020

Accepted: June 2020

Int. J. Radiat. Res., April 2021;
19(2): 473-477

DOI: 10.29252/ijrr.19.2.473

INTRODUCTION

Hemangiomas are common soft-tissue tumors that occur as a painful, slow-growing mass in the lower extremities. Onset often occurs before the age of 30^(1,2). The incidence of intramuscular hemangioma is very low, accounting for about 0.8% of hemangioma⁽³⁾. The cause of intramuscular hemangiomas is not clear. Some studies have considered causative factors such as traumatic sequelae or congenital factors^(4,5). Calcification of hemangiomas is a relatively common occurrence, but ossified intramuscular hemangiomas are rarely reported, with a total of nine cases⁽⁶⁻¹²⁾. This article reported a rare intramuscular hemangioma with ossification developed in the gluteal region which was not typically displayed on X-ray imaging. The tumor was immature for incompletely calcified during ossification.

Case Report

This study was approved by the ethical committee in our hospital. Informed consent was obtained from the patient in the study. A

20-year-old male patient presented to our hospital with a history of swelling and pain in the right buttock for the past 3 days. Previous trauma or a history of infection before the onset of swelling and pain was denied, and no family history of soft tissue masses was reported. The patient had not sought medical care prior to his presentation at this hospital.

Physical examination revealed a slight intumescence in the upper area of the right buttock. The local skin temperature was slightly elevated, but no clinical evidence of an infection was noted. A mass of approximately 10 × 5 cm, with a rough texture and well defined was palpated. The right hip and lower limbs had normal mobility and sensory function. The neurovascular examination was unremarkable and results from the blood analysis were within the normal ranges.

No significant changes were found in the pelvic radiological examination (*Kodak*, USA) (figure 1). Ultrasound examination (*Hitachi*, Japan) showed a 68 × 23 mm hypoechoic area in the right buttock muscle, and the internal echo was asymmetrical. No obvious abnormal blood

flow patterns were noted inside or around the lesion (figure 2). Non-enhanced magnetic resonance imaging (MRI) (AllTech, China) showed a soft-tissue mass involving the right gluteus minimus and gluteus medius. T1-weighted MRI presented a slight hyperintensity, and T2-weighted MRI exhibited an asymmetrical hyperintensity and a small foliated hypointensity. Twenty milliliters (9.38g) of gadopentetate dimeglumine (Bayer, Germany) was administered intravenously to perform an enhanced MRI scan. The images showed uneven and moderate reinforcement of the lesion (figure 3A, B, C). A needle biopsy (Bard, USA) was performed and the results showed areas of striated muscle tissue, fibrous connective tissue, and inflammatory necrotic tissues possibly due to inflammatory changes. Therefore, no clear diagnostic results were obtained. Positron emission tomography-computer tomography (Siemens, Germany) examination showed a high metabolic lesion in the right gluteal region, possibility indicating a hemangioma or a neurogenic tumor.

Considering the patient's symptoms and

examination results, a benign tumor was suspected as the most likely diagnosis, and surgery for intracapsular excision of the mass was planned. A 15cm long incision was made in the lateral area of the right buttock. After separating the gluteus maximus, a hard, non-encapsulated mass was found infiltrating into the gluteus medius and gluteus minimus. The tumor was completely stripped along the edge and successfully excised (figure 4). The excised mass was sent for pathological examination and the patient received standard post-surgical care.

Pathological examination revealed vascular structures of varying sizes in the striated muscle with thrombopoiesis, thrombus organization, hemosiderin deposition, and focal ossification (figure 5A, B). Immunohistochemistry showed the vasculature cluster of differentiation 31 and 34 were positive. The myoideum desmin and actin were positive while the D2-40 and S-100 were negative. About ten percent of the Ki-67 was positive, and very few P53 were also positive. The pathological diagnosis was ossified intramuscular hemangioma.

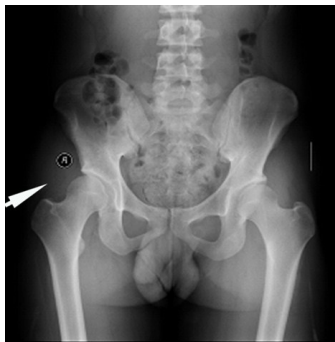


Figure 1. X-ray examination showed no obvious ossification of the right buttock.

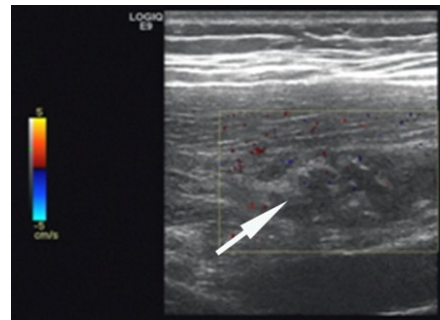


Figure 2. Ultrasound examination showed a asymmetrical low echo area in the right buttock muscle, and no obvious abnormal blood flow signals inside and around the lesion.

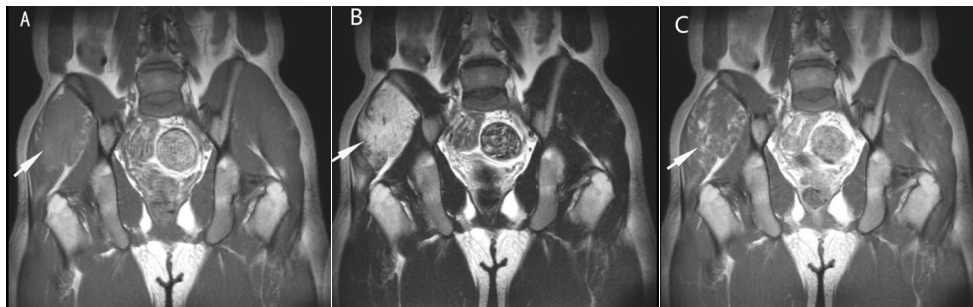

Figure 3. MR findings of the lesion. A. T1 weight MR presented slight hyperintensity. B. T2 weight MR exhibited asymmetrical hyperintensity and small foliated hypointensity. C. Enhanced MRI scan showed uneven and moderate reinforcement of the lesion.

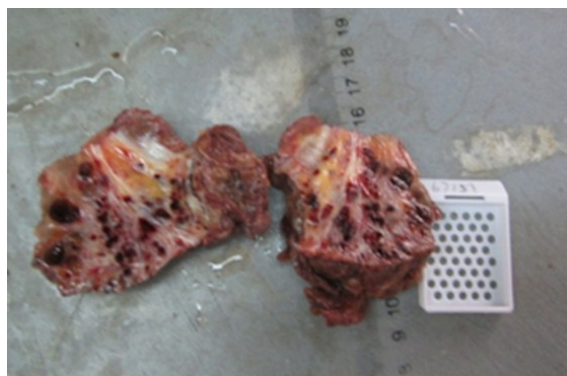

Figure 4. Gross appearance of the specimen.

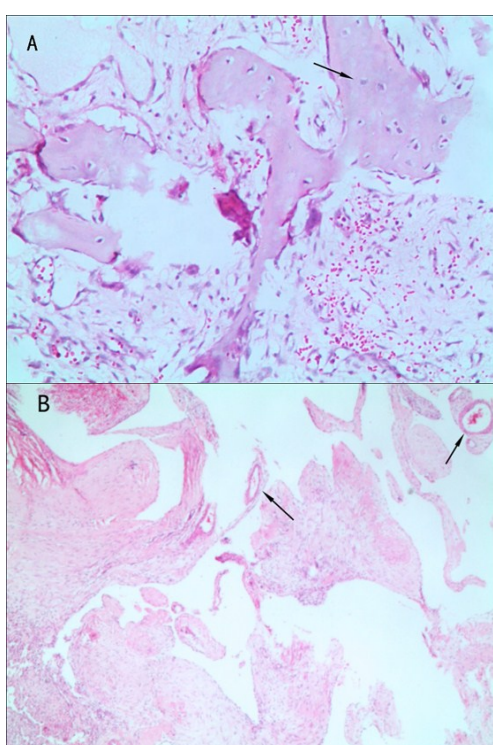


Figure 5. Histologic findings of the lesion. **A.** The ossified tissue is displayed under a 100× microscope. **B.** Many blood vessels were displayed under a 25×microscope.

DISCUSSION

In 1963, Bishop first reported a case of ossified intramuscular hemangioma that occurred in a patient's lower extremities (13). Engelstad *et al.* (7) described the imaging and pathological morphology of this rare hemangioma. Previous research has presented cases of ossified intramuscular hemangiomas located in the thigh or cruris regions. In these cases, mature ossification of the intramuscular

hemangiomas was noted at the time of presentation in a medical setting (6-12). The tumor in this case occurred in the gluteal region, and had low density of ossification. Review of the literature demonstrated that this presentation was rare as no similar cases had been reported in the past.

An intramuscular hemangioma can clinically manifest as localized pain, progressively increasing limb circumference, limb swelling, or skin temperature elevation. Some cases present accompanied by skin pigment discoloration or dilated veins (14). A partially ossified intramuscular hemangioma may also affect muscle contraction leading to joint dysfunction (11). In most cases, significant masses can be palpated. These symptoms may persist for a long period of time before a diagnosis is made.

The typical X-ray manifestation of an ossified intramuscular hemangioma is the "Swiss chess" appearance which is caused by irregular ossification of soft tissue (7). This reflects the distribution of mature ossification along large cavernous vascular channels. Differential diagnoses for these X-ray findings include myositis ossificans, extraskeletal osteosarcoma, ossifying fibromyxoid tumor of soft parts, and fibrodysplasia ossificans. The ossification of myositis ossificans occurs mainly in the peripheral area of the mass, characterized by "zonal phenomenon" that occurs in the advanced stage of the lesion. Extraskeletal osteosarcoma presents as progressively enlarged lesions, showing a large number of mineralized spots on X-rays and computed tomography scans. The ossification region of fibromyxoid tumor is often small in the soft parts and mostly located at the periphery of the lesion (15). Fibrodysplasia ossificans is rare and mostly appears in the soft tissues of the back, shoulders, and upper extremities, accompanied by digit deformities (16). However, in this case, X-ray examination did not show significant ossified lesions suggesting due to the low density of ossified tissue. Thus, the imaging characteristics were significantly different from those of a typical ossified intramuscular hemangioma as previously reported.

On MRI, an ossified intramuscular

hemangioma shows intermediate signal change on T1-weighted images, a high signal on T2-weighted images, and serpentine blood vessels within the lesion. Significant uneven enhancement can be observed in the enhanced scan (17). Due to ossification within the lesion, there is a region of patchy hypointensities on the T1-weighted and T2-weighted images. The signal of the hemangioma component in the lesion is strengthened on enhanced MRI only (9). These findings are consistent with the presentation of this case.

CT scans show an increase in irregular density in the lesions of ossified intramuscular hemangiomas, combined with ossification. Enhanced CT scans do not show enhanced signal in the lesions (9). In some cases, tumors may be surrounded by an area of reduced density while the tumor itself has an irregular high density. This may be due to a reduction of adipose tissue surrounding the tumor, which is consistent with the MRI and histological examination findings (7). Previous studies have reported that the ossified intramuscular hemangioma can be expressed as regional radioactive material (^{99m}Tc) accumulation in the lesion (7,8).

Sonographic examination of immature ossified intramuscular hemangiomas reveals a complex structure with indistinct boundaries between the hyperechoic and hypoechoic regions. Color Doppler ultrasound images show excessive blood vessel in the tumor with abnormal low-resistance arterial signals flowing forward during both the systolic and diastolic phases (18). Jin *et al.* (12) reported a sonographic appearance of an intramuscular hemangioma with ossification. In that study the peripheral hyperechoic part of the mass was associated with reactive hyperplasia of adipose tissue. The intratumoral hypoechoic part may be present due to the dilated lumen of the blood vessels. The hypoechoic part present as smooth muscle and fibrous tissue without rich-blood vessels, and the varied echogenicity may be due to the presence of a large number of irregularly shaped bone islands within the tumor. These bone islands are areas of interstitial fibrosis, distinguishable from the venous stones that appear in the dilated lumen of the vessel.

In conclusion, the diagnosis of an immature ossified intramuscular hemangioma, while partially assisted by MRI examination, was not easily made through any form of imaging. Therefore, the diagnosis of this type of ossified intramuscular hemangioma should be considered as differential diagnosis in patients presenting with a soft tissue tumor.

Disclosure of potential conflicts of interest

Funding: There is no funding source.

Conflict of Interest: The authors declare that they have no conflict of interest.

Ethical approval: All procedures performed in studies involving human participants were in accordance with the ethical standards of the institutional and/or national research committee.

Conflicts of interest: Declared none.

REFERENCES

1. Ly JQ, Sanders TG, Mulloy JP, Soares GM, Beall DP, Parsons TW, Slabaugh MA (2003) Osseous change adjacent to soft-tissue hemangiomas of the extremities: correlation with lesion size and proximity to bone. *Am J Roentgenol*, **180**: 1695-1700.
2. Jenkins HP and Delaney PA (1932) Benign angiomatous tumors of skeletal muscles. *Surg Gynecol Obstet*, **55**: 464-480.
3. Wild AT, Raab P, Krauspe R (2000) Hemangioma of skeletal muscle. *Arch Orthop Trauma Surg*, **120(3-4)**: 139-143.
4. Scott JE (1957) Haemangiomas in skeletal muscle. *Br J Surg*, **44(187)**: 496-501.
5. Chaudhary N, Jain A, Gudwani S, *et al.* (1998) Intramuscular haemangioma of head and neck region. *J Laryngol Otol*, **112(12)**: 1199-1201.
6. Jiang TT, Cisa J, Desai P, Present D (1995) Intramuscular ossified hemangioma. *Skeletal Radiol*, **24(7)**: 538-540.
7. Engelstad BL, Gilula LA, Kyriakos M (1980) Ossified skeletal muscle hemangioma: radiologic and pathologic features. *Skeletal Radiol*, **5(1)**: 35-40.
8. Hoag GN, Murphy MM, Major PA (1984) Ossified skeletal muscle angioma: report of two cases. *J Surg Oncol*, **25(1)**: 34-37.
9. Nagira K, Yamamoto T, Marui T, Akisue T, Yoshiya S, Kurosaka M (2001) Ossified intramuscular hemangioma: Multimodality imaging findings. *Clin Imag*, **25(5)**: 368-372.

10. Brinda MA, Manjunath S, Balasubrahmaniya KS, Manjunath RD, Nanjaiah B (2015) Intramuscular Ossified Hemangioma: A Rare Case Report. *J Clin Diagn Res*, **9(9)**: PD19-21.
11. Jamshidi K, Jafari D, Ramezan Shirazi M, Pahlevansabagh A, Shoushtaryzadeh T (2014) An Unusual Presentation of Ossified Intramuscular Hemangioma: a Case Report. *Acta Med Iran*, **52(4)**: 319-322.
12. Jin W, Kim GY, Lee JH, Yang DM, Kim HC, Park JS, Ryu KN (2008) Intramuscular hemangioma with ossification: emphasis on sonographic findings. *J Ultrasound Med*, **27(2)**: 281-285.
13. Bishop BWF (1936) Hemangioma of voluntary muscle. *Br J Surg*, **24(93)**: 190-191.
14. Ferguson IL (1972) Hemangiomata of skeletal muscle. *Br J Surg*, **59(8)**: 634-637.
15. Schaffler G, Raith J, Ranner G, Weybora W, Jeserschek R (1997) Radiographic appearance of an ossifying fibromyxoid tumor of soft parts. *Skeletal Radiol*, **26**: 615-618.
16. Smith R (1998) Fibrodysplasia (myositis) ossificans progressive. Clinical lessons from a rare case. *Clin Orthop*, **346**: 7-14.
17. Greenspan A, McGahan JP, Vogelsan P (1992) Imaging strategies in the evaluation of soft-tissue hemangiomas of the extremities: correlation of the findings of plain radiography, CT, MRI, and ultrasonography in 12 histologically proven cases. *Skeletal Radiol*, **21**: 11-18.
18. Derchi LE, Balconi G, De Flaviis L, Oliva A, Rosso F (1989) Sonographic appearances of hemangiomas of skeletal muscle. *J Ultrasound Med*, **8**: 263-267.

