

# Structural evaluation of Parotid gland in post radiotherapy oral cancer patients: A prospective study

X. Hao<sup>1</sup>, C. Zhang<sup>1</sup>, X. Lv<sup>2\*</sup>

<sup>1</sup>Department of Imaging, Yuncheng Central Hospital, Yuncheng, Shanxi Province, 044000, China

<sup>2</sup>Department of Medical Imaging, Linfen Central Hospital, No. 17 Jiefang West Road, Linfen, Shanxi Province, 041000, China

## ABSTRACT

**Background:** To evaluate structural variation of the parotid gland in post-radiotherapy oral carcinoma patients. **Material and Methods:** 52 patients (33 males, 19 females) with histologically confirmed cancer of head and neck region were enrolled. All the patients underwent intensity modulated radiotherapy (IMRT) with linear accelerator. A quantitative analysis was conducted with the help of contrast enhanced computed tomography (CECT) scan regarding the changes in the volume and density of the parotid glands (PGs) along with the assessment of their interrelationship in relation to the mean dose applied to the glands. The evaluations were done immediately after radiotherapy, and after 2 and 3 years. **Results:** Parotid size reduction was observed in 77.77 % of cases immediately after radiotherapy with a mean dose of 26.66 Gy applied to the parotid glands. Parotid shrinkage reduced to 61.5 % cases three years post radiotherapy. High density changes were revealed by 69.2 % cases immediately after radiotherapy with a mean dose of 34.53 Gy applied to these parotid glands. Low density changes were revealed by 48.1 % cases after 2 years follow up which further reduced to 25 % at three years follow up. **Conclusion:** There was evidence of structural variation in the PGs during the course of IMRT which was significantly related with the mean dose applied to them. There were high density changes and low density changes immediately after radiotherapy and 2-3 years post-radiotherapy respectively. Further there was volumetric shrinkage post-radiotherapy which shows recovery 2 and 3 years post-radiotherapy.

**Keywords:** Radiotherapy, oral cancer, IMRT, parotid gland density, parotid gland size, xerostomia.

## ► Original article

### \*Corresponding authors:

Xiaobo Lv, Ph.D.,

E-mail: [lxdbjlzy@sina.com](mailto:lxdbjlzy@sina.com)

Revised: September 2020

Accepted: December 2020

Int. J. Radiat. Res., July 2021;  
19(3): 521-529

DOI: 10.18869/acadpub.ijrr.19.3.521

## INTRODUCTION

It is a well-known fact that oral health is considered an important prognostic marker for the overall health of an individual. Saliva plays an important role in maintaining the oral health. Majority of the salivary secretion is contributed by the PGs. These are the largest salivary glands and are located at the pre-auricular region<sup>(1-5)</sup>. It is quite unfortunate that incidence of oral cancer is on rise. It can be treated with surgery or radiotherapy. The high relative radio sensitivity of these oral tumours along with their anatomical location leads to successful

management of these oral tumours by radiotherapy<sup>(5,6)</sup>.

However radiotherapy leads to various side effects, it is still considered as an important treatment modality for maxillofacial carcinoma patients<sup>(1-10)</sup>. Persistent xerostomia is one of the side effects due to radiation exposure and subsequent damage to parotid and submandibular salivary glands. It eventually degrades the quality of life of the patient as it hampers mastication and swallowing in long term survivors<sup>(1,7,8)</sup>. This is attributed to close proximity of these glands to the target volume of head and neck cancers leading to different

grades of xerostomia followed by inducing dysphagia, dysgeusia, caries, and periodontitis<sup>(5, 6,9,10)</sup>. Henceforth sparing of the salivary glands during the radiotherapy procedure is considered as an important research field in the treatment of malignancies of maxillofacial region<sup>(2,11-13)</sup>. Literature reveals continuous research and development in the introduction of newer techniques involved in this procedure. IMRT is one such advancement which has raised the possibility of sparing the salivary glands when compared to conventional radiotherapy procedure<sup>(3,14)</sup>.

The radiation dose as well as the volume irradiated is the deciding factor towards the subsequent functional change in the parotid glands and other oral structures irradiated.<sup>[15]</sup> Various authors have investigated the effect of Conventional radiotherapy technique in comparison to IMRT on the parotid sparing<sup>(16)</sup>. One of the authors described that after 1 year follow up, symptom of dry mouth was higher in conventional radiotherapy patients (74%) in comparison to IMRT patients (39%)<sup>(2)</sup>.

Eisbruch et al. revealed that a radiation dosage lower than 26 Gy to the parotid gland can spare them from any subsequent functional loss<sup>(2, 17)</sup>. However even after the usage of more advanced 3D CRT or IMRT in unilateral or bilateral maxillofacial carcinoma, a mean radiation dose lesser than 26 Gy to both the parotid glands cannot be sometimes achieved in all the irradiated patients<sup>(2, 18)</sup>. Radiotherapy leads to changes in the morphology and vascularity of the parotid glands which in turn leads to altered functioning of the parotid gland leading to oral dryness<sup>(18)</sup>. The cells of the salivary gland are a type of reverting post mitotic cells which are specialized in function. Their relative radio sensitivity is of intermediate nature. The parenchymal component of salivary glands especially parotid gland is radiosensitive. Henceforth the reduction in salivary secretion is seen within weeks after radiotherapy. Various researchers have used CECT to assess the morphology of head and neck structures and to monitor the response of radiotherapy for treatment<sup>(1)</sup>.

As is evident that radiotherapy is essential

modality in several cases of oral carcinoma, the researchers are continuously working to find out the ways to reduce the morbidity related to radiotherapy protocols. Apart of the fact that a radiation dose of 50 -70 Gy is required for majority of these malignancies<sup>(19, 20)</sup> for curative intent, IMRT is still capable of raising the therapeutic ratio in such patients as compared to conventional radiotherapy. Most of such studies are conducted to evaluate the effect of IMRT on the structural variations of parotid gland up to the completion of radiotherapy cycle or up to one year follow up (Lee *et. al* in 2006)<sup>(21)</sup>. Henceforth this present study was conducted to evaluate the morbidity caused by IMRT on the parotid gland during 3 years follow up.

This present study assessed radiation induced structural changes in the parotid glands up to 3 years. Furthermore this study will also evaluate that whether volumetric shrinkage of parotid glands is permanent or transient after subjecting the patient to parotid sparing type of radiotherapy (IMRT).

## MATERIALS AND METHODS

### Patient sample

A cohort of patient suffering from carcinoma of different sites of the oral cavity was enrolled after taking approval from the institutional ethical committee (Approval No. 202003-1001, Approval committee: Linfen Central Hospital, China). All the patients visited the department from January 2016 to January 2019. The 'Strengthening the Reporting of Observational studies in Epidemiology' (STROBE) guidelines were followed. A total of 61 potentially eligible patients were enrolled to participate in the study. Out of the total 61 patients, 39 were males while 22 were females.

All the included patients were histopathologically confirmed cases of oral carcinoma and were enrolled based on the treatment either with radical radiotherapy or pre-radiotherapy after the opinion and consensus of oncologist. The patients were treated with definitive intensity modulated

Radiotherapy (IMRT) (Elekta Synergy, Sweden) without chemotherapy for oropharyngeal carcinoma as per the consensus of oncologists and radiotherapists. All the enrolled patients underwent contrast enhanced computed tomography scan of head and neck pre and post radiotherapy. Only those cases were included in which one parotid gland was completely spared during intensity modulated radiotherapy. None of the patients received any kind of treatment of the lesion prior to enrolment. Moreover the patients with reduced computed tomography (CT) number owing to increase in the adipose tissue or any other reason were excluded. Further the patients who presented with artefacts in the contrast enhanced computed tomography scan due to dental fillings/ Prosthesis which can hamper the evaluation of PGs were also excluded.

Out of total 61 patients, 4 patients did not gave their consent to be a part of this study, 3 patients were not willing for their treatment with radiotherapy in our hospital. So the remaining 54 confirmed eligible patients were subjected to IMRT.

### Radiotherapy

All the patients received 3-dimensional Intensity modulated radiotherapy (IMRT) with the help of a linear accelerator as it allows the delivery of radiotherapy with more accuracy as compared to conventional protocols. Simulation was done and followed by contouring of the tumour and neighbouring structures with the help of planning software of the machine. Care was taken to preserve the contra lateral parotid gland and to minimize the damage in the ipsilateral parotid gland while still allowing sufficient radiation to tumour cells.

16 of patients were subjected to pre-radiotherapy while 38 patients underwent radical radiotherapy. Radiation was delivered in small fractions according to the treatment scheme. Approximately 2.0 Gy of radiation was given per fraction to the tumour cells in one day. This was followed for 5 days in a week. A total of 26-40 Gy of radiation was applied to the tumour cells in pre-radiotherapy while a total of 50-72 Gy was applied to the tumour cells in radical

radiotherapy protocol. The evaluation was done before the radiation procedure, immediately after the radiotherapy completion and 2 and 3 years later.

Out of the 54 patients, 2 patients did not complete the radiation protocol in a timely manner as they were infrequent with their visits. Henceforth a total number of 52 patients were included in this study out of which 15 patients received pre-operative radiotherapy while 37 patients received radical radiotherapy (figure 1).

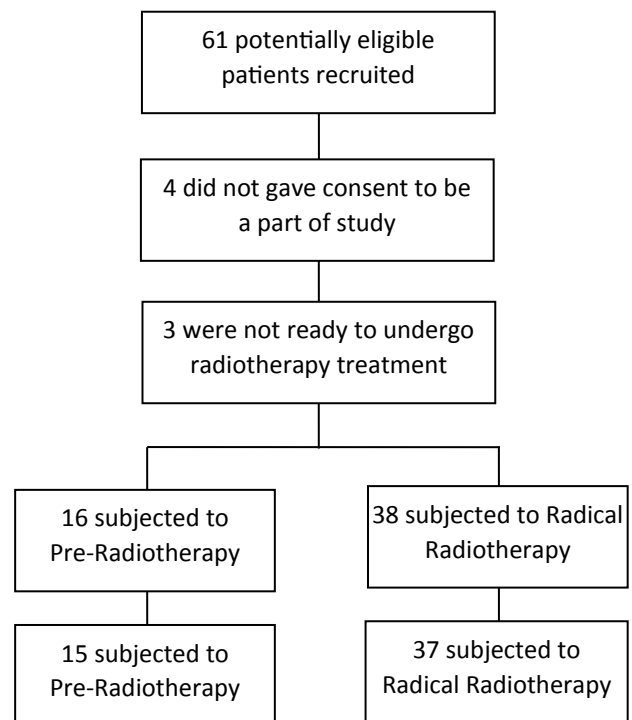
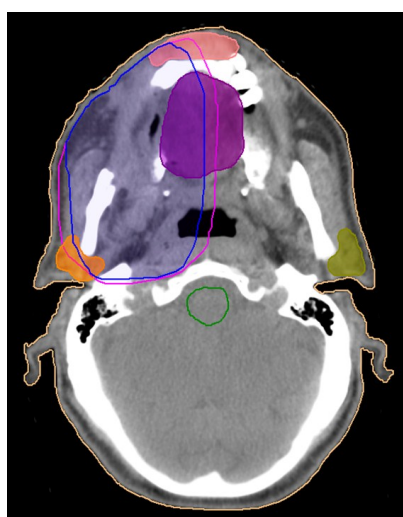
Figure 1. Flow chart for participation.

### Image acquisition and Analysis

The patients were evaluated with the help of contrast enhanced computed tomography performed with the help of -multidetector Computed Tomography scanner (GE Discovery HD750, United States; tube volt-age, 120 kV; tube current, 300 mA; and rotation time, 0.5 s) after injecting with nonionic iodine contrast agent (100 ml). Pre and post radiotherapy contrast enhanced computed tomography scans of all the patients were analysed for density and volume changes in the parotid gland immediately after radiotherapy and 2 and 3 years later with the help of planning software of

the machine (figure 2). Only a single specialized investigator assessed the scans so as to avoid any bias. These changes were correlated with the mean dose applied to parotid glands calculated with the help of 3-dimensional treatment planning system. All the parotid glands were analysed for structural changes i.e. density and volume changes based on Computed Tomography data. Further analysis was also done to evaluate the effect of age, gender and mean dose applied to parotid glands.



**Figure 2.** Patient presenting with carcinoma of right mandible with blue demarcation representing the area affected by malignancy; pink demarcation representing the area of radiation therapy.

### Statistical Analysis

The results were statistically analysed with the help of SPSS software version 17.0 (spss. Chicago, IL). Descriptive statistics were used for the characterization of dosimetric and volume changes of parotid glands. Student T test and Man Whitney U test were used for parametric normally distributed and non-parametric data respectively. A p value less than 0.05 was considered significant. Kolmogorov-Smirnov test was done to assess the normality of the data. Correlations were assessed with the help of Pearson correlation (r value) and Spearman correlation. A p value at the level of 0.01 was considered significant. Analysis of variance was done with the help of Univariate tests to indicate true difference between the studied variables

even after removing the effect of age and gender.

## RESULTS

A total of 52 patients with a mean age of  $51.58 \pm 11.58$  years were evaluated in this study out of which 23 were females and 29 were males with a percentage of 44.2 % and 55.8% respectively. The characteristics like mean age, gender and division of cases on the basis of site of lesion is highlighted in table 1. Students *T*-test reveals that there is no significant difference of mean age of patients in preoperative radiotherapy group and radical radiotherapy group ( $p=0.651$ ). Further Pearson chi square test reveals there was no significant association seen between gender and radiotherapy groups ( $p=0.400$ ) as well as between site of lesion and radiotherapy groups ( $p=0.779$ ) (table 1).

**Table 1.** Patient's characteristics with frequency of Carcinoma of different sites of the oral cavity.

Parameter	Radiotherapy group		Total
	Pre-Op radiotherapy	Radical radiotherapy	
Total number of patients	15 (28.8%)	37 (71.2 %)	52(100%)
Age			
Age range (years)	35-72	29-79	29-79
Mean age (years)	52.73 ± 11.67	51.11 ± 11.67	51.58± 11.58
Student T test (Unpaired)	P value 0.651		
Gender			
Male	7 (24.1%)	22 (75.9%)	29(100%)
Female	8 (34.8%)	15 (65.2%)	23(100%)
Pearson Chi Square test	P value 0.400		
Location of Lesion			
Buccal mucosa	3 (50%)	3 (50%)	6 (100%)
Floor of mouth	3(42.9%)	4(57.1%)	7 (100%)
Mandible	2(25.0%)	6(75.0%)	8 (100%)
Maxilla	2 (28.6%)	5(71.4%)	7(100%)
Nasopharynx	0(0.0%)	1(100.0%)	1(100%)
Retromolar Trigone	2(28.6%)	5(71.4%)	7(100%)
Tongue	3(18.8%)	13(81.3%)	16(100%)
Pearson Chi Square test	P value 0.779		

Out of the total patients enrolled, 15 patients (28.8 %) were subjected to preoperative radiotherapy while 37 patients (71.2 %) were



subjected to radical radiotherapy protocol. The mean radiation dosage applied to the tumour in these patients was  $53.46 \pm 13.61$  Gy. Student's *t*-test revealed that the mean radiation dosage applied to the tumour in radical radiotherapy group ( $61.51 \pm 4.93$  Gy) was significantly higher as compared to Preoperative group ( $33.60 \pm 4.29$  Gy) ( $p=0.000$ ) (table 2). The mean radiation dose received by the parotid glands of all the patients was  $23.29 \pm 11.13$  Gy with a dose range of 2-38 Gy. Student's *t*-test revealed significant difference in the mean radiation dosage received by the parotid gland in radical radiotherapy group ( $29.41 \pm 6.03$  Gy) as compared to preoperative group ( $08.20 \pm 3.85$  Gy) ( $p=0.000$ ).

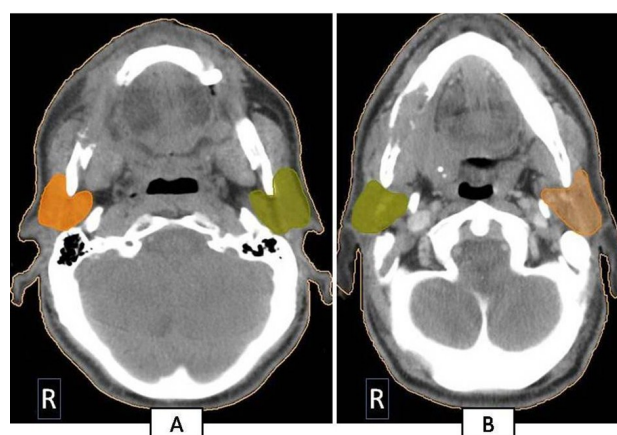
**Table 2.** Mean radiation dose applied and mean Size of parotid gland in pre-op and radical radiotherapy group.

Variables	Radiotherapy	N	Mean $\pm$ Std. Deviation	P value
Dose of radiotherapy (Gy)	Pre op	15	$33.60 \pm 4.290$	0.000
	Radical	37	$61.51 \pm 4.931$	
Radiation Dose to parotid (Gy)	Pre op	15	$8.20 \pm 3.858$	0.000
	Radical	37	$29.41 \pm 6.030$	
Size of parotid gland before radiotherapy (cm <sup>3</sup> )	Pre op	15	$26.733 \pm 4.9117$	0.480
	Radical	37	$27.703 \pm 4.2622$	
Size of parotid gland immediately after radiotherapy (cm <sup>3</sup> )	Pre op	15	$26.067 \pm 4.8118$	0.000
	Radical	37	$20.111 \pm 4.1273$	
Size of parotid gland 2 year post radiotherapy (cm <sup>3</sup> )	Pre op	15	$26.513 \pm 4.8469$	0.007
	Radical	37	$22.816 \pm 4.0996$	
Size of parotid gland 3 year post radiotherapy (cm <sup>3</sup> )	Pre op	15	$26.607 \pm 4.8935$	0.013
	Radical	37	$23.149 \pm 4.1371$	

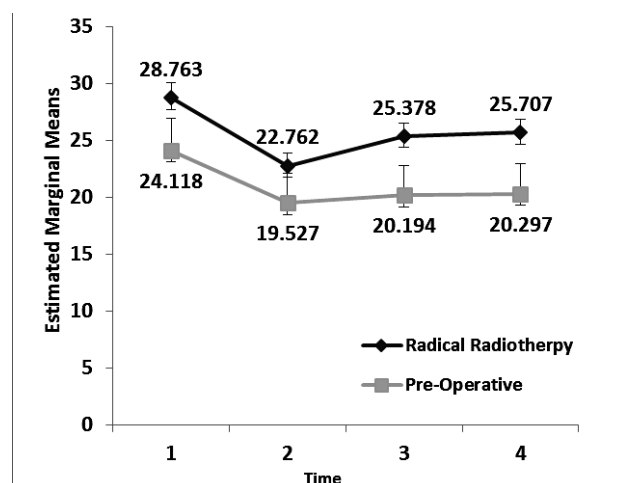
Students *t*-test showed no significant difference in the mean size of parotid glands in preoperative radiotherapy and radical radiotherapy group ( $p=0.480$ ). However, post radiotherapy there was significant difference seen immediately after radiotherapy; 2 years and 3 years after radiotherapy with significant reduction in the size of parotid gland in radical radiotherapy group (table 2).

Parotid Size reduction was observed in 42 (77.77%) of cases immediately after radiotherapy in total (figure 3). Profile Plot for the trend of reduction of size of parotid gland during the course of radiotherapy is shown in figure 4. Shrinkage was not considered if the

size of parotid gland did not reduced at least by 1cm<sup>3</sup>. Out of this, the shrinkage was observed in 4 cases of preoperative radiotherapy while it was seen in 36 cases of radical radiotherapy patients. Only one case of radical radiotherapy did not showed any shrinkage immediately after radiotherapy. The mean dose applied to the parotid gland in the patients who showed shrinkage in the gland was 26.66 Gy as compared to 7.58 Gy applied to the glands with no change in size.



**Figure 3.** CECT simulation picture representing the left and right parotid glands before the initiation of radiotherapy in figure-A while CECT representing reduction in the size of right parotid gland in figure-B post radiotherapy.



**Figure 4.** Profile plot highlighting trend of size of parotid gland during the course of radiotherapy with covariates evaluated at the radiotherapy dose of 53.46 Gy.

The density change in the parotid gland among the radiotherapy groups is shown in

table 3. Parotid shrinkage was observed in 32 patients (61.5 %) three years after radiotherapy with a mean parotid dose of 31.06 Gy which was significantly higher than parotid dose of 10.85 Gy to those 20 parotid glands who didn't showed any significant shrinkage. Out of the patients who showed shrinkage, 19 patients didn't showed any change in the density of parotid gland three years post radiotherapy while 13 patients showed Low density changes. There was significant association seen between density of Parotid gland three year post radiotherapy and Size of parotid gland three year Post Radiotherapy ( $p=0.001$ )

36 patients (69.2%) revealed high density changes on CECT immediately after radiotherapy. The mean dose applied to the parotids with high density changes was 34.53 Gy and to the parotids with no changes in the density was 8.09 Gy. Low density changes i.e fatty degeneration was revealed by 25 parotid glands (48.1%) two years post radiotherapy. Low density changes i.e fatty degeneration was revealed by 13 parotid glands (25.0%) three years post radiotherapy with a mean parotid dose of 35.15 Gy as compared to 19.13 Gy parotid dose which revealed no changes (table 3).

**Table 3.** Density variations in the parotid gland post radiotherapy.

Density variations		Radiotherapy group		Total
		Pre-operative radiotherapy	Radical radiotherapy	
Density of parotid gland immediately after radiotherapy	No change	15	1	16
	Increased	0	36	36
<b>Total</b>		15	37	52
Density of Parotid gland 2 years post radiotherapy	No change	15	12	27
	Low	0	25	25
<b>Total</b>		15	37	52
Density of parotid gland 3 years Post radiotherapy	No change	15	24	39
	Low	0	13	13
<b>Total</b>		15	37	52

Pearson chi-Square (Asymp. Sig. 2-sided) 0.000 (for density of Parotid gland immediately after radiotherapy \* radiotherapy)  
 Pearson chi-Square (Asymp. Sig. 2-sided) 0.000 (for density of Parotid gland 2 year post radiotherapy \* radiotherapy)  
 Pearson chi-Square (Asymp. Sig. 2-sided) 0.008 (for density of Parotid gland three year post radiotherapy \* radiotherapy)

There was significant relationship between volume changes and mean dose applied to the parotid glands. Spearman's correlation reveals negative correlation between Volume changes immediately after radiotherapy, at 2 years and 3 years after radiotherapy with a p value of 0.01, 0.02 and 0.02 respectively.

There was significant relationship between density variations and mean dose applied to the parotid glands. Furthermore, those 16 patients who revealed no density change in the parotid gland immediately after radiotherapy also revealed no change in the density three years post radiotherapy too. However, out of total 36 patients with increased density of parotid gland immediately after radiotherapy; 23 did not revealed any change in the density of the gland 3 years post radiotherapy while the rest 13 revealed low density changes 3 years post radiotherapy. This highlights significant association between density variations and high density changes in the parotid glands immediately after radiotherapy ( $P=0.006$ ).

## DISCUSSION

There is no deny to the fact that Ionizing radiation used in the radiotherapy protocols cause damage to normal tissues in addition to the desired anti-tumour effects <sup>(5,19)</sup>. This becomes more important in the maxillofacial region as it is a complex area constituting different anatomical structures present close to each other <sup>(19)</sup>. Further all these structures respond differently to the radiation dose applied. Salivary gland, especially parotid gland is one of such structures which are considered at risk during radiotherapy of head and neck region.

In this study, a total of 52 patients were enrolled with carcinoma of different regions of the oral cavity (table 1). Since these oral tumours present with ballistically complex geometry, high severity and have different healthy organs like salivary glands close to them, their treatment with radiotherapy is a challenge in terms to avoid the risk of hazardous effects of radiotherapy to these healthy organs

(20).

Several authors have revealed that location and type of malignancy influences the radiation dose needed for treatment. It is also evident that a radiation dose of 50-70 Gy is required for majority of these malignancies for curative intent<sup>(19)</sup>. This was in accordance with this study conducted as the mean radiation dose applied to the tumour in radical radiotherapy was  $61.51 \pm 4.93$  Gy (Range 52-70 Gy) while the mean radiation dose applied in preoperative radiotherapy group was  $33.60 \pm 4.29$  Gy (Range 26-40 Gy). According to Wu VWC *et al.* in 2019, the dose delivered to the primary tumour was 72-76 Gy divided in 7 weeks course<sup>(5)</sup>.

According to Dobbs *et al.* in 1999 and several other researchers, this tumour dose is given at a rate of 2 Gy/day for five days a week. This was followed in this study too<sup>(19)</sup>. The sub lethal DNA damage to normal tissue by the fractionated dose tends to repair faster as compared to the tumour tissue. Henceforth the 2 Gy fractions help to magnify the destruction of tumour cells thus giving time to healthy cells for repair<sup>(19)</sup>.

IMRT was chosen to deliver radiotherapy in this study as it attributes to increased radiation dose delivered particularly to the tumour volume thereby reducing the same to the adjacent healthy tissues<sup>(20)</sup>. Henceforth IMRT can diminish the chances of occurrence of xerostomia thus preserving the parotid gland<sup>(21)</sup>.

The mean volume of parotid glands before radiotherapy and the mean dose applied to the parotid glands of all the patients in this study was in accordance with the study done by Wei *et al.*<sup>[22]</sup> in 2014 and Juan *et al.*<sup>(23)</sup> in 2015 respectively.

Juan *et al.*<sup>(23)</sup> in 2015 revealed that 64 % of the patients suffered from grade 2 xerostomia when they were subjected to radiotherapy with a parotid dose of 50-60 Gy<sup>(23)</sup>. Lee *et al.* in 2006 reveals that although IMRT leads to Xerostomia to some extent, it still shows better chances of recovery after 1 year of follow up<sup>(21)</sup>. Henceforth in this study we tried to evaluate the extent of structural changes in parotid gland 3 years post radiotherapy. In this study, CT with contrast was used to evaluate the structural

changes in parotid glands as CT has been able to detect salivary gland lesions with 100 % sensitivity<sup>(24-26)</sup>. Further plain CT is able to detect entire volume of gland but it is not able to detect parotid ducts. Hence iodinated contrast was used in this study as it will raise the sensitivity of the scan to detect parotid ducts<sup>(24, 27, 28)</sup>.

The parotid volume was lesser immediately after radiotherapy as compared to volume of parotid glands before radiotherapy (table 2). Later the volume increased over 2 years and three years follow up. This was in accordance to the findings of Juan *et al.* in 2015 which revealed that the parotid shrinkage was significant within 100 days, up to 1 year and more than one year post radiotherapy with a volume reduction rate of  $31.2 \pm 13.0\%$ ,  $26.1 \pm 13.5\%$ , and  $17.1 \pm 16.6\%$  respectively ( $P < 0.005$ )<sup>(23)</sup>.

Parotid shrinkage was observed more in cases with radical radiotherapy (97.29%) as compared to Pre-operative radiotherapy group (26.66%). The mean parotid dose was higher in patients with parotid shrinkage. This was in accordance to the other studies conducted in the literature which has even concluded that the mean parotid dose is considered as an important prognostic marker towards parotid shrinkage<sup>(21)</sup>. Nishimura *et al.*<sup>(12)</sup> revealed a significant correlation between the volume loss of parotid glands and radiation dose ( $p = 0.001$ ). They also revealed that the volume of parotid glands reduced to 32 ml from 43.1 ml in the third week of IMRT<sup>(3)</sup>. Further Ogura *et al.* in 2017 also revealed that there were 63.6 % of cases which revealed parotid shrinkage three years post radiotherapy with a mean applied parotid dose of  $46.3 \pm 23.3$  Gy<sup>(1)</sup>. The parotid shrinkage as well as the mean parotid dose was more in the study of Ogura *et al.* as compared to this present study as this present study was conducted with IMRT as compared to Ogura I *et al.* who conducted the study with conventional radiotherapy<sup>(1)</sup>.

Several studies in literature reveal a decrease in parotid gland size at a rate of 0.6-0.7 % per day for head and neck cancers with a total volume loss of 21.3 % at the end of treatment<sup>(24)</sup>. Jin *et al.* in 2013 also revealed same

volume reduction (4.9 % per week)<sup>(29)</sup>. Wang *et al.* in 2009 revealed that average volume loss in parotid gland at the end of radiotherapy treatment was 26.93%<sup>(30)</sup>. It is of interest to note that parotid glands do not reveal any further reduction in the volume after completion of radiotherapy treatment. This was in accordance with the study of Wang *et al.*<sup>(30)</sup> in 2009. Further According to Sim *et al.* in 2018, the salivary glands which earlier showed 33% reduction after completion of radiotherapy, they revealed volumetric recovery after 2 years<sup>(31)</sup>. But this volumetric recovery was still significantly smaller than pre radiotherapy volumes. This was in accordance to the results of this study too.

This study revealed that 69.2% parotid glands revealed high density changes on CECT immediately after radiotherapy with a mean parotid dose of 34.53 Gy. This was in accordance with the study done by Ogura *et al.* which revealed 70.5% high density changes<sup>(1)</sup>. However the mean parotid dose in the patients with high density changes in their study was 46.8 Gy. This could be attributed to the fact that conventional radiotherapy protocol was followed in their study. Further low density changes were revealed by 25% parotid glands three years post radiotherapy with a mean parotid dose of 35.15 Gy. This was also in contrast to the low density changes (72.2%) three years post radiotherapy by the study done by Ogura *et al.* with mean parotid dose of 46.6 Gy<sup>(1)</sup>.

This present study reveals significant relationship between volume/density changes in the parotid gland and mean dose applied to the parotid glands which was in accordance with the other studies conducted in the literature.

### Limitations of the study

This study constituted a small sample size and only structural changes in the Parotid Glands were evaluated. The variation in salivary content and its pH was not evaluated before and after radiotherapy. This could have helped to understand the effect of radiation on the functional status of the irradiated parotid glands. Even the change in the position of the

organs at risk was not considered in this study which can affect dosimetry of the planned radiation treatment.

## CONCLUSION

A part of the fact that IMRT is advanced, it still lead to structural changes in the irradiated PGs depending upon the position of the tumour and radiation dose received by the parotid glands. These structural changes reduce with time. Further there is volumetric shrinkage post radiotherapy which shows recovery with time. These structural variations in the PGs are significantly related to the mean radiation dose received by these glands.

**Conflicts of interest:** Declared none.

## REFERENCES

1. Ogura I, Sasaki Y, Sue TOM, Yamaguchi H, Kameta A, Haya- ma K, Tsuchimochi M (2017) Structural Variations in Pa- rotid Glands Induced by Radiation Therapy in Patients with Oral Carcinoma Observed on Contrast-Enhanced Comput- ed Tomography. *Pol J Radiol*, **82**: 561-566.
2. Hey J, Setz J, Gerlach R, Janich M, Hildebrandt G, Vorder- mark D, Gernhardt CR, Kuhnt T (2011) Parotid gland- recovery after radiotherapy in the head and neck region - 36 months follow-up of a prospective clinical study. *Radia- tion Oncology*, **6**:125.
3. Fiorentino A, Caivano R, Metallo V, Chiumento C, Cozzoli- no M, Califano G, Clemente S, Pedicini P, Fusco V (2012) Parotid gland volumetric changes during intensity- modulated radiotherapy in head and neck cancer. *The British Journal of Radiology*, **85**:1415-1419.
4. Obinata K, Nakamura M, Carrozzo M, Macleod I, Carr A, Shirai S, Ito H (2014) Changes in parotid gland morphology and function in patients treated with intensity-modulated radiotherapy for nasopharyngeal and oropharyngeal tu- mors. *Oral Radiol*, **30**: 135-141.
5. Wu VWC and Leung KY (2019) A review on the assessment of radiation induced salivary gland damage after radio- therapy. *Frontiers in Oncology*, **9**: 2019.
6. Wong FC, Ng AW, Lee VH, Lui CM, Yuen KK, Sze WK, Leung TW, Tung SY (2010) Whole-field simultaneous integrated boost intensity modulated radiotherapy for patients with nasopharyngeal carcinoma. *Int J Radiat Oncol Biol Phys*, **76**: 138-45.
7. Chambers MS, Harden AS, Kies MS, Martin JW (2004) Radi-

*Int. J. Radiat. Res., Vol. 19 No. 3, July 2021*



- ation-induced xerostomia in patients with head and neck cancer: Pathogenesis, impact on quality of life, and management. *Head Neck*, **26**: 796–807.
8. Braam PM, Roesink JM, Raaijmakers CPJ, Busschers WB, Terhaard CHJ (2007) Quality of life and salivary output in patients with head-and-neck cancer five years after radiotherapy. *Radiat Oncol*, **2**: 3.
9. Jellema AP, Slotman BJ, Doornaert P, Leemans CR, Langendijk JA (2007) Impact of radiation-induced xerostomia on quality of life after primary radiotherapy among patients with head and neck cancer. *Int J Radiat Oncol Biol Phys*, **69**: 751–760.
10. Kam MKM, Leung SF, Zee B, Chau RMC, Suen JJS, Mo F, Lai M, Ho R, Cheung KY, Yu BKH, Chiu SKW, Choi PHK, Teo PML, Kwan WH, Chan ATC (2007) Prospective randomized study of intensity-modulated radiotherapy on salivary gland function in early-stage nasopharyngeal carcinoma patients. *J Clin Oncol*, **25(31)**: 4873–4879.
11. Lin A, Kim HM, Terrell JE, Dawson LA, Ship JA, Eisbruch A (2003) Quality of life after parotid-sparing IMRT for head-and-neck cancer: a prospective longitudinal study. *Int J Radiat Oncol Biol Phys*, **57**: 61–70.
12. Nishimura Y, Nakamatsu K, Shibata T, Kanamori S, Koike R, Okumura M, Suzuki M (2005) Importance of the initial volume of parotid glands in xerostomia for patients with head and neck cancers treated with IMRT. *Jpn J Clin Oncol*, **35**: 375–379.
13. Porter SR, Fedele S, Habbab KM (2010) Xerostomia in head and neck malignancy. *Oral Oncol*, **46**: 460–463.
14. Saarilahti K, Kouri M, Collan J, Kangasmäki A, Atula T, Joensuu H, Tenhunen M (2006) Sparing of submandibular glands by intensity modulated radiotherapy in the treatment of head and neck cancer. *Radiother Oncol*, **78**: 270–275.
15. Bekes K, Francke U, Schaller HG, Kuhnt T, Gerlach R, Vordermark D, Gernhard CR (2009) The influence of different irradiation doses and desensitizer application on demineralization of human dentin. *Oral Oncol*, **45**: e80–e84.
16. Nutting CM, Morden JP, Harrington KJ, Urbano TG, Bhide SA, Clark C, Miles EA, Miah AB, Newbold K, Tanay M, Adab F, Jefferies SJ, Scrase C, Yap BK, A'Hern RP, Sydenham MA, Emson M, Hall E (2011) Parotid-sparing intensity modulated versus conventional radiotherapy in head and neck cancer (PARSPORT): a phase 3 multicentre randomised controlled trial. *Lancet Oncol*, **12**: 127–136.
17. Eisbruch A, Ship JA, Martel MK, Ten Haken RK, Marsh LH, Wolf GT, Esclamado RM, Bradford CR, Terrell JE, Gebarski SS, Lichter AS (1996) Parotid gland sparing in patients undergoing bilateral head and neck irradiation: techniques and early results. *Int J Radiat Oncol Biol Phys*, **36**: 469–480.
18. Eisbruch A, Dawson LA, Kim HM, Bradford CR, Terrell JE, Chepeha DB, Teknos TN, Anzai Y, Marsh LH, Martel MK, Ten Haken RK, Wolf GT, Ship JA (1999) Conformal and intensity modulated irradiation of head and neck cancer: the potential for improved target irradiation, salivary gland function, and quality of life. *Acta Otorhinolaryngol Belg*, **53**: 271–275.
19. Vissink A, Jansma J, Spijkervet FKL, Burlage FR, Coppes RP (2003) Oral Sequelae Of Head And Neck Radiotherapy. *Crit Rev Oral Biol Med*, **14(3)**: 199–212.
20. Daly-Schveitzer N, Juliéron M, Tao YG, Moussier A, Bourhis J (2011) Intensity-Modulated Radiation Therapy (IMRT): Toward a new standard for radiation therapy of head and neck cancer? *European Annals of Otorhinolaryngology, Head and Neck Diseases*, **128**: 241–247.
21. Lee SH, Kim TH, Kim JY, Park SY, Pyo HR, Shin KH, Kim DY, Kim JY, Cho KH (2006) Evaluation of Parotid Gland Function following Intensity Modulated Radiation Therapy for Head and Neck Cancer. *Cancer Res Treat*, **38(2)**: 84–91.
22. Li W, Sun ZP, Liu XJ, Yu GY (2014) Volume measurements of human parotid and submandibular glands. *Journal of Peking University (Health Sciences)*, **46(2)**: 288–293.
23. Juan CJ, Cheng CC, Chiu SC, Jen YM, Liu YJ, Chiu HC, Kao HW, Wang CW, Chung HW, Huang GS, Hsu HH (2015) Temporal evolution of parotid volume and parotid apparent diffusion coefficient in nasopharyngeal carcinoma patients treated by intensity-modulated radiotherapy investigated by magnetic resonance imaging: A Pilot study. *Plos One*, **10(8)**: e0137073.
24. Cheng SCH, Vu VWC, Kwong DLW, Ying MTC (2011) Assessment of post-radiotherapy salivary glands. *The British Journal of Radiology*, **84**: 393–402.
25. Lee YYP, Wong KT, King AD, Ahuja AT (2008) Imaging of salivary gland tumours. *Eur J Radiol*, **66**: 419–36.
26. Nomayr A, Lell M, Sweeney R, Bautz W, Lukas P (2001) MRI appearance of radiation-induced changes of normal cervical tissues. *Eur Radiol*, **11**: 1807–1817.
27. Bryan RN, Miller RH, Ferreyro RI, Sessions RB (1982) Computed tomography of the major salivary glands. *AJR Am J Roentgenol*, **139**: 547–554.
28. Larsson SG, Lufkin RB, Hoover LA (1987) Computed tomography of the submandibular salivary glands. *Acta Radiol*, **28**: 693–696.
29. Jin X, Hu W, Shang H, Han C, Yi J, Zhou Y, Xie C (2013) CBCT-based volumetric and dosimetric variation evaluation of volumetric modulated arc radiotherapy in the treatment of nasopharyngeal cancer patients. *Radiation Oncology*, **8**: 279.
30. Wang ZH, Yan C, Zhang ZY, Zhang CP, Hu HS, Kirwan J, Mendenhall WM (2009) Radiation-induced volume changes in parotid and submandibular glands in patients with head and neck cancer receiving postoperative radiotherapy: a longitudinal study. *Laryngoscope*, **119(10)**: 1966–1974.
31. Sim CPC, Soong YL, Pang EPP, Lim C, Walker GD, Manton, Reynolds EC, Wee JTS (2018) Xerostomia, salivary characteristics and gland volumes following intensity-modulated radiotherapy for nasopharyngeal carcinoma: a two-year follow up. *Australian Dental Journal*, **63**: 217–223.

