

Feasibility study on protection of key organs in the whole brain radiotherapy with simultaneous integrated boost in patients with 1-3 brain metastases

Y.W. Yang, H.Y. Luo, Y.Y. Chen, J. Zhang, X. Bai, M. Chen*

The Cancer Hospital of the University of Chinese Academy of Sciences (Zhejiang Cancer Hospital) Zhejiang Provincial Key Laboratory of Radiation Oncology, Institute of Basic Medicine and Cancer (IBMC), Chinese Academy of Sciences, Hangzhou, Zhejiang 310022, China

ABSTRACT

► Original article

***Corresponding author:**

Ming Chen, MD,

E-mail:

Chenmingdr@163.com

Received: April 2021

Final revised: September 2021

Accepted: October 2021

Int. J. Radiat. Res., January 2022;
20(1): 83-89

DOI: 10.52547/ijrr.20.1.13

Background: To explore the feasibility of three radiotherapy techniques to realize simultaneous modulated accelerated radiation therapy for elective brain (SMART-Brain) in patients with 1-3 brain metastases. **Materials and Methods:** Intensity modulated radiation therapy (IMRT), volumetric modulated arc therapy (VMAT) and helical tomotherapy (HT) were utilized to design radiotherapy plans for 20 patients with 1-3 brain metastases from lung cancer who underwent SMART-Brain, and the dosimetry parameters of the target volume and organs at risk (OARs) were compared. **Results:** For planning gross tumor volume (PGTV), $D_{98\%}$ (near minimum) and conformity index (CI) of VMAT plan were significantly better than IMRT plan. For the planning target volume 1 (PTV1), HT plan provided better $D_{98\%}$, $D_{2\%}$ (near maximum dose), V_{30Gy} (target volume percent of 30Gy dose covering) and CI. In terms of the expose dose of hippocampus, HT plan had advantages in Dmean (mean dose), and its Dmax (maximum dose) was equivalent to VMAT plan, which was better than IMRT plan. HT and VMAT plans had a lower Dmax of optic chiasm, and VMAT plan was better in terms of dose limitation of scalp. In terms of lens protection, IMRT and VMAT plans were better than HT plan. There was no statistical difference in other dosimetry parameters. **Conclusion:** For most patients, all three radiotherapy techniques met clinical requirements. VMAT and HT plans were superior to IMRT plan. It was recommended that VMAT or HT radiotherapy techniques should be selected to implement SMART-Brain according to the local reality of the radiotherapy facilities.

Keywords: Brain metastases, IMRT, VMAT, HT, SMART-brain.

INTRODUCTION

Brain metastases accounted for more than half of all brain tumors and were the most common brain tumors in clinical practice ⁽¹⁾. Approximately 20% of tumor patients developed brain metastasis in the process of disease, most of which occurred in patients with pulmonary carcinoma, mammary carcinoma, melanoma or colorectal carcinoma ⁽²⁾. Especially for pulmonary carcinoma, brain metastases were extremely common at different stages of their diagnosis and treatment, rising from 10% at the first visit to 60%~80% two years later. Therefore, brain metastasis was an important factor affecting the quality of survival of patients ⁽³⁻⁴⁾.

Radiotherapy was the main treatment for brain metastases. The current realization methods mainly included whole brain radiotherapy (WBRT), stereotactic radiosurgery (SRS), whole brain radiotherapy combined with stereotactic radiosurgery (WBRT+SRS) and whole-brain radiation therapy with a simultaneous integrated boost (WBRT+SIB) ⁽⁵⁻⁶⁾.

For current image quality, millimeter or

submillimeter size of brain metastases could not be accurately diagnosed and located. So WBRT was proverbially used in radiation therapy for brain metastases. On the other hand, it made doctors realize that it could cause varying degrees of cognitive impairment ⁽⁷⁾. Thus, The doctors' concept had also gradually changed: for 1-4 newly diagnosed brain metastases, SRS has more advantages over WBRT and does not increase neurocognitive toxicity with no marked differences in overall survival (OS) ^(8, 9). Cochrane's meta-analysis of previous randomized controlled clinical trials showed that WBRT+SRS improved intracranial localization, reduced new intracranial lesions, but failed to improve OS, and had a larger probability of declined learning and memory ability compared with patients receiving SRS alone ⁽¹⁰⁾.

It was necessary to continuously improve the control rate of brain metastases, but also to ensure the cognitive function and hearing of patients, so as to improve the patient's existence quality. It was proved that short-term and late-term memory decline, and neurocognitive dysfunction was mainly caused by functional impairment of the hippocampus

caused by high-dose radiotherapy⁽¹¹⁻¹³⁾. Tinnitus, dizziness, sensory deafness and hearing loss after WBRT were related to the high exposure dose of the cochlea⁽¹⁴⁾. Moreover, brain metastases were more likely to occur in the cerebral cortex, subcortical area and corticomedullary junction, while the probability of brain metastasis in the hippocampus and cochlea was very small⁽¹⁵⁻¹⁷⁾. Therefore, the protection of hippocampal function during WBRT named as hippocampus-avoidance whole brain radiotherapy (HA-WBRT) had become a research hotspot in recent years⁽¹⁸⁻²⁰⁾.

As the cerebral cortex and cranial nerves were late-response tissues with slow cell proliferation and insensitivity to radiotherapy, they can safely tolerate a certain amount of exposure dose, while visible metastatic tumors required higher dose to be effectively controlled. Hippocampus-avoidance whole brain radiotherapy with a simultaneous integrated boost (HA-WBRT+SIB) could achieve better hippocampal protection as compared to hippocampus-avoidance whole brain radiotherapy combined with stereotactic radiosurgery (HA-WBRT+SRS)⁽²¹⁾. Simultaneous modulated accelerated radiation therapy for elective brain (SMART-Brain) was a WBRT method containing HA-WBRT+SIB, which could be chosen to protect not only the hippocampus, but also other organs selected as needed, such as the cochlea in the hearing area, hair follicles of the scalp, etc. The specific steps were as follows⁽²²⁻²³⁾: patients were treated with functional protective WBRT (limited in important functional areas such as hippocampus, cochlea and lens) once a day, with 3.0Gy each time and a total dose of 30Gy, 4.0~5.0Gy each time for visible brain metastases and the total dose was 40~50Gy; The whole radiotherapy process was completed within 2 weeks, which was shorter than the time of WBRT combined with SRS. The difficulties of this method was about the fusion of Computed Tomography (CT) and Magnetic Resonance Imaging (MRI) images, the accurate delineation of the hippocampus, the plan design of simultaneous integrated boost and protection of functional organs of metastatic tumors.

At present, three radiotherapy techniques, intensity modulated radiation therapy (IMRT), volumetric modulated arc therapy (VMAT) and helical tomotherapy (HT) had been widely utilized in clinical treatment. Could all three radiotherapy techniques achieve SMART-Brain radiotherapy? In this study, using SMART-Brain radiotherapy method, three types of radiation therapy were designed in RayStation v4.5 radiotherapy planning system (RaySearch Laboratories AB, Stockholm, Sweden) and helical tomography radiotherapy planning system (TomoTherapy Inc., Madison, WI, USA), for IMRT, VMAT and HT. The best treatment was chosen considering parameters such as the size and location of brain metastases. The promotion of

SMRAT-Brain radiotherapy may benefit people with brain metastases. This study provides a reference for SMRAT-Brain radiotherapy using different radiotherapy techniques.

MATERIALS AND METHODS

Information of patients

A total of 20 patients with 1-3 brain metastases who required SMRAT-Brain radiotherapy in the Department of Radiotherapy, Cancer Hospital Affiliated to the University of Chinese Academy of Sciences from 2018 to 2019 were selected. There were 11 males and 9 females aged 31~76 years old (median age 60). According to the eighth edition AJCC/UICC stage classification for lung cancer (2017), 12 patients were in IVa disease and 8 in stage IVb. All patients were immobilized in the supine position with a head, neck and shoulder thermoplastic mask. Philips Brilliance Big Bore 16-slice CT simulator (Philips Health Care GmbH, Hamburg, and Germany) was used to collect images with a layer thickness of 2.5mm, and the image collection range was more than 5cm beyond the target volume in the head-to-foot direction. All the patients underwent the same protocol of T1-weighted 3D structural MRI scan using a 3.0T scanner (MAGNETOM Verio; Siemens, Erlangen, Germany). Acquisition parameters were as follows: TR/TE =1440 ms/11 ms, flip angle =150°, field of view =230×230 mm², matrix size =320×320, and the size for each voxel was 1.0×0.7×1.5 mm³.

Delineation of target volume and organs at risk

CT and MRI images were fused in the RayStation v4.5 (RaySearch Laboratories AB, Stockholm, Sweden), and the contour of the gross tumor volume (GTV) of the brain metastases, the whole brain clinical target volume (CTV) and the organs at risk (OARs) were delineated on the fusion map according to the report of Radiation Therapy Oncology Group (RTOG) 0933. Planning gross tumor volume (PGTV): average outward expansion of GTV of brain metastases by 0.3cm. Planning target volume (PTV): average outward expansion of whole brain CTV by 0.3cm. Planning target volume 1 (PTV1): area of PTV minus the average outward expansion of hippocampus by 1.0cm. OARs included the hippocampus, brainstem, optic nerve, optic chiasm, cochlea, lens and scalp.

Plan design

Raystation and HT planning systems were utilized in this study. Linear accelerators were Trilogy (Varian Medical Systems, Palo Alto, Calif) and Helical Tomotherapy (TomoTherapy Inc., Madison, WI, USA), and all linear accelerators used X-rays with an energy of 6MV and a dose rate of 600MU/min. Plan design scheme: (1) 9-field IMRT plan

(200°,240°,280°,320°,0°,40°,80°,120°, 160°); (2) Two coplanar double-arc VMAT plans, with the gantry angle range of 182°~178°; (3) HT plan (a 1.05 cm field width was selected, the Pitches equivalent to 0.287 divided, and the modulation factor was set to 2). The prescribed doses were as follows: 45 Gy to the PGTV and 30 Gy to the PTV in 10 fractions. The plan required the prescribed doses surround the 95% of PGTV and the 90% of PTV, and the dose requirements of hippocampus, scalp, cochlea and lens should refer to RTOG 0933 report and related studies (24-25). The dose limits of hippocampus were Dmax < 17Gy, Dmean < 10Gy, Dmax < 8Gy for lens, Dmax < 50Gy for brainstem, Dmax < 50Gy for optic nerve, Dmean < 45Gy for cochlea, and Dmean < 18Gy for scalp. Table 1 showed the other relevant parameters.

Table 1. Target volume and Hippocampus parameters.

PGTV (cc)	PTV (cc)	Hippocampus (L and R) (cc)	Distance between PGTV and Hippocampus_L (cm)	Distance between PGTV and right hippocampus_R (cm)
23.15±19.14	1512.43±175.88	3.51±0.78	3.51±2.10	3.14±1.70

Plan evaluation

Assessment parameters of PTV1 and PGTV: D_{98%} (near minimum), V_{45Gy} or V_{30Gy}, D_{2%} (near maximum dose), conformity index (CI) and homogeneity index (HI). D_{x%} was the dose covering x% of the target volume, V_{xGy} was the target volume percent of xGy dose covering. CI = (target volume covered by reference isodose (VTref)/ target volume (VT)) × (VTref/ volume of the reference isodose (Vref)) (26), VTref was the planned target volume included in the clinical prescription dose isodose, VT was the planned target volume, and Vref was all the volumes included in the clinical prescription dose. HI = (D_{2%} - D_{98%})/D_{50%} (27).

Evaluation parameters of OARs: the Dmean and Dmax of OARs in three groups were evaluated, including lens, scalp, cochlea, optic nerve, optic chiasm and hippocampus.

Statistical methods

SPSS 22.0 software was utilized to conduct statistical analysis on the dosimetry parameters of 20 patients with brain metastases. Wilcoxon signed rank test was used. P<0.05 was considered to be statistically significant.

RESULTS

Dose distribution

Dose parameters of three radiotherapy techniques for 20 patients were listed in tables 2, 3 and 4, expressed as the mean values± standard difference (SD). The V_{45Gy} of all PGTV was normalized to 95%. Figure 1 showed distance-dose histogram of bilateral

hippocampus to PGTV. Figure 2 showed size-dose histogram of bilateral hippocampus to PGTV. Figure 3 showed CT images of dose distributions of IMRT, VMAT and HT in brain metastases from one representative case. Figure 4 showed DVHs of IMRT, VMAT and HT of brain metastases from the same case.

Dosimetric volume parameters of target volume

As shown in table 2, for PGTV, the D_{98%} and CI of VMAT plan were significantly better than IMRT plan; for PTV1, the HT plan provided better D_{98%} (b,c), D_{2%} (a,c), V_{30Gy} (c), CI (a,b,c). There was no statistical difference in the dosimetry parameters of other target volumes.

Hippocampal parameters

As shown in table 1, the average volume of PTV was 1512.43±175.88 cc, and the average volume of hippocampus was 3.51±0.78 cc, which accounting for about 0.23% of the PTV. During the planning design, if the distance of one side of the hippocampus was less than 0.5 cm from the PGTV, the dose of this hippocampus was not limited, because all the plans of the three radiotherapy techniques could not meet the clinical requirements. As shown in table 3, figure 1 and 2, in terms of exposure dose, HT plan had advantages in terms of Dmean of hippocampus (b, c), and IMRT plan was inferior to VMAT and HT plans in terms of Dmax of hippocampus (a, b).

Dose of OARs

The brain stem, lens, optic nerve, optic chiasm, and cochlea of the three types of plans met the clinical dose limit requirements. HT plan had lower Dmax of optic chiasma (a,b); The VMAT plan was superior in terms of scalp dose limitation (a,c); In terms of lens avoidance, IMRT and VMAT plans were superior to HT plan (Lens_L Dmax (a,b,c) and Lens_R Dmax (b,c)). There was no statistical difference in the dosimetry parameters of other OARs.

Table 2. Comparison of dosimetry parameters of target volume among VMAT, IMRT and HT plans.

ROI Parameters	Evaluation parameters	IMRT	VMAT	HT	P
PGTV	D _{98%} (Gy)	43.87±0.60	44.12±0.42	43.42±2.07	a
	V _{45Gy} (%)	0.95±0.00	0.95±0.00	0.95±0.00	>0.05
	D _{2%} (Gy)	48.69±0.78	49.02±0.78	48.87±1.85	>0.05
	CI	0.69±0.09	0.73±0.09	0.68±0.13	a
	HI	0.10±0.02	0.10±0.02	0.12±0.08	>0.05
PTV1	D _{98%} (Gy)	26.83±1.28	26.99±1.68	29.03±1.53	b,c
	V _{30Gy} (%)	0.95±0.01	0.95±0.01	0.96±0.02	c
	D _{2%} (Gy)	43.30±2.93	42.52±3.59	44.03±4.17	a,c
	CI	0.83±0.03	0.85±0.04	0.88±0.06	a,b,c
	HI	0.49±0.09	0.46±0.12	0.46±0.13	>0.05

a: IMRT vs VMAT, b: IMRT vs HT; c: VMAT vs HT, if the P value of group a was less than 0.05, filled in a in the P value area, and so on.

Table 3. Comparison of hippocampal doses in patients with brain metastases.

ROI Parameters	Evaluation parameters	IMRT	VMAT	HT	P
Hippocampus_L	Dmean(Gy)	9.72±0.31	9.66±0.23	9.22±0.68	b, c
	Dmax(Gy)	16.39±1.37	15.09±1.39	15.17±1.43	a, b
Hippocampus_R	Dmean(Gy)	9.76±0.29	9.63±0.21	9.10±0.41	b, c
	Dmax(Gy)	16.23±0.93	15.13±1.23	15.23±1.21	a, b

a: IMRT vs VMAT, b: IMRT vs HT; c: VMAT vs HT, if the P value of group a was less than 0.05, filled in a in the P value area, and so on.

Table 4. Comparison of dosimetry parameters of OARs among IMRT, VMAT and HT plans.

ROI Parameters	Evaluation parameters	IMRT	VMAT	HT	P
Brain stem	Dmax(Gy)	42.20±3.16	41.12±3.98	41.30±4.08	>0.05
Lens_L	Dmax(Gy)	5.52±0.58	5.41±0.60	6.12±0.68	a,b,c
Lens_R	Dmax(Gy)	5.49±0.48	5.45±0.51	6.10±0.70	b,c
Optic nerve_L	Dmax(Gy)	32.40±3.91	31.77±3.25	32.52±2.82	>0.05
Optic nerve_R	Dmax(Gy)	33.55±4.29	32.42±4.09	32.85±3.47	>0.05
Optic chiasm	Dmax(Gy)	39.99±2.46	37.89±3.04	37.28±2.53	a,b
Cochlea_L	Dmean(Gy)	31.12±2.59	31.15±2.43	31.31±3.18	>0.05
Cochlea_R	Dmean(Gy)	32.09±3.50	31.56±3.50	32.50±3.34	>0.05
Scalp	Dmean(Gy)	16.68±3.99	16.25±3.78	17.60±4.11	a,c

a: IMRT vs VMAT, b: IMRT vs HT; c: VMAT vs HT, if the P value of group a was less than 0.05, filled in a in the P value area, and so on.

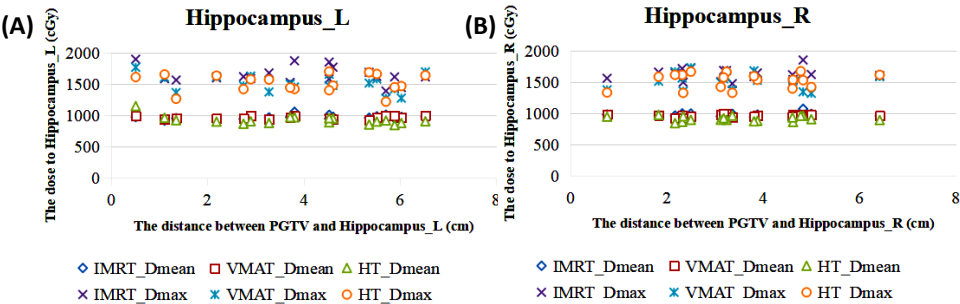


Figure 1. Distance-dose histogram of bilateral hippocampus to PGTV ((A)Hippocampus_L (B) Hippocampus_R; The abscissa was the distance between PGTV and hippocampus, and the ordinate was the dose to hippocampus; Cases without dose limitation in hippocampus were not marked).

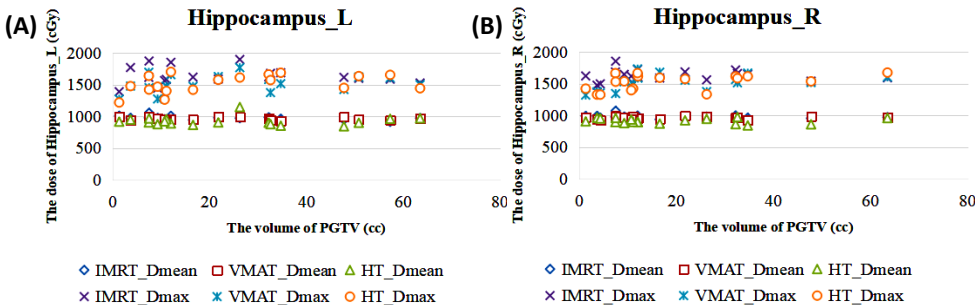


Figure 2. Size-dose histogram of bilateral hippocampus to PGTV ((A) Hippocampus_L (B) Hippocampus_R; The abscissa is the volume of PGTV and the ordinate is the dose of hippocampus; Cases without dose limitation in hippocampus were not marked).

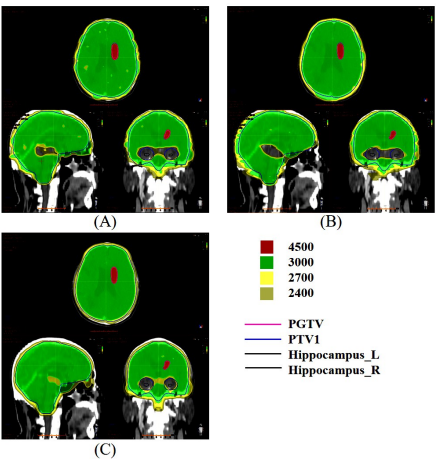


Figure 3. CT images of dose distribution of IMRT, VMAT and HT in brain metastases ((A) IMRT (B)VMAT (C)HT).

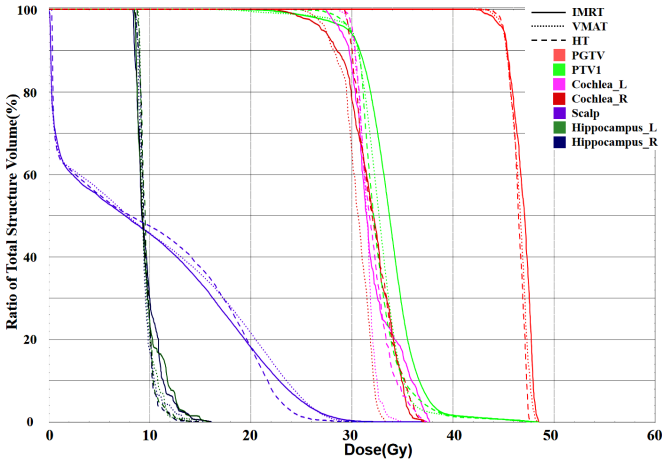


Figure 4. Dose-volume histograms (DVHs) of IMRT, VMAT and HT of brain metastases.

DISCUSSION

Brain metastases were mostly caused by blood metastasis. In addition to the metastatic lesions visible on imaging, there were also sub-metastatic lesions that cannot be found by current imaging techniques. If only the visible metastatic lesions were irradiated, the intracranial subclinical lesions may not be effectively controlled. One study of intracranial tumor control in long-term survivors found that WBRT was better than SRS but that its negative effects on the cognitive system persist persisted⁽²⁸⁾. With the development of high-end equipment and technology for radiotherapy, It was feasible to achieve SMART-Brain.

In this study, the dosiological characteristics of SMART-Brain using different radiotherapy techniques (IMRT, VMAT and HT) were compared. The results were summarized and we found that all three radiotherapy techniques achieved target coverage and met basic clinical standards of dosiology, and HT provided the best conformity dose of PTV1 (mean CI = 0.88). Jiang et al. applied four radiotherapy techniques to study the HA-WBRT+SIB, and found that HT technique could achieve better target coverage, which was consistent with our study⁽²³⁾. He also found that the HI of PTVbrain obtained with HT was best, which was different from our study. One possible reason was that the PTVbrain defined was different from the PTV1 in this article. In this study, all three radiotherapy techniques provided good average PGTV target coverage and similar D_{2%} and HI. The D_{98%} and CI of VMAT were superior to IMRT, and were not different from HT.

Studies had shown that the pathogenesis of radiation-induced neurocognitive dysfunction may be caused by radiation damage of proliferative and migratory stem cells in the hippocampus subgranular region^(11,29). Redmond et al. studied 19 children who received WBRT and found that the hippocampal radiation dose was positively correlated with the neurocognitive decline after craniocerebral radiotherapy. When the Dmean of hippocampus reached 12Gy, it will cause cognitive dysfunction in children⁽³⁰⁾. Gondi et al. conducted experiments on a total of 1133 brain metastatic lesions in 371 patients, and found that none of the lesions were located in the hippocampus, and the probability of brain metastatic lesions occurring in the area 5mm away from the hippocampus was only 3.0%, proving the feasibility of avoiding hippocampal irradiation⁽³¹⁾. HA-WBRT to maintain neurocognitive function was a feasible method. Recent study had also shown that HA-WBRT+SIB could make better hippocampal protection compared to HA-WBRT+SRS⁽²²⁾. In addition, NRG Oncology CC001 clinical trials found that compared with WBRT alone, the combination of memantine and hippocampal protective radiotherapy can reduce the risk of cognitive impairment by 42%⁽³²⁾.

Some researchers had used IMRT, VMAT and HT to explore the advantages of HA-WBRT or HA-WBRT+SIB^(22-25,33-35). In this study, when the prescription dose PTV1 was set to 30 Gy/10 fractions, HT plan could achieve a lower Dmean and Dmax of hippocampus than the IMRT plan, which had been already confirmed by Gondi et al.⁽³⁴⁾. We confirmed that all three radiotherapy techniques met the dose compliance criteria of hippocampal sparing outlined in RTOG 0933. The average hippocampus dose of the three radiotherapy techniques was 67.5%~69.5% lower compared to the prescription dose, similar to the results obtained in some studies^(24,26). HT plan had advantages in Dmean, and the Dmax was similar to VMAT plan and superior to IMRT plan.

Previous studies were mainly studied whether if hippocampus protection was realized through different radiotherapy techniques, but did not study the relationship between dose of hippocampus and characteristics of brain metastases, such as the locations and sizes. As shown in figure 1, when the hippocampus was more than 1cm away from the PGTV, Dmean and Dmax of hippocampus had little correlation with the location of PGTV. As shown in Figure 2, the volume change of PGTV (1.34cc to 63.48cc) had little effect on the dose of hippocampus. It was because the dose limitation conditions in the hippocampus were already very strict. During the optimization process, after the required dose requirements being reached, the dose would not continue to be lowered, but the dose of target volume would be ensured as a priority.

HT was slightly better than IMRT and VMAT in the protection of other OARs except scalp. This study also added a dose limitation of scalp. Previous studies had shown that reduced dose of scalp could reduce the hair follicle injury of scalp, improve hair regeneration rate after radiotherapy, and reduce the occurrence of permanent hair loss⁽³⁶⁾. Different from most studies, this study not only studied the protection of the key OARs in WBRT+SIB, but also analyzed the effects of size and location of brain metastases on hippocampus. SMART-Brain could also explore the radiation protection of red bone marrow in the skull barrier.

CONCLUSION

In summary, all three radiotherapy techniques met clinical requirements for most patients. HT performed better in target coverage to PTV1 and better protection to OARs, and VMAT was superior to IMRT. It was recommended that VMAT or HT radiotherapy techniques should be selected to implement SMART-Brain according to the local reality of the radiotherapy facilities. Due to the limited case data, only patients with oligometastasis were selected for the study in this article. In the future, further study and analysis will be conducted

on patients with multiple brain metastases.

ACKNOWLEDGMENTS

This work was supported by grants from the National Natural Science Foundation of China (12005190), Zhejiang Key R&D Program (2019C03003) and Zhejiang Medical and Health Project (2020KY472, 2022KY673).

An ethics statement

This study had been approved by the ethics committee of Zhejiang Cancer Hospital, and the committee approval number was: IRB-2021-218 (2021.07.01).

Conflicts of interest: None declared.

Funding: None.

Author contribution: (Y.W) Yang: Conceptualization, Methodology, Formal analysis, Data curation, Validation, Writing - review & editing. (H.Y) Luo: Conceptualization, Methodology, Writing - review & editing, Validation, Investigation. (Y.Y) Chen: Conceptualization, Methodology, Writing - review & editing. (J.Zh): Data curation, Writing - review & editing. (X.B): Funding acquisition, Data curation, Writing - review & editing. (M.C): Conceptualization, Methodology, Formal analysis, Funding acquisition, Supervision, Writing - review & editing.

REFERENCES

- Vogelbaum MA and Suh JH (2006) Resectable brain metastases. *J Clin Oncol*, **24**(8): 1289-1294.
- Achrol AS, Rennert RC, Anders C, Soffietti R, Ahluwalia MS, Nayak L, et al. (2019) Brain metastases. *Nat Rev Dis Primers*, **5**(1): 1-26.
- Murray N and Sheehan F (2001) Limited stage small cell lung cancer. *Curr Treat Option On*, **2**(1): 63-70.
- Shi Y, Sun Y, Yu J, Ding C, Ma Z, Wang Z, et al. (2017) China experts consensus on the diagnosis and treatment of brain metastases of lung cancer (2017 version). *Chin J Lung Canc*, **20**(1): 1-13.
- Rades D, Kueter JD, Hornung D, Veninga T, Hanssens P, Schild SE, et al. (2008) Comparison of stereotactic radiosurgery (srs) alone and whole brain radiotherapy (wbrt) plus a stereotactic boost (wbrt+srs) for one to three brain metastases. *Strahlenther Onkol*, **184**(12): 655-662.
- Lagerwaard FJ, Eppinga W, Haasbeek C, Haan PD, Slotman BJ (2010) Whole brain radiotherapy with simultaneous integrated boost (wbrt+sib) for multiple brain metastases (bm) using volumetric modulated arc therapy. *Int J Radiat Oncol*, **78**(3): S777.
- Hong AM, Fogarty GB, Dolven-Jacobsen K, Burmeister BH, Lo SN, Haydu LE, et al. (2019) Adjuvant whole-brain radiation therapy compared with observation after local treatment of melanoma brain metastases: a multicenter, randomized phase III trial. *J Clin Oncol*, **37**(33): 3132-3141.
- Tsao MN, Rades D, Wirth A, Lo SS, Danielson BL, Gaspar LE, et al. (2012) Radiotherapeutic and surgical management for newly diagnosed brain metastasis (es): An American society for radiation oncology evidence-based guideline. *Pract Radiat Oncol*, **2**(3): 210-225.
- Chao ST, De Salles A, Hayashi M, Levivier M, Ma L, Martinez R, et al. (2018) Stereotactic radiosurgery in the management of limited (1-4) brain metastases: systematic review and international stereotactic radiosurgery society practice guideline. *Neurosurgery*, **83**(3): 345-353.
- Tsao MN, Xu W, Wong RK, Lloyd N, Laperriere N, Sahgal A, et al. (2018) Whole brain radiotherapy for the treatment of newly diagnosed multiple brain metastases. *Cochrane Db Syst Rev*, **1**(1): CD003869.
- Roughton K, Kalm M, Blomgren K (2012) Sex-dependent differences in behavior and hippocampal neurogenesis after irradiation to the young mouse brain. *Eur J Neurosci*, **36**(6): 2763-2772.
- Brown PD, Ahluwalia MS, Khan OH, Asher AL, Wefel JS, Gondi V (2018) Whole-brain radiotherapy for brain metastases: evolution or revolution?. *J Clin Oncol*, **36**(5): 483.
- Huo M, de Moraes FY, Foote M, Pinkham MB, Marta GN, Suh JH (2020) Indications for Whole-Brain Radiation Therapy. In Radiotherapy in Managing Brain Metastases. *Springer Cham*, 165-184.
- Bhandare N, Jackson A, Eisbruch A, Pan CC, Flickinger JC, Antonelli P, Mendenhall WM (2010) Radiation therapy and hearing loss. *Int J Radiat Oncol*, **76**(3): S50-S57.
- Ghia A, Tomé WA, Thomas S, Cannon G, Khuntia D, Kuo JS, Mehta MP (2007) Distribution of brain metastases in relation to the hippocampus: implications for neurocognitive functional preservation. *Int J Radiat Oncol*, **68**(4): 971-977.
- Marsh JC, Herskovic AM, Gielda BT, Hughes FF, Hoepfner T, Turian J, Abrams RA (2010) Intracranial metastatic disease spares the limbic circuit: a review of 697 metastatic lesions in 107 patients. *Int J Radiat Oncol*, **76**(2): 504-512.
- Wan JF, Zhang SJ, Wang L, Zhao KL (2013) Implications for preserving neural stem cells in whole brain radiotherapy and prophylactic cranial irradiation: a review of 2270 metastases in 488 patients. *J Radiat Res*, **54**(2): 285-291.
- Wang S, Zheng D, Zhang C, Ma R, Bennion NR, Lei Y, et al. (2017) Automatic planning on hippocampal avoidance whole-brain radiotherapy. *Med Dosim*, **42**(1): 63-68.
- Lee G, Besse L, Lamba N, Hancox C, Usta I, Hacker F, et al. (2021) Feasibility of hippocampal avoidance whole brain radiation in patients with hippocampal involvement: Data from a prospective study. *Med Dosim*, **46**(1): 21-28.
- Brown PD, Jaeckle K, Ballman KV, Farace E, Cerhan JH, Anderson SK, et al. (2016) Effect of radiosurgery alone vs radiosurgery with whole brain radiation therapy on cognitive function in patients with 1 to 3 brain metastases: a randomized clinical trial. *JAMA*, **316**(4): 401-409.
- Prokic V, Wiedenmann N, Fels F, Schmucker M, Nieder C, Grosu AL (2013) Whole brain irradiation with hippocampal sparing and dose escalation on multiple brain metastases: a planning study on treatment concepts. *Int J Radiat Oncol*, **85**(1): 264-270.
- Popp I, Rau S, Hintz M, Schneider J, Bilger A, Fennell JT, et al. (2020). Hippocampus-avoidance whole-brain radiation therapy with a simultaneous integrated boost for multiple brain metastases. *Cancer*, **126**(11): 2694-2703.
- Jiang A, Sun W, Zhao F, Wu Z, Shang D, Yu Q, et al. (2019) Dosimetric evaluation of four whole brain radiation therapy approaches with hippocampus and inner ear avoidance and simultaneous integrated boost for limited brain metastases. *Radiat Oncol*, **14**(1): 1-8.
- Mehta MP, Gondi V, Corn B (2011) Radiation therapy oncology group. A phase II trial of hippocampal avoidance during whole brain radiotherapy for brain metastases. *RTG*, 933.
- Zhang M, Sun T, Mingwei BU, Guo X, Zhang J (2015) A dosimetric study of hippocampal-avoidance prophylactic cranial irradiation in intensity-modulated radiotherapy and volumetric modulated arc therapy for patients with localized small cell lung cancer achieving complete response after chemoradiotherapy. *Chin J Lung Canc*, **24**(6): 675-679.
- Feuvret L, G Noël, Mazon JJ, Bey P (2006) Conformity index: a review. *Int J Radiat Oncol*, **64**(2): 333-342.
- Hodapp N (2012) The ICRU report 83: prescribing, recording and reporting photon-beam intensity-modulated radiation therapy (IMRT). *Strahlenther Onkol*, **188**(1): 97-99.
- Brown PD, Ballman KV, Cerhan JH, Anderson SK, Carrero XW, Whitton AC, et al. (2017) Postoperative stereotactic radiosurgery compared with whole brain radiotherapy for resected metastatic brain disease (NCCTG N107C/CEC-3): a multicentre, randomised, controlled, phase 3 trial. *Lancet Oncol*, **18**(8): 1049-1060.
- Sun Q, Li M, Wang G, Xu H, He Z, Zhou Y, et al. (2019) Distribution of metastasis in the brain in relation to the hippocampus: a retrospective single-center analysis of 565 metastases in 116 patients. *Cancer Imaging*, **19**(1): 1-9.
- Redmond KJ, Mahone EM, Terezakis S, Ishaq O, Ford E, McNutt T, et al. (2013) Association between radiation dose to neuronal progenitor cell niches and temporal lobes and performance on neuropsychological testing in children: a prospective study. *Neuro-Oncology*, **15**(3): 360-369.
- Gondi V, Tome WA, Marsh J, Struck A, Ghia A, Turian JV, et al. (2009) Estimated risk of perihippocampal disease progression after

hippocampal avoidance during whole-brain radiotherapy: comprehensive multi-institution review of 371 patients with 1133 brain metastases. *Int J Radiat Oncol*, **75**(3): S236.

32. Gondi V, Deshmukh S, Brown PD, Wefel JS, Tome W, Armstrong T, et al. (2019) NRG Oncology CC001: A phase III trial of hippocampal avoidance (HA) in addition to whole-brain radiotherapy (WBRT) plus memantine to preserve neurocognitive function (NCF) in patients with brain metastases (BM). *J Clin Oncol*, 2009-2009.
33. Gondi V, Tolakanahalli R, Mehta MP, Tewatia D, Rowley H, Kuo JS, et al. (2010) Hippocampal-sparing whole-brain radiotherapy: a "How-to" technique using helical tomotherapy and linear accelerator-based intensity-modulated radiotherapy. *Int J Radiat Oncol*, **78** (4): 1244-1252.
34. Blomstrand M, Brodin NP, Munck af Rosenschöld P, Vogelius IR, Sánchez Merino G, Kiil-Berthlesen A, et al. (2012) Estimated clinical benefit of protecting neurogenesis in the developing brain during radiation therapy for pediatric medulloblastoma. *Neuro-oncology*, **14**(7): 882-889.
35. Gondi V, Hermann BP, Mehta MP, Tomé WA (2012) Hippocampal dosimetry predicts neurocognitive function impairment after fractionated stereotactic radiotherapy for benign or low-grade adult brain tumors. *Int J Radiat Oncol*, **83**(4): e487-e493.
36. Kao J, Darakchiev B, Conboy L, Ogurek S, Sharma N, Ren X, et al. (2015) Tumor directed, scalp sparing intensity modulated whole brain radiotherapy for brain metastases. *Technol Cancer Res T*, **14** (5): 547-555.

