

## Percutaneous laser photocoagulation of osteoid osteoma: Assessment of treatment in nine cases

K. Firouznia<sup>1\*</sup>, H. Ghanaati<sup>1</sup>, H. Hashemi<sup>1</sup>, N. Ahmadinezhad<sup>1</sup>, H. Soroush<sup>2</sup>, M. Shakiba<sup>2</sup>

<sup>1</sup> Dept. of Radiology, Medical Imaging Center, Imam Khomeini Hospital, Tehran University of Medical Sciences, Tehran, Iran

<sup>2</sup> Research unit, Medical Imaging Center, Imam Khomeini Hospital, Tehran University of Medical Sciences, Tehran, Iran

---

### ABSTRACT

**Background:** Osteoid osteoma is a benign bony neoplasm and its classic treatment is surgery. In the recent decades percutaneous laser therapy was suggested to be replaced by surgery. In this study we have reviewed the results of the first applications of interstitial laser photocoagulation (ILP) for treatment of osteoid osteoma in Iranian patients.

**Materials and Methods:** In this case series study, we evaluated 9 known cases of osteoid osteoma that were referred for ILP from orthopedic section of Imam Khomeini hospital during 2001 and 2002. Diagnosis was confirmed by plain X-ray, CT, isotope & MR scan. ILP was done by interventional radiologists of medical imaging center. Percutaneous ILP was performed by Nd-Yag laser, using 400-1000 joules energy (according to nidus size) and adjusting on 2 watts power.

**Results:** The procedure was successful in all patients. We had pain relief in 24 hours. Follow up from 5 months to one year showed no recurrence.

**Conclusion:** The procedure is a safe and effective method for patients and could be applied for proper cases.

---

**Key words:** Osteoid osteoma, interstitial laser photocoagulation, CT scan, bone tumors, interventional radiology.

### INTRODUCTION

Osteoid osteoma is a benign bony neoplasm which often occurs in young men. It is most common in first three decades of life; however, some of the lesions occur in older patients. Typically the patients have pain which is worse at nights and is relieved with aspirin (Carnesale 1998, Rogers 1993). Cortical osteoid osteoma appears as a small radiolucent area which its diameter is not larger than a few millimeters, so it may be

missed in preliminary X-rays. Usually the sclerotic reaction is severe. Tomography or CT scan may be necessary to demonstrate the central lucency, which is a significant landmark. Mostly, the lesions occur at the femoral neck and extremities (Cayli *et al.* 1998, Radcliffe *et al.* 1998). If the lesion occurs near the joints, there is a possibility of swelling and stiffness. In children, if the vertebral cord is involved, there would be a possibility of scoliosis. (Carnesale 1998, Rogers 1993, Radcliffe *et al.* 1998). The most important differential diagnosis is brodie's abscess (Adams and Hamblen 1995).

There are various methods in treating osteoid osteoma such as surgery, percutaneous extraction trocar alcoholization and thermo-coagulation with radio frequency and laser.

---

**\*Corresponding author:**

Dr. K. Firouznia, Dept. of Radiology, Medical Imaging Center, Imam Khomeini Hospital Tehran University of Medical Sciences, Tehran, Iran. Fax: +98- 21-6910201, E-Mail: [k\\_firouznia@yahoo.com](mailto:k_firouznia@yahoo.com)

Interstitial laser photocoagulation (ILP) is a new method based on invitro and experimental animal studies. These investigations have shown promising results, with well-demarcated coagulated tissues (thermal necrosis) that have predictable size in solid tissues with the use of a low-power laser probe. Tumors are coagulated and thus destroyed by direct heating in this method. This technique has been applied clinically to treat liver, pancreas, prostate, brain, breast, and lymph nodes tumors. Experimental work has shown that a reproducible, well-defined area of coagulative necrosis is obtained around the precharred fiber tip in bone, with good correlation between energy delivered and lesion size. Carbonization of the fiber tip before ILP (precharring) makes the effect more predictable (Gangi *et al.* 1998a).

The laser energy is able to coagulate and vaporize the tissues (Radcliffe *et al.* 1998) In interstitial laser photocoagulation (ILP) the laser energy is used to coagulate and destruct the tumor through direct heat (Gangi *et al.* 1998b). The experiments showed that the maximum necrosis would be achieved after reception of 1000-1200 joules that can cause osteocyte necrosis (50°C) at 8 mm around the fiber tip (Gangi *et al.* 1998a).

The size of osteoid osteomas falls within the range of those that can be effectively coagulated, and the nidus can be identified precisely on CT scans. The transmission of heat within bone is sharply limited by blood flow and by the fact that high temperatures cannot be sustained over great distances (Gangi *et al.* 1998a). The maximum necrosis depends on the wave length, energy deposited, used power (the temperature of instruments, tip), the optical and thermal characteristics of target tissue and the type of the optic fiber. (Gangi *et al.* 1998a, Gangi *et al.* 1997a, Gangi *et al.* 1998c, Wacker *et al.* 1998). Precise control of treated area, high accuracy the applicability in joints make the ILP more superior to alcoholization and the other techniques which remove the tissue *in situ*. ILP needs one night hospitalization and the patients

can return to their works afterward.

ILP has been carried out just in patients with typical lesions. It is considered that ILP is a safe and effective technique which is able to treat osteoid osteoma without potential complications of excision (Gangi *et al.* 1998a, Gangi *et al.* 1998b, Gangi *et al.* 1997a, Gangi *et al.* 1995).

Laser therapy is a non-invasive method and it is more economical than surgery. According to the resection of surgery with the weakening of bone and the risk of fracture, the main purpose of ILP is the local destruction of lesion without harming the bone. According to the priority of using ILP in treating osteoid osteoma in Iran, we should modify all accepts of treatment. The main purpose of this study is assessing the success of laser therapy in treatment of osteoid osteoma in patients who were referred to Imam Khomeini hospital during 2001 & 2002.

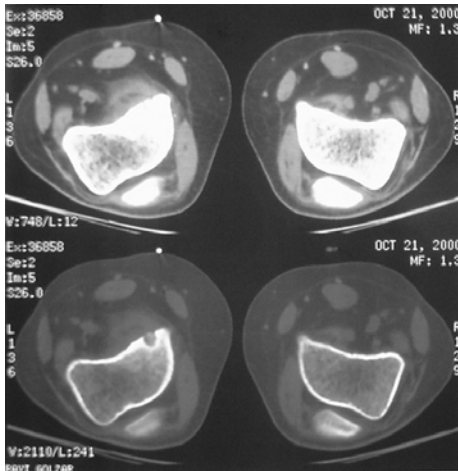
## MATERIALS AND METHODES

At first, the diagnosis was confirmed in all patients by plain radiography, CT scan Isotope scan and MRI. Lesions were localized with CT scan and the nidus dimension was measured. The maximum diameter of nidus determined the needed energy for tumor photocoagulation (Gangi *et al.* 1995, Gangi *et al.* 1997a) (table1). The laser equipment was Nd-YAG type. In all patients, the used power was two watts. The needle entered the nidus under the CT guide (Towbin *et al.* 1995, Mazayer *et al.* 1991). Those subperiosteal or cortical nidi, without major calcification, were directly penetrated by a

**Table 1.** Required energy for every nidus size.

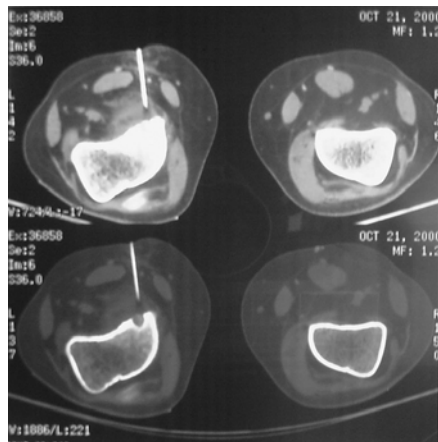
Required Energy (Joules)	Nidus size
200	3.5
400	5
600	6
800	7.5
1000	9

biopsy needle, G: 18 (Ny, Rutherford, Becton Dickenson) (figure1). Since the needle size was small and hence the collection of sufficient

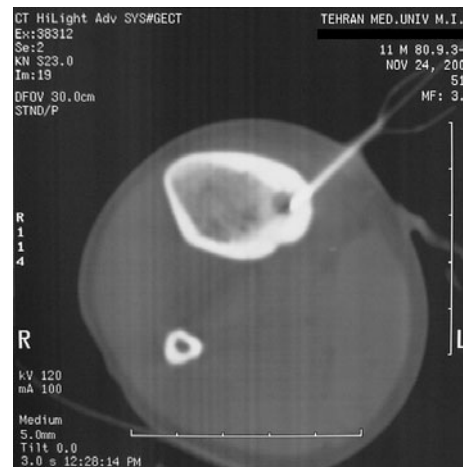

**Figure 1.** Cortical Nidus in the Distal metaphyseal Femur.

sample was not possible, the biopsy had not been carried out. An eight hundred micron fiber inserted through the needle. The needle was withdrawn about 5mm to let the bare tip of needle to be remained within the tumor (figures 2&3). Fiber precharing was done clinically by firing of fiber in a few milliliter of patient's blood immediately before initiating the procedure (Mazayer *et al.* 1991, Assoun *et al.* 1993). One follow up was done for all patients and in that, patient's symptoms were assessed and imaging studies were done with CT scan and/or plain radiography.



**Figure 2.** Needle navigation with CT scan.



**Figure 3.** ILP of proximal metaphyseal tibia nidus.

## RESULTS

Nine patients with history and radiological manifestations of osteoid osteoma had been treated by ILP. One patient was female and others were male. The male patients were in the age range of 9-20 years and the female patient was 79 years old. In all patients, the procedure was done with local anesthesia, and CT scan controls showed nidus were destroyed completely and that nidus sclerosis had occurred completely. The pain relief occurred promptly, maximum by 24 hours after the procedure in all patients. There was no evidence of infection in any patients, and no evidence of recurrence was observed in 6 months and one year follows up (table 2). In spite of some degree of sclerosis there was no evidence of nidus residue or new bone formation. All clinical signs of patients had disappeared. No complications had been observed in patients during and immediately after the procedure, and in short and long term follow up.

## DISCUSSION

Osteoid osteoma is a benign bony tumoral lesion. For treating patients, the nidus should be removed or destructed. Surgery is the classic treatment. Most authors suggest enblock resection; however, the risk of fracture in this method is

**Table 2.** Disease characteristics, location of nidi and treatment indices in patients

Subjects	The amount of pain before treatment	Time of pain before treatment	Response to NSAID (the number of consumed tablets)	Nidus Diameter	Deformity	Involved bone and site	Remedy amount after ILP	Time interval between pain relief and complement of ILP	Follow up period	Results of follow up Recurrence
1/F/79	Class III - Inability to sleep	Night	Brufen 400 10/ day	8mm	-	Distal of Internal condyle of left Femur- cortical	-	One day after treatment	1 year	No Recurrence
2/M/18	Class II – Inability to do daily activity	Night	Ibuprofen 400 8/day	4mm	-	Distal of left Femur- cortical	-	Immediately	11 month	No Recurrence
3/M/6	Class II - Inability to do daily activity -	Night	Aspirin 10/day	5mm	-	Distal of right Tibia- Cortical	-	Immediately	5 month	No Recurrence
4/M/9	Class II - Inability to do daily activity	Night	Aspirin 16/day	7mm	-	1/3 middle of right Tibia- Endosteal	-	Tomorrow after treatment	1 year	No Recurrence
5/M/11	Class III – Inability to sleep	Night	Ibuprofen 200 20/day	4mm	-	Proximal of right Tibia- Endosteal	-	Immediately	1 year	No Recurrence
6/M/16	Class III – Inability to sleep	Night	Aspirin 10/day	5mm	-	Distal of left Femur- cortical	-	Immediately	1 year	No Recurrence
7/M/22	Class II - Inability to do daily activity	Night	Aspirin 10/day	7mm	-	Distal of right Tibia- Cortical	-	Tomorrow after treatment	9 month	No Recurrence
8/M/8	Class II - Inability to do daily activity	Night	Ibuprofen 200 20/day	4mm	-	Proximal of left Femur- Endosteal	-	Immediately	1 year	No Recurrence
9/M/12	Class II - Inability to do daily activity	Night	Brufen 400 10/ day	5mm	-	Distal of right Tibia- Endosteal	-	Tomorrow after treatment	11 month	No Recurrence

high because the lesions are often cortically located. It would be very comfortable for patients if an easy procedure is done instead of surgery, because operation is very costly and needs post operation cares and enbloc resection may cause bone fracture after the surgery. Since the presentation of laser many studies have been carried out it's assess the function in treatment of osteoid osteoma (Carnesale 1998, Radcliffe *et al.* 1998, Gangi *et al.* 1998a, Gangi *et al.* 1998, Wacker *et al.* 1998c, Gangi *et al.* 1997b). In laser therapy we should consider that the diagnosis must be confirmed without histological examinations, for example some studies showed that in some

radiologic and radioisotope studies although the clinical symptoms and history were positive, there were no evidence of disease and biopsy was done to confirm the diagnosis. The bone nidus is the typical finding (Carnesale 1998, Rogers 1993, Radcliffe *et al.* 1998). Cortical osteoid osteoma appears as a small radiolucent area with sclerosis and enhanced margins, we use spiral CT scan and tomography to demonstrate it, so, there won't be a need for biopsy to confirm the diagnosis. If the lesion is confirmed without histological examinations, we are authorized to use methods like ILP.

Guiding laser fiber trough skin to the location

of the nidus is very important in laser therapy. There are various methods in guiding laser fiber. For instance, when ILP was performed CT guided on vertebral lesions the results were noticeable (Gangi *et al.* 1998c). Guiding fiber with CT scan showed acceptable results in other parts of the body (Gangi *et al.* 1995, Towbin *et al.* 1995, Mazayer *et al.* 1991, Assoun 1993). These findings matched with this study. Besides, we can use CT scan to modify the location, size and diameter of nidus. The maximum amount of absorbed energy during ILP is very important (It is adjusted with the diameter of nidus) because the overlap energy would be harmful to healthy issues. (in osteoid osteoma there is no need to remove the reactional bone) Considering the size of osteoid osteoma that is less than 1 centimeter (Carnesale 1998, Rogers 1993, Radcliffe *et al.* 1998) there would be no need to perform the process more than one time. In some studies they used MRI instead of CT to guide the fiber and it was successfully done (Wacker *et al.* 1998, Sequeiros *et al.* 2003).

Three factors must be concerned when evaluating the efficacy of the ILP:

1- Decrease the amount of pain, 2- Destruction of lesion after the process, 3- No recurrence in long term follows up. As mentioned previously, the pain relief occurred promptly 1 day after the procedure that matched with most of the similar published studies and showed the efficiency of this procedure in reducing the symptoms of the lesion. For example, the report of Witt and colleagues (2000) showed that the pain relief was seen in most of the patients and less than 30% of them felt little pain after the procedure (Witt *et al.* 2000). Another study showed that there was completely no sign of disease symptoms after 3 weeks and 3 months in all patients that matched with our study (Sequeiros *et al.* 2003). Other studies also showed that all patients except one were recovered completely (De Friend *et al.* 2003, Gangi *et al.* 1998d) and during 4-23 months follow up, they showed no recurrence (De Friend *et al.* 2003).

We controlled the location of the lesion with CT scan and radiography and it showed the complete destruction of nidus that matched with most of the studies (Gangi *et al.* 1998a, Gangi, *et al.* 1997c, Sequeiros *et al.* 2003, Witt *et al.* 2000, De Friend *et al.* 2003, Gangi *et al.* 1998d) In fact destruction of the tumor was the reason of the extinction of the symptoms; it was confirmed with radiographies that were done to control the patients. This study showed no recurrence in one year follow up which matched with other studies (Sequeiros *et al.* 2003). In addition, the post complications of processes are another problem which should be considered.

The success of ILP is another aspect which is presented with disappearing of signs and eradications of tumor after the processes. As mentioned before there's no technical limitation which is also compatible with other reports. This is the priority of procedure. In some cases the lesions had not been eradicated completely and the patients required another ILP. This problem is due to the incomplete eradication of the lesion or incorrect insertion of the laser probe. This may be solved and treated through performing another operation.

In conclusion the procedure is a safe and effective method for patients and could be applied for proper cases.

## REFERENCES

1. Adams J.C. and Hamblen D.L. (1995). Local Affection of bones. *Outlines of orthopedics*. Adams, J.C., Hamblen D.L. (eds.). Churchill & Livingston, New York, 101.
2. Assoun J., Railhac J.L., Bonneville P., et al. (1993) Osteoid Osteoma: percutaneous resection with CT guidance. *Radiology* **188**: 541-54.
3. Carnesale P.G. (1998). Benign tumors of bone. *Campbell's operative orthopedics*. Canale T.S. (ed.) *Mosby, St Louis* 691-692.
4. Cayli S.R., Beskonakli E., Gunce S., Guc T. (1998). Osteoid osteoma of the frontal bone.

- Case report. *Zentralbl Neurochir.* **59**: 132-4.
5. De Friend D.E., Smith S.P., Hughes P.M. (2003). Percutaneous laser photocoagulation of osteoid osteomas under CT guidance. *Clin. Radiol.* **58**:222-6.
  6. Gangi A., Dietmann J.L., Dosh J.C., Mortazavi R. (1995). Percutaneous laser photocoagulation of Osteoid Osteoma. Under CT- guidance. *Radiology*, **199**: 331-335.
  7. Gangi A., Gasser B., De Unamuno S., Fogarrassy E., Fuchs C., Siffert P., Dietemann J.L. Roy C. (1997a). New Trends in Interstitial Laser Photocoagulation of Bones. *Semin Musculoskelet Radiol* **1**: 331-338.
  8. Gangi A., Dietemann J.L., Gasser B., Mortazavi R., Dosch J.C., Dupuis M., Durckel J., Roy C. (1997b) Percutaneous Laser Photocoagulation of Osteoid Osteomas. *Semin. Musculoskelet. Radiol.*, **1**: 273-280.
  9. Gangi A., Dietemann J.L., Gasser B., Mortazavi R., Brunner P., Mourou M.Y., Dosch J.C., Durckel J., Marescaux J., Roy C. (1997c) Interstitial laser photocoagulation of osteoid osteomas with use of CT guidance. *Radiology*. **203**:843-8.
  10. Gangi A., Dietemann J.L., Guth S., Vinclair L., Sibilila J., Mortazavi R., Steib J.P., Roy C. (1998a). Percutaneous laser photocoagulation of spinal osteoid osteomas under CT guidance. *Am. J. Neuroradiol.*, **19**: 1955 – 1958.
  11. Gangi A., Dietemann J.L., Gasser B., Guth S., Unamuno S., Fogarassi E., Fuchs C., Sieffert P., Roy C. (1998b). Interventional radiology with laser in bone and joint. *Radiol. Clin. North Am.*, **3**: 547-559.
  12. Gangi A., Dietemann J.L., Mortazavi R., Pflieger D., Kauff C., Roy C. (1998c) CT-guided interventional procedures for pain management in the lumbosacral spine. *Radiographics*. **8**: 621-33.
  13. Gangi A., Dietemann J.L., Clavert J.M., Dodelin A., Mortazavi R., Durckel J., Roy C. (1998d). Treatment of osteoid osteoma using laser photocoagulation. A propose of 28 cases. *Rev. Chir. Orthop. Reparatrice Appar. Mot.* **84**: 676-84.
  14. Mazayer J.F., Kohler R., Bossad D. (1991) Osteoid osteoma: CT –guided percutaneous treatment. *Radiology*. **181**: 269-71.
  15. Radcliffe S.N., Walsh H.J., Carty H. (1998). Osteoid osteoma: the difficult diagnosis. *Eur.J. Radiol.* **28**: 67-79.
  16. Rogers L.F. (1993). Bone tumors and related conditions. Paul and juhl's Essentials of Radiologic imaging. Juhl J.H., Crummy A. B. (eds.). *J. B. Lippincott Company. Phyladelphia* . 140- 141.
  17. Sequeiros R.B., Hyvonen P., Sequeiros A.B., Jyrkinen L., Ojala R., Klemola R., Vaara T., Tervonen O. (2003). MR imaging-guided laser ablation of osteoid osteomas with use optical instrument guidance at 0.23 T. *Eur. Radiol.* **13**:2309-14.
  18. Towbin R., Kaye R., Meza M.P., Pollock A.N., Yaw K., Moreland M. (1995) Osteoid osteoma: percutaneous excision using a CT-guided coaxial technique. *Am. J. Roentgenol.* **164**: 945-949.
  19. Wacker F.K., Cholewa D., Roggan A., Schilling A., Waldschmidt J., Wolf K.J. (1998). Vascular lesions in children: percutaneous MR imaging-guided interstitial Nd:YAG laser therapy-preliminary experience. *Radiology*, **208**: 789-794.
  20. Witt J.D., Hall-Craggs M.A., Ripley P., Cobb J.P., Bown S.G. (2000). Interstitial laser photocoagulation for the treatment of osteoid osteoma. *J. Bone. Joint. Surg. Br.* **82**:1125-8.