

Cytoprotective effects of amifostine and melatonin against radiation-induced oral mucositis in rats

D. Park¹, D.H. Kim^{1*}, W.T. Kim¹, J.H. Nam¹, D.C. Kim¹, K.H. Lee¹, Y.K. Ki², J.H. Joo², H.S. Jeon²

¹Department of Radiation Oncology, Biomedical Research Institute, Pusan National University Hospital and Pusan National University School of Medicine, Busan, Republic of Korea

²Department of Radiation Oncology, Pusan National University Yangsan Hospital and Pusan National University School of Medicine, Yangsan, Republic of Korea

ABSTRACT

► Original article

***Corresponding author:**
Donghyun Kim, MD, Ph.D.,
E-mail: dh2372@pusan.ac.kr

Received: June 2022

Final revised: November 2022

Accepted: January 2023

Int. J. Radiat. Res., April 2023;
21(2): 261-265

DOI: 10.52547/ijrr.21.2.12

Keywords: Amifostine, melatonin, radiation-induced oral mucositis, rats.

Background: Amifostine (AMI) protects against radiotherapy (RT)-induced toxicities and melatonin (MEL) is a potent free radical scavenger. This study was performed to investigate the protective effects of AMI and MEL on radiation-induced oral mucositis (ROM). **Materials and Methods:** Thirty female Sprague-Dawley rats were randomly divided into five groups as follows: the control (Cont), RT alone (RT), RT+AMI, RT+MEL, and RT+AMI+MEL. RT groups were irradiated with a single dose of 15 Gy to the head. AMI (200 mg/kg) and MEL (100 mg/kg) were administered intraperitoneally 1 hour before radiation exposure. Changes in body weights and histology in irradiated tongue tissues were analyzed 10 days after exposure. **Results:** AMI and/or MEL treatment significantly prevented irradiation-induced body weight loss and promoted epithelial cell proliferation. Mean epithelial thickness was markedly higher in the AMI+MEL group ($73.9 \pm 9.7 \mu\text{m}$) than in the RT group ($28.8 \pm 13.9 \mu\text{m}$) ($P < 0.001$), and Ki67 expression was significantly higher in AMI, MEL, and AMI+MEL groups than in the RT group ($p < 0.001$). Terminal deoxynucleotidyl transferase dUTP nick end labeling (TUNEL) revealed that AMI+MEL treatment significantly inhibited radiation-induced apoptosis in irradiated epithelium ($p = 0.006$). **Conclusion:** AMI and MEL administrations similarly protected animals from ROM and, when co-administered, had additive effects.

INTRODUCTION

Radiotherapy (RT) plays a pivotal role in the management of head and neck cancer (HNC), but indirect damage to nearby tissues inevitably leads to side effects (1). Radiation-induced oral mucositis (ROM) is a dose-limiting acute toxicity of RT in HNC patients and markedly reduces quality of life due to dysphagia, bleeding, malnutrition, and high hospitalization rates. Furthermore, ROM may interrupt RT schedules and adversely affect prognosis (2). However, despite considerable technologic advancements, no effective preventative intervention has been devised for ROM (3).

Reactive oxygen species (ROS) generated by irradiation cause DNA damage, which leads to loss of mucosal surface membrane integrity (4). Hydroxyl radicals (OH•), hydrogen peroxide (H₂O₂), and the superoxide anion (O₂⁻) are produced by the radiolysis of water, and the activities of the antioxidant enzymes superoxide dismutase (SOD), catalase, and glutathione peroxidase (GPX) are increased by radiation-induced oxidative stress (5,6).

Amifostine (AMI, WR-2721) is the only FDA-approved protective compound for the

prevention of xerostomia after RT and is also a ROS scavenger (7). However, its use is limited by side effects, which include nausea, emesis, and hypotension (8). On the other hand, melatonin (MEL, N-acetyl-5-methoxytryptamine) is a major product of the pineal gland and has free radical scavenging and antioxidant activities and anti-inflammatory effects. Moreover, the toxicity of MEL is very low (9), and in rat models of RT-induced uterine tissue injury, MEL was reported to be more potent than AMI (10).

In this study, we examined the cytoprotective effects of AMI and MEL on ROM in rats, and given the wide safety margin of MEL, we also investigated the effects of combined AMI and MEL treatment.

MATERIALS AND METHODS

Study design

All experiments were conducted after obtaining approval from our institutional animal ethics committee (approval number: 2022-200, dated 15th February 2022) and were performed as per "Guidelines for the Care and Use of Laboratory Animals" issued by the National Institutes of Health.

Thirty female Sprague-Dawley rats (125 - 143 g, 6 weeks old) were used in the study. Animals were housed in polypropylene cages in a temperature and humidity-controlled environment with free access to sterile water and food and allocated to five groups (6 rats/group) as follows; the control group (Cont) and the RT, RT+AMI, RT+MEL, and RT+AMI+MEL groups.

Rats in the RT+AMI, RT+MEL, and RT+AMI+MEL groups were administered a single dose of AMI (200 mg/kg, Sigma Chemical Co, St. Louis, USA) and/or MEL (100 mg/kg, Sigma Chemical Co, St. Louis, USA) intraperitoneally (i.p.) 1 hour before irradiation^(9,11). All procedures were performed under alfaxalone (20 mg/kg, i.p.)/xylazine (3.9 mg/kg, i.p.) anesthesia. Animals were followed for 10 days, and body weights were recorded every 3 days.

Irradiation

With a rat restrained on a treatment table in the prone position, a single dose of 15 Gy was delivered to the head at 5 Gy/min using an AP-PA 6 MV photon beam generated by a linear accelerator (Versa HD, Elekta, Stockholm, Sweden). To ensure uniform dose distribution, a tissue-equivalent bolus was placed on the head. Animals were closely monitored after irradiation until they recovered from anesthesia.

Histopathology

After sacrifice on day 10, tongues were dissected longitudinally in the median plane, fixed in 10% buffered formalin for 24 h, embedded in paraffin, sectioned at 4- μ m, and stained with hematoxylin and eosin (H&E). Sections were imaged at x200, and epithelial thicknesses were measured in four non-overlapping microscopic fields.

Immunohistochemistry

The immunohistochemical study was performed using paraffin-embedded tissue sections. Deparaffinized sections were incubated in a blocking solution containing Ki-67 (1:200; Abcam, ab16667) antibody overnight at 4°C, washed in TBS containing 0.025% Triton, and incubated for 2 hours at room temperature in HRP Peroxidase Polymer Detection Kit (MP-7401-15, Vector Laboratories, Burlingame, CA) solution. Diaminobenzidine (DAB) was used as the chromogen to assess antigen intensities and quantities by light microscopy. In Ki-67 (a marker of epithelial cell proliferation) stained sections, numbers of Ki-67 positive cells per field at 200 \times were counted using a Nikon Eclipse TE 200 microscope equipped with OptiView image analysis software (Korea Lab Tech, Seongnam, Korea). Results are presented as average counts of four non-overlapping sections of six rats/group.

TUNEL assay

Apoptosis is a primary pathologic finding of mucositis, and degrees of apoptosis and mucositis severities are known to be positively related.

Apoptotic nuclei in paraffin-embedded tissue sections were detected using a TUNEL (terminal deoxynucleotidyl transferase dUTP nick end labeling) assay kit (ab206386, HRP-DAB, Abcam, Cambridge, MA). At points of DNA cleavage, DAB reacts with HRP-labeled samples to generate a brown color. The analysis was performed by counting numbers of TUNEL-positive cells per field at 200 \times in 4 randomly selected non-overlapping fields.

Statistical analysis

Results are expressed as means \pm SEMs (standard errors of means). One way analysis of variance (ANOVA) followed by Dunnett's test was used to determine the significances of intergroup differences. The analysis was conducted using online software (IBM SPSS Statistics Version 26.0; IBM Corp., Armonk, NY, USA), and statistical significance was accepted for single-sided P values of < 0.05.

RESULTS

Effects of treatments on body weights

No mortality occurred during the experiment period. The Control and RT+AMI+MEL groups gained weight over the 9 day follow-up period. The RT, RT+AMI, and RT+MEL groups lost weight on day 3, but from days 6 to 9, all groups showed progressive increases in body weight (Figure 1). However, the RT+AMI+MEL group showed a more rapid increase in weight than the RT, RT+AMI, and RT+MEL groups. Furthermore, all, except the rats in the RT+AMI+MEL groups ($p = 0.643$) had significantly lower mean body weights than the controls on day 10.

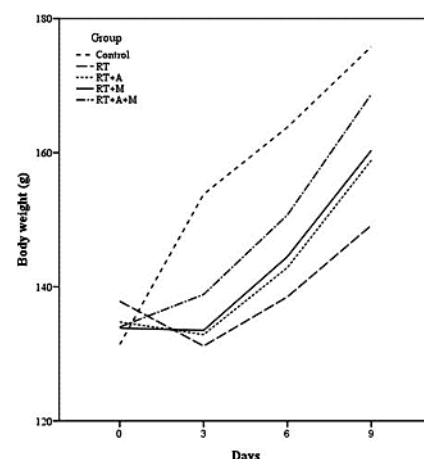


Figure 1. Mean body weights of the study groups from day 0 to day 10. Mean body weights in the control and RT+AMI+MEL groups increased on day 3, whereas the RT, RT+AMI, and RT+MEL groups showed weight losses. Furthermore, the RT, RT+AMI, and RT+MEL groups had significantly lower mean body weights than the control group on day 10 ($P < 0.05$).

Histopathology

At the end of the study, extensive mucosal lining ulceration, inflammatory infiltration, and

vasodilation were observed in submucosa in the RT group. In contrast, epithelium was relatively preserved, and blood vessels were more numerous in the RT+AMI and RT+MEL groups. However, epithelial layers were better preserved in the RT+AMI+MEL group, with fewer inflammatory cells, and resembled those in the control group (figure 2A).

Irradiation reduced epithelial layer thickness in the RT group, but this was markedly mitigated in the AMI or MEL groups. Mean epithelium thicknesses in the RT, RT+AMI, and RT+MEL groups were 28.8 ± 13.9 , 40.8 ± 6.2 ($p=0.208$), and 40.2 ± 7.0 ($p=0.269$), respectively, and no significant difference was observed between the RT and RT+AMI or RT+MEL groups. Mean epithelium thickness in the RT+AMI+MEL group was 73.9 ± 9.7 μm , which was significantly greater than mean thicknesses in the RT, RT+AMI, or RT+MEL groups ($P < 0.001$) (figure 2B).

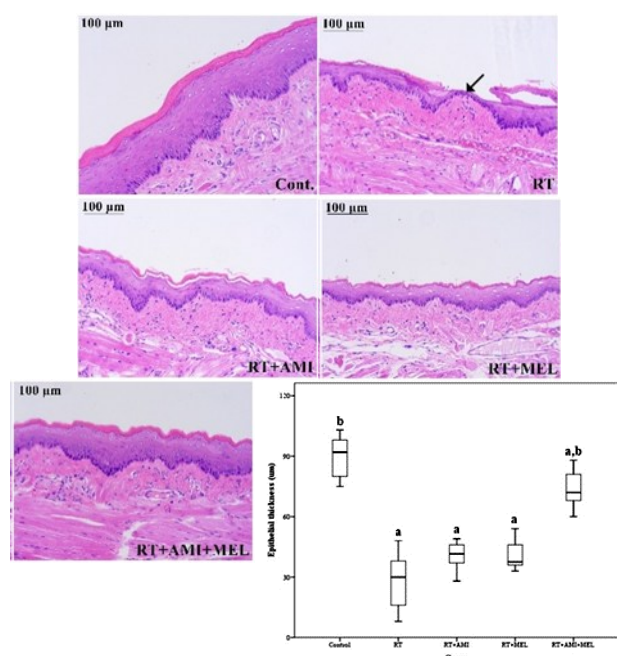


Figure 2. Histopathologic images of tongue mucosa 10 days after irradiation (H&E staining, x200). Animals in the RT group showed mucosal ulceration, submucosal vasodilation, and epithelial atrophy (arrow), but administrations of AMI, MEL, or AMI+MEL mitigated these changes (A, Scale bar = 100 μm).

Mean epithelial thickness was markedly greater in the RT+AMI+MEL group (73.9 ± 9.7 μm) than in the RT group (28.8 ± 13.9 μm) (B). Results are expressed as means \pm SEMs. aP < 0.05 versus treatment-naïve controls, bP < 0.05 versus the RT group.

Ki67 immunohistochemistry

Immunostaining with specific antibodies against Ki-67 revealed a significantly lower number of proliferating cells in the RT group (6.5 ± 3.1) than in the other groups ($p < 0.05$). Most of the positive cells were located at the germinal layer of squamous epithelium. No significant difference was observed between the RT+AMI, RT+MEL, and RT+AMI+MEL groups (26.9 ± 8.5 , 27.7 ± 8.0 , and 35.1 ± 9.3 , respectively) (figure 3).

TUNEL assay

The mean number of TUNEL-positive cells was significantly greater in the RT group than in the RT+AMI+MEL group (31.5 ± 9.6 vs. 13.4 ± 4.1 , $p = 0.006$), but no significant difference was observed between the RT group and the RT+AMI (22.5 ± 6.8) or RT+MEL (20.7 ± 6.6) groups (figure 4).

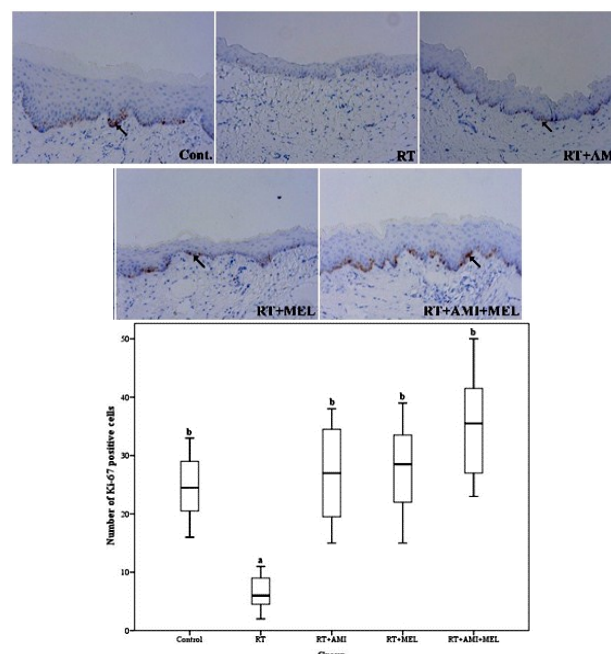


Figure 3. Immunohistochemical staining for Ki67 (x200) in radiation-induced oral mucositis (A). Ki67 expressions (arrow) were significantly higher in the RT+AMI, RT+MEL, and RT+AMI+MEL groups (26.9 ± 8.5 , 27.7 ± 8.0 , and 35.1 ± 9.3 , respectively) than in the RT group (6.5 ± 3.1) (B). Results are expressed as means \pm SEMs. aP < 0.05 versus treatment-naïve controls, bP < 0.05 versus the RT group.

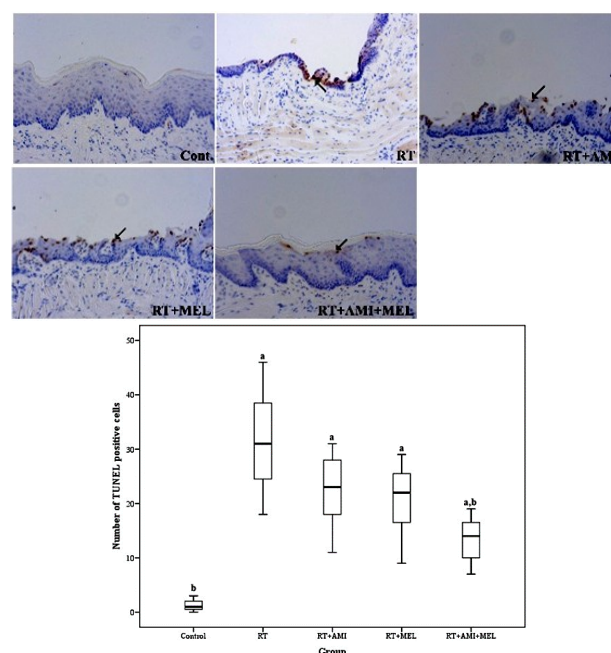


Figure 4. TUNEL staining (x200) in radiation-induced oral mucositis (A). TUNEL-positive cell (arrow) numbers were higher in the RT group than in the RT+AMI, RT+MEL, and RT+AMI+MEL groups (31.5 ± 9.6 vs. 22.5 ± 6.8 , 20.7 ± 6.6 , and 13.4 ± 4.1 , respectively) (B). Results are expressed as means \pm SEMs. aP < 0.05 versus treatment-naïve controls, bP < 0.05 versus the RT group.

DISCUSSION

Our results show that the administration of AMI and/or MEL before RT significantly ameliorated mucosal reactions in rats. No significant difference was observed between the effects of AMI and MEL, but when co-administered, they had an additive effect on body weights and histologic findings, which is an encouraging finding given that no pharmacologic agent is available for ROM.

Radiation generates intracellular ROS, which damage DNA and cause genomic instability and cell death or senescence⁽¹²⁾. Therefore, mitigators of radiation-induced damage target components of the DNA-damage signaling pathway, such as free radical scavengers, anti-apoptotic proteins, or DNA repair promoters⁽¹³⁾.

Attenuators of oxidative stress and inflammation, such as SOD, catalase, and GPX, can alleviate tissue toxicity. SOD catalyzes the dismutation of the superoxide radicals to generate H₂O₂ or oxidases, such as xanthine oxidase. Alternatively, superoxide radicals are reduced to water by catalase or GPX, the latter of which plays an essential protective role against membrane lipid peroxidation⁽¹⁴⁾.

Agents that prevent ROM are urgently required to improve treatment efficacy by preventing treatment interruption or cessation. In 2004, the FDA approved the use of palifermin, a recombinant human keratinocyte growth factor, to reduce the rate and duration of grade 3 or 4 oral mucositis. However, its use in the United States has been limited to patients with a hematologic malignancy undergoing intensive chemotherapy and scheduled for hematopoietic stem cell transplantation. Unfortunately, palifermin has been reported to have no effect on analgesic use, patient-reported pain, or chemoradiotherapy compliance in randomized trials on locally advanced HNC, and thus its use for managing HNC is limited^(15,16).

AMI is a phosphorylated aminothioliol prodrug activated by membrane-bound alkaline phosphatase to its active metabolite, WR-1065⁽¹⁷⁾. AMI provides broad-spectrum cytoprotection and selectively protects normal tissues from acute and late radiation damage without reducing the cytotoxic effect of radiation on tumor cells. Normal cells have higher alkaline phosphatase activity in the plasma membrane, better vascular supply, and a higher pH than tumor cells⁽¹⁸⁾. Furthermore, it has been reported that a pH of 7.4 is optimum for the dephosphorylation and uptake of AMI by cells⁽¹³⁾, and that AMI concentration is ~100 times higher in normal cells than in tumor cells⁽¹⁹⁾.

Eleven of 21 prospective HNC trials reported that AMI administration significantly reduced the rate of mucositis of grade <3⁽¹³⁾. In the largest of these studies, 303 previously untreated HNC patients were randomized to receive RT alone or RT plus 200 mg/

m² of AMI i.v. 15–30 min before radiotherapy, and there was no statistically significant difference in ROM between the two groups⁽²⁰⁾. In a meta-analysis of 17 trials, AMI reduced the rate of grade 3/4 mucositis (risk ratio [RR] = 0.72, P < 0.00001), but subgroup analyses revealed significant reductions only in patients treated with RT alone (RR = 0.49, p = 0.03) and patients administered AMI intravenously (RR = 0.52, p = 0.002). Furthermore, patients who were treated with concurrent chemoradiation and subcutaneously administered AMI failed to ameliorate ROM⁽⁷⁾. In situations where the effect of AMI on mucositis is unclear, co-treatment with other agents appears to be required.

The protective effect of MEL against ionizing radiation has been described in many studies. In vitro, MEL neutralized OH• activity 5 times more effectively than glutathione and that of peroxy radicals (ROO•) twice as effectively as vitamin E^(14, 21). In addition, MEL has been reported to mitigate the severity of oral mucositis and associated pain in HNC patients receiving RT⁽²²⁾, and it has been suggested that MEL might increase the radiosensitivity of tumor cells⁽²³⁾. Thus, a comparison of MEL and AMI seemed appropriate based on the reported potent radioprotective effect, low toxicity, and high tissue penetration of MEL. However, in the present study, no significant difference was found between the effects of AMI and MEL on ROM, though they were found to have an additive effect.

The present study has a number of limitations that warrant consideration. First, the single dose of 15 Gy used may not be clinically relevant in the context of HNC. Second, rats were irradiated with a single high dose based on approaches used in other animal models. Therefore, we recommend that fractionated radiation protocols be adopted in future studies. Third, AMI (200 mg/kg) and/or MEL (100 mg/kg) were administered 1h before irradiation, as described in previous studies^(9,11). Thus, we also recommend that studies be undertaken using different AMI and/or MEL doses and administration schedules to investigate their radioprotective effects.

CONCLUSIONS

AMI or MEL administration before irradiation similarly ameliorated the effects of ROM and, when co-administered, had additive effects. These findings suggest that co-treatment with AMI and MEL could be used to protect against ROM during RT for HNC.

ACKNOWLEDGEMENT

None.

Conflicts of interest: The authors have no conflict of interest to declare.

Funding: This work was supported by the National Research Foundation of Korea(NRF) grant funded by

the Korea government(MSIT) (No. 2021R1G1A 1091669).

Ethical consideration: This study was approved by the pusan national university hospital animal ethics committee (approval number : 2022 -200, dated 15th February 2022).

Author contribution: All the authors have equally contributed in conceptualization, analysis, evaluation, investigation, data curation and in writing this research paper.

REFERENCES

- Porceddu SV and Haddad RI (2017) Management of elderly patients with locoregionally confined head and neck cancer. *Lancet Oncol*, **18**: e274-e283.
- Sroussi HY, Epstein JB, Bensadoun RJ, et al. (2017) Common oral complications of head and neck cancer radiation therapy: Mucositis, infections, saliva change, fibrosis, sensory dysfunctions, dental caries, periodontal disease, and osteoradionecrosis. *Cancer Med*, **6**: 2918-2931.
- Rosenthal DI and Trotti A (2009) Strategies for managing radiation-induced mucositis in head and neck cancer. *Semin Radiat Oncol*, **19**: 29-34.
- Sheng-Tanner X, Bump EA, Hedley DW (1998) An oxidative stress-mediated death pathway in irradiated human leukemia cells mapped using multilaser flow cytometry. *Radiat Res*, **150**: 636-647.
- Kirkman HN, Rolfo M, Ferraris AM, Gaetani GF (1999) Mechanisms of protection of catalase by NADPH. Kinetics and stoichiometry. *J Biol Chem*, **274**: 13908-13914.
- Flohe L, Gunzler WA, Schock HH (1973) Glutathione peroxidase: a selenoenzyme. *FEBS Lett*, **32**: 132-134.
- Gu J, Zhu S, Li X, Wu H, Li Y, Hua F (2014) Effect of amifostine in head and neck cancer patients treated with radiotherapy: A systematic review and meta-analysis based on randomized controlled trials. *PLoS One*, **9**: e95968.
- Rades D, Fehlauer F, Bajrovic A, et al. (2004) Serious adverse effects of amifostine during radiotherapy in head and neck cancer patients. *Radiation Oncol*, **70**: 261-264.
- Sener G, Jahovic N, Tosun O, et al. (2003) Melatonin ameliorates ionizing radiation-induced oxidative organ damage in rats. *Life Sci*, **74**: 563-572.
- Seker U, Aktas A, Nergiz Y, et al. (2020) Investigation of the protective effects of melatonin, amifostine (WR-2721), and N-acetylcysteine on radiotherapy-induced uterine tissue injury in rats. *Int J Radiat Res*, **18**: 791-798.
- Cosar R, Yurut-Caloglu V, Eskioçak S, et al. (2012) Radiation-induced chronic oxidative renal damage can be reduced by amifostine. *Med Oncol*, **29**: 768-775.
- Hall EJ and Giaccia AJ (2019) Radiobiology for the radiologist. Wolters Kluwer Co. Philadelphia, USA.
- King M, Joseph S, Albert A, et al. (2020) Use of amifostine for cytoprotection during radiation therapy: a review. *Oncology*, **98**: 61-80.
- Baldwin WS and Barrett JC (1998) Melatonin Attenuates Hydrogen Peroxide Toxicity in MCF7 Cells Only at Pharmacological Concentrations. *Biochem Biophys Res Commun*, **250**: 602-605.
- Henke M, Alfonsi M, Foa P, et al. (2011) Palifermin decreases severe oral mucositis of patients undergoing postoperative radiochemotherapy for head and neck cancer: A randomized, placebo-controlled trial. *J Clin Oncol*, **29**: 2815-2820.
- Le QT, Kim HE, Schneider CJ, et al. (2011) Palifermin reduces severe mucositis in definitive chemoradiotherapy of locally advanced head and neck cancer: A randomized, placebo-controlled study. *J Clin Oncol*, **29**: 2808-2814.
- Kaldir M, Cosar-Alas R, Cermik TF, et al. (2008) Amifostine use in radiation-induced kidney damage. Preclinical evaluation with scintigraphic and histopathologic parameters. *Strahlenther Onkol*, **184**: 370-375.
- Hensley ML, Hagerty KL, Kewalramani T, et al. (2009) American society of clinical oncology 2008 clinical practice guideline update: use of chemotherapy and radiation therapy protectants. *J Clin Oncol*, **27**: 127-145.
- Yuhás JM (1980) Active versus passive absorption kinetics as the basis for selective protection of normal tissues by S-2-(3-aminopropylamino)-ethylphosphorothioic acid. *Cancer Res*, **40**: 1519-24.
- Brizel DM, Wasserman TH, Henke M, et al. (2000) Phase III randomized trial of Amifostine as a radioprotector in head and neck cancer. *J Clin Oncol*, **18**: 3339-45.
- Haghi-Aminjan H, Farhood B, Rahimifard M, et al. (2018) The protective role of melatonin in chemotherapy-induced nephrotoxicity: a review of non-clinical studies. *Expert Opin Drug Metab Toxicol*, **14**: 937-950.
- Elsabagh H, Moussa E, Mahmoud S, et al. (2020) Efficacy of Melatonin in prevention of radiation-induced oral mucositis: A randomized clinical trial. *Oral Dis*, **26**: 566-572.
- Mozdarani H, Azadbakht O, Ghorbainan Klachai S, et al. (2021) Modulating effects of famotidine and melatonin on high dose radiation induced cell lethality in normal human and cancer cell lines. *Int J Radiat Res*, **19**: 457-463.

