

Meta-analysis of the clinical effectiveness of abdominal aortic balloon occlusion for pelvic tumor treatment under color doppler ultrasound

Z. Zhang, D. Wang, X. Zhang, J. Feng, Q. Feng*

Department of Department of Orthopedics, The Fourth Hospital of Hebei Medical University, Shijiazhuang, Hebei 050011, P. R. China

ABSTRACT

► Original article

*Corresponding author:

Qi Feng, Ph.D.,

E-mail: qi20150601@163.com

Received: February 2023

Final revised: April 2023

Accepted: May 2023

Int. J. Radiat. Res., July 2023;
21(3): 405-411

DOI: 10.52547/ijrr.21.3.8

Keywords: color Doppler ultrasound, abdominal aortic balloon occlusion, pelvic tumor, meta-analysis.

Background: This paper aimed to assess the clinical effects of abdominal aortic balloon occlusion (AABO) under color Doppler ultrasound guidance in treating pelvic tumors. **Materials and Methods:** Various databases, which contained China National Knowledge Infrastructure, Wanfang Data, Chinese Biomedical Literature Database, PubMed, Excerpta Medica Database (Embase), and Cochrane Library, were used for searching randomized controlled studies published from 2010 to present. The quality of the literature was assessed using the Newcastle-Ottawa Scale (NOS). Outcome measurements included intraoperative blood loss, transfusion volume, operative time, hospital stay, recurrence, and postoperative complications. **Results:** Six reference articles were obtained, including 223 patients who underwent AABO and 300 patients who did not. The NOS score was greater than 7 points in both groups. Meta-analysis showed that the intraoperative blood loss, transfusion volume, and surgery duration of patients undergoing pelvic tumor resection with AABO were all reduced (95% confidence interval (CI): -1504.53~-762.10, $P<0.00001$; 95% CI: -902.22~-575.45, $P<0.00001$; 95% CI: -80.20~-26.54, $P<0.0001$). No difference was discovered in the occurrence of postoperative complications, including nerve injury (95% CI: 0.30~1.34, $P=0.23$) and urethral injury (95% CI: 0.19~1.97, $P=0.41$) between both groups. The incidence of wound infection was relatively low (95% CI: 0.22~0.81, $P=0.010$). Additionally, no difference was discovered in hospital stay (95% CI: -6.85~0.79, $P=0.12$) and recurrence (95% CI: 0.45~1.53, $P=0.12$) between both groups ($P>0.05$). **Conclusion:** AABO under color Doppler ultrasound guidance can reduce intraoperative blood loss, transfusion volume, and operative time during pelvic tumor resection and can also reduce the incidence of some postoperative complications.

INTRODUCTION

Pelvic tumors are primary bone tumors that are deep and large in size, and the main manifestation is a pelvic mass. According to the organization and embryogenesis, pelvic tumors are divided into four basic types, including mesenchymal tissue-derived tumors, urogenital tumors, neurogenic tumors and tumors of germ cell origin, and about 10% of tumors could not be classified ⁽¹⁾. During the process of excision, there is a high risk of damaging nerves and blood vessels, making the procedure risky ⁽²⁾.

Studies have shown that intraoperative bleeding is a significant factor affecting the excision of pelvic tumors. Increased bleeding during surgery requires large amounts of blood transfusions, which can lead to complications and even death for the patient ^(3,4). Additionally, excessive bleeding during surgery can cause blurry vision, longer surgical times, and affect the identification of tumor tissue and surrounding

tissues, thereby increasing the risk of intraoperative complications ⁽⁵⁾. Therefore, intraoperative bleeding, blood transfusion volume, as well as the incidence of complications are crucial factors that influence the prognosis of patients with pelvic tumors undergoing excision surgery.

Abdominal aortic balloon occlusion (AABO) is an effective method to control intraoperative bleeding and blood transfusion volume by directly blocking arterial blood supply ^(6,7), and under the guidance of color Doppler ultrasound, it has become an effective treatment for pelvic tumors ⁽⁸⁾. Therefore, this study evaluated the therapeutic effect of AABO under the guidance of color Doppler ultrasound on pelvic tumors. Our study demonstrated that AABO under color Doppler ultrasound guidance can reduce intraoperative blood loss, transfusion volume, and operative time during pelvic tumor resection and can also reduce the incidence of some postoperative complications.

MATERIALS AND METHODS

Retrieval methods

Using computer retrieval of databases which contained China National Knowledge Infrastructure (CNKI), Wanfang, Chinese biomedical literature, PubMed, Excerpta Medica Database (Embase), as well as Cochrane, the retrieval time was specified as 2010 to the present. The keywords were "Balloon occlusion of abdominal aorta," "pelvic tumor," and "color doppler ultrasound," and the search were done both in English and Chinese.

Inclusion criteria: (1) Published literature. (2) Literature research type is randomized controlled trial. (3) Patients diagnosed with pelvic tumors. (4) Observation group underwent AABO, and control group not.

Exclusion criteria: (1) Review, reports. (2) Literature with incomplete data. (3) Literature on repetitive research. (4) Literature in languages other than Chinese or English.

Selection

Two researchers independently extracted and screened literature data, excluded literature that did not in line with the inclusion criteria, and conducted a full-text reading of the included literature. On the grounds of the inclusion as well as exclusion criteria, the literature was determined, and data were extracted from the included literature, including general information about the authors and outcome indicator data (including intraoperative blood loss, intraoperative transfusion volume, surgery duration, length of hospital stay, and incidence of complications).

Quality evaluation

The Newcastle-Ottawa Scale (NOS), developed by the University of Newcastle (Canada) and the University of Ottawa (Australia), was used for quality assessment. A lower score indicated poorer quality of the literature, which was not conducive to meta-analysis.

Statistical analysis

Review Manager (RevMan, Cochrane, UK) 5.3 was used for statistical analysis. All the literatures were measured for heterogeneity using the I^2 test with degrees of freedom correction. The random-effects model was implemented if heterogeneity existed ($I^2 > 50\%$). Fixed-effects model was adopted for when heterogeneity did not ($I^2 \leq 50\%$). $P < 0.05$ was regarded as statistical significance. Publication bias of the included literature was identified using a funnel plot. Sensitivity analysis was implemented by sequentially excluding each included literature and then combining the effect size, to explore the degree of influence of the study on the combined effect. Each meta-analysis was performed using different statistical models. If the change in 95% confidence

interval (CI) and combined effect size was small after using different statistical models, the results were considered stable. Quantitative data such as intraoperative bleeding volume, intraoperative transfusion volume, operative time, and length of hospital stay were exhibited as standardized mean differences (SMD) with their corresponding 95% CI. Count data such as postoperative complication rate and recurrence were exhibited as odds ratios (OR) with their corresponding 95% CI.

RESULTS

Screening process

A total of 346 relevant literature and manual retrieval literature were retrieved in this study. Through eliminating 31 duplicate literatures, 187 irrelevant or incomplete original data and the documents that do not in line with the inclusion criteria, 6 pieces of literature were finally chosen, and the screening procedure was shown in figure 1.

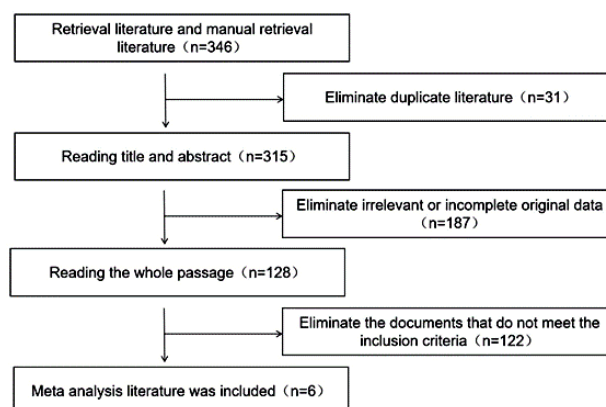


Figure 1. Flow chart of the literature search and study selection. Six studies were contained in this meta-analysis. N: Number.

Basic characteristics

Six articles included in this paper were all randomized controlled studies, involving 523 patients who underwent pelvic tumor resection. Among them, 223 patients underwent AABO were divided into the observation group and 300 patients did not undergo this procedure were considered as the control group. The basic characteristics of the 6 articles contained in this study were detailed in table 1. The NOS scoring criteria were used for evaluation, and the NOS scores were all greater than or equal to 7, indicating that the quality of the included literature was high and the meta-analysis was applicable.

Comparison of intraoperative blood loss

Intraoperative blood loss was analyzed in 6 included articles (control: observation = 300:223). The heterogeneity determined in intraoperative blood loss between groups was $I^2 = 76\%$, thus the random effects model was implemented for analysis. The findings presented a significant decrease in

intraoperative blood loss in the observation group relative to the control (mean difference (MD) = -1133.31, 95% CI: -1504.53~-762.10, $P < 0.00001$), as displayed in figure 2.

Comparison of intraoperative transfusion volume

Intraoperative blood transfusion volume of the included 4 articles was analyzed (control: observation = 234:141). There was no heterogeneity detected in intraoperative transfusion volume between groups ($I^2=0\%$), thus the fixed effects model was chosen. The findings presented a significant decrease in intraoperative transfusion volume in the observation group relative to the control (MD=-738.83, 95% CI: -902.22~-575.45, $P < 0.00001$). These findings were presented in figure 3.

Comparison of surgery duration

Operation time was analyzed in the six included articles (control: observation = 300:223). The heterogeneity was determined in surgery duration between groups ($I^2=78\%$), thus the random effects model was chosen. The findings presented a significant decrease in surgery duration in the observation group relative to the control (MD=-53.37, 95% CI: -80.20~-26.54, $P < 0.0001$). These findings were presented in figure 4.

Comparison of hospital stay

Hospital stay was analyzed in the 3 included articles (control: observation = 208:111). The heterogeneity was determined in hospital stay between groups ($I^2=77\%$), thus the random effects model was chosen. The findings revealed no significance in hospital stay between both groups (MD=-3.03, 95% CI: -6.85~0.79, $P=0.12$). These findings were presented in figure 5.

Comparison of recurrence

Recurrence was analyzed in the 3 included articles (control: observation = 208:111). The heterogeneity was determined in recurrence between

groups ($I^2=66\%$), thus the random effects model was chosen. The outcomes displayed relatively similar recurrence rate in the 2 groups, without differences (MD=0.83, 95% CI: 0.45~1.53, $P=0.12$). These outcomes were presented in figure 6.

Comparison of recurrence

Recurrence was analyzed in the 3 included articles (control: observation = 208:111). The heterogeneity was determined in recurrence between groups ($I^2=66\%$), thus the random effects model was chosen. The outcomes displayed relatively similar recurrence rate in the 2 groups, without differences (MD=0.83, 95% CI: 0.45~1.53, $P=0.12$). These outcomes were presented in figure 6.

Comparison of complications

Nerve injury was analyzed in 4 included articles (control: observation = 242:145). There was no heterogeneity detected in nerve injury between groups ($I^2=0\%$), thus the fixed effects model was chosen. The findings exhibited no significance in nerve injury between both groups (MD=0.63, 95% CI: 0.30~1.34, $P=0.23$). These findings were presented in figure 7A.

Urethral injury was analyzed in 4 included articles (control: observation = 242:145). There was no heterogeneity detected in urethral injury between groups ($I^2=0\%$), thus the fixed effects model was chosen. The findings exhibited no significance in urethral injury between both groups (MD=0.61, 95% CI: 0.19~1.97, $P=0.41$). These findings were presented in figure 7B.

Wound infection was analyzed in 4 included articles (control: observation = 242:145). There was no heterogeneity detected in wound infection between groups ($I^2=0\%$), thus the fixed effects model was chosen. The findings exhibited a significant decrease in wound infection in the observation group relative to the control (MD=0.42, 95% CI: 0.22~0.81, $P=0.010$). These findings were presented in figure 7C.

Table 1. Basic characteristics of the 6 included articles

Author	Year	N		Outcome measures	NOS score
		Observation	Control		
Zhang Y ⁽⁹⁾	2018	30	26	Intraoperative blood loss, intraoperative transfusion volume, surgery duration, incidence of complications	8
Ratto N ⁽¹⁰⁾	2020	15	11	Intraoperative blood loss, intraoperative transfusion volume, surgery duration, hospital stay, incidence of complications	8
Luo Y ⁽⁷⁾	2013	45	92	Intraoperative blood loss, intraoperative transfusion volume, surgery duration, hospital stay, recurrence, incidence of complications	9
Tang X ⁽¹¹⁾	2010	48	32	Intraoperative blood loss, surgery duration	7
Luo Y ⁽⁶⁾	2014	51	105	Intraoperative blood loss, intraoperative transfusion volume, surgery duration, hospital stay, incidence of complications	8
Wei L ⁽¹²⁾	2018	34	34	Intraoperative blood loss, surgery duration, recurrence, Complications	7

Note: N: Number. NOS: Newcastle-Ottawa Scale.

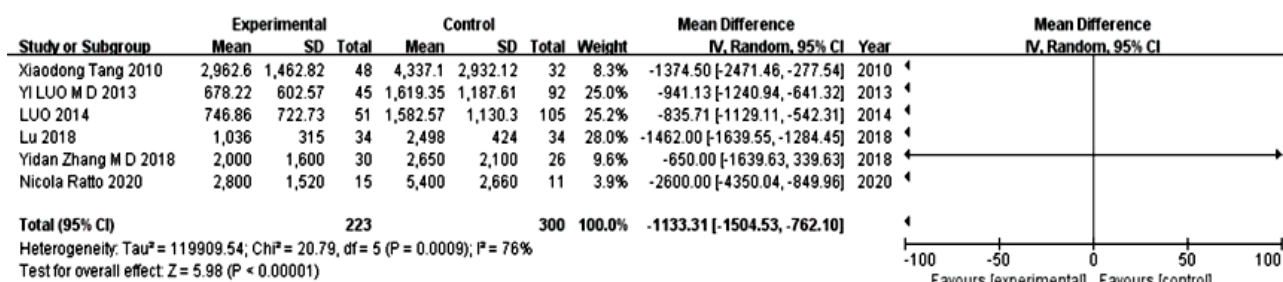


Figure 2. Forest plots for meta-analysis of intraoperative blood loss in the 2 groups. SD: standard deviation. CI: confidence interval. IV: inverse variance.

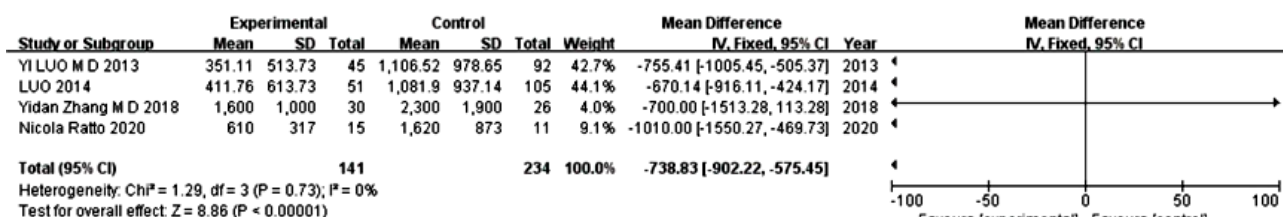


Figure 3. Forest plots for meta-analysis of intraoperative transfusion volume in the 2 groups. SD: standard deviation. CI: confidence interval. IV: inverse variance.

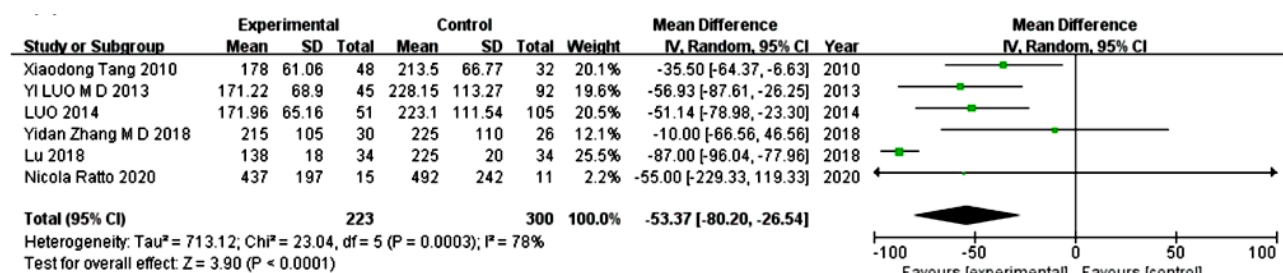


Figure 4. Forest plots for meta-analysis of surgery duration in the 2 groups. SD: standard deviation. CI: confidence interval. IV: inverse variance.

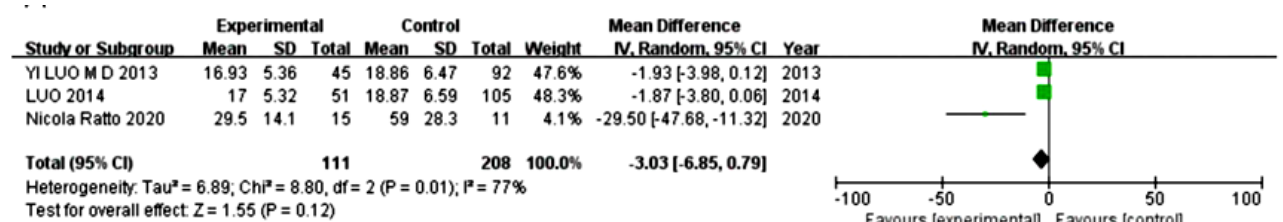


Figure 5. Forest plots for meta-analysis of hospital stay in the 2 groups. SD: standard deviation. CI: confidence interval. IV: inverse variance.

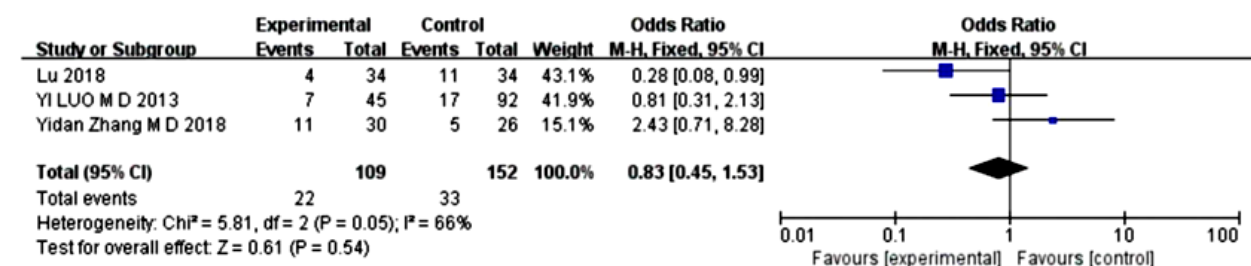
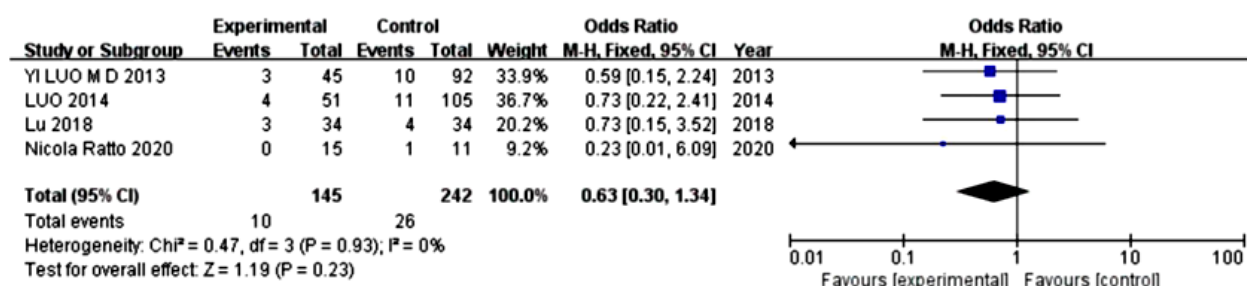
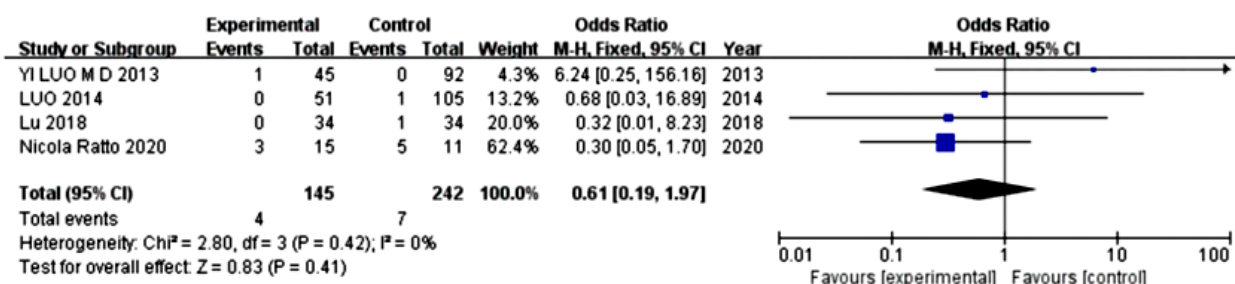


Figure 6. Forest plots for Meta-analysis of recurrence in the 2 groups. SD: standard deviation. CI: confidence interval. IV: inverse variance.

A



B



C

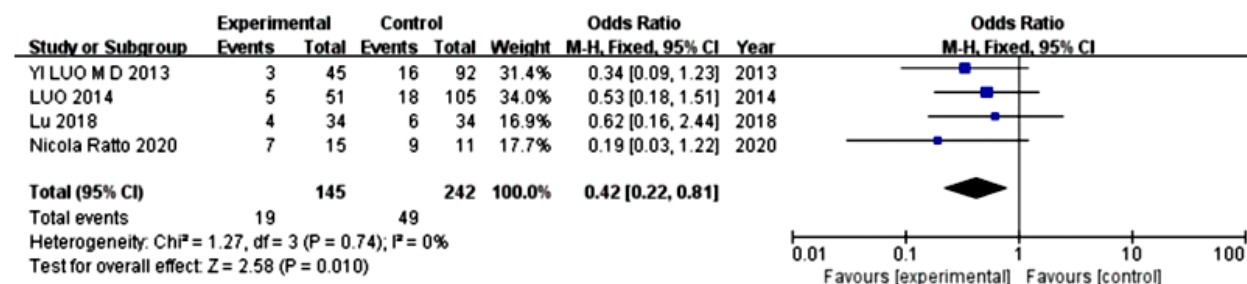


Figure 7. Forest plots for meta-analysis of nerve injury in the 2 groups (A). Forest plots for meta-analysis of urethral injury in the 2 groups (B). Forest plots for meta-analysis of wound infection in the 2 groups (C). SD: standard deviation. CI: confidence interval. IV: inverse variance.

Bias analysis

Funnel plot was used to analyze publication bias. As displayed in figure 8, the funnel plot showed a partial symmetric distribution, implying that there was significant publication bias in the included studies.

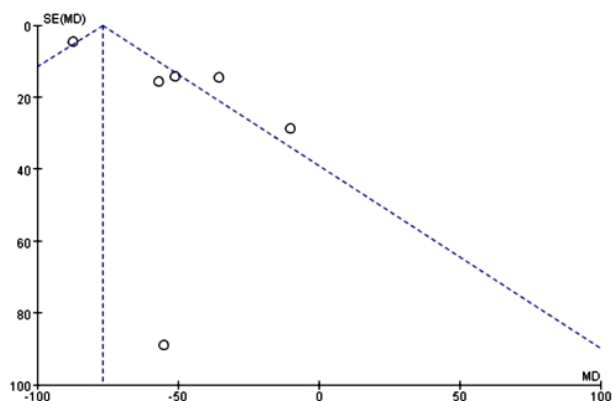


Figure 8. Funnel plot of publication bias. There was significant publication bias in the included studies. X axis: MD. Y axis: SE (MD). SE: standard error. MD: mean difference.

DISCUSSION

The occurrence of pelvic tumors is often accompanied by changes in the pelvic wall and blood vessels, which can easily cause adhesions of surrounding tissues and result in a large amount of bleeding and difficulty in hemostasis during surgery. Therefore, effective control of intraoperative bleeding is crucial for the success of the surgery and greatly affects the patient's prognosis. With the continuous development of medical technology, the use of AABO has been developed for pelvic tumor surgery. AABO can facilitate complete tumor resection, shorten surgery time and reduce intraoperative bleeding. Moreover, studies have shown that AABO guided by color Doppler ultrasound can significantly shorten the surgery duration, reduce vascular damage, avoid thromboembolism, provide direct observation of the surgical effect, and have a clear view of renal artery blood flow (13, 14).

In our study, we implemented a meta-analysis of 6 randomized controlled studies, with a total of 223

patients undergoing AABO, retrieved from domestic and foreign literature. Random effect model was implemented to conduct meta-analysis on the intraoperative blood loss of the 6 articles. Our results displayed that the intraoperative blood loss in the observation group was significantly reduced relative to that in the control group (MD=-1133.31, 95% CI: -1504.53~-762.10, $P<0.00001$). This indicated that AABO had a good hemostatic effect and could provide a clear surgical view to ensure the success of the surgery, which was in line with former literature⁽¹⁵⁾.

Most studies have shown that an increase in intraoperative blood transfusion can cause various complications, prolong hospitalization, increase the risk of infection, and cause thromboembolism⁽¹⁶⁻¹⁸⁾. In order to avoid excessive bleeding in patients during pelvic tumor resection surgery, blood transfusion is often performed during the surgery and its volume could affect the incidence of complications. In our study, the results displayed that the intraoperative blood transfusion volume was declined in the observation group, as relative to the control (MD=-738.83, 95% CI: -902.22~-575.45, $P<0.00001$), and the surgery duration in the observation group was significantly lessened relative to the control (MD=-53.37, 95% CI: -80.20~-26.54, $P<0.0001$). All these results suggested that AABO could reduce the volume of intraoperative blood transfusion and shorten surgery time, which was consistent with previous reports^(19,20).

Regarding postoperative complications, the results of our study also revealed lower incidence of wound infections in the observation group, as relative to the control (MD=0.42, 95% CI: 0.22~0.81, $P=0.010$). Similarly, in patients with placenta previa accrete, no serious balloon catheter-related complications occurred in the AABO group relative to the control group⁽²¹⁾. However, no difference was discovered in nerve damage (MD=0.63, 95% CI: 0.30~1.34, $P=0.23$) or urethral damage (MD=0.61, 95% CI: 0.19~1.97, $P=0.41$) between the two groups. Therefore, AABO is a safe and effective method for pelvic tumor resection surgery, with a reduced risk of postoperative complications.

Our research has some limitations. First, the sample size of the evaluated study is relatively small, and there is not enough information to evaluate the exactness of our study. In addition, most research started in a geographic area. Such location restrictions could severely influence the genuineness and plausibility of the results.

In conclusion, AABO under color Doppler ultrasound guidance can reduce intraoperative blood loss, transfusion volume, and operative time during pelvic tumor resection and can also reduce the incidence of some postoperative complications, which is worthy for promotion.

ACKNOWLEDGMENTS

None.

Funding: None.

Conflict of interest: All authors declare no conflicts of interest in this paper.

Ethical consideration: We will not obtain ethic documents because this study will be conducted based on the data of published literature.

Author Contributions: Z Z: Conceptualization, Methodology, Writing original draft. D W: Methodology, Investigation, Formal analysis, Validation. X Z: Investigation, Formal analysis, Data curation. J F: Methodology, Validation, Writing review & editing, Supervision. Q F: Writing review & editing, Supervision, Funding acquisition.

REFERENCES

- McMahon CJ, Rofsky NM, Pedrosa I (2010) Lymphatic metastases from pelvic tumors: anatomic classification, characterization, and staging. *Radiology*, **254**(1): 31-46.
- Wang KM, Rickards AJ, Bingham T, et al. (2022) Technical note: Evaluation of a silicone-based custom bolus for radiation therapy of a superficial pelvic tumor. *J Appl Clin Med Phys*, **23**(4): e13538.
- Ito Y, Nakayama H, Niitsu Y, et al. (2022) The first case of Veillonella atypica bacteremia in a patient with renal pelvic tumor. *Anaerobe*, **73**: 102491.
- Zoccali C, Baldi J, Attala D, et al. (2021) 3D-Printed Titanium Custom-Made Prostheses in Reconstruction after Pelvic Tumor Resection: Indications and results in a series of 14 patients at 42 months of average follow-up. *J Clin Med*, **10**(16).
- Stravitz RT, Ellerbe C, Durkalski V, et al. (2018) Bleeding complications in acute liver failure. *Hepatology*, **67**(5): 1931-42.
- Luo Y, Duan H, Min L, et al. (2014) Clinical evaluation of lower abdominal aorta balloon occlusion in pelvic or sacral tumor resection. *West China Medical Journal*.
- Luo Y, Duan H, Liu W, et al. (2013) Clinical evaluation for lower abdominal aorta balloon occluding in the pelvic and sacral tumor resection. *J Surg Oncol*, **108**(3): 148-51.
- Xiong YQ, Song HB, Tu CQ, et al. (2012) Applying the color doppler in abdominal aortic balloon occlusion for pelvic and sacral surgery. *Sichuan Da Xue Xue Bao Yi Xue Ban*, **43**(5): 715-9.
- Zhang Y, Guo W, Tang X, et al. (2018) Can aortic balloon occlusion reduce blood loss during resection of sacral tumors that extend into the lower lumbar spine? *Clin Orthop Relat Res*, **476**(3): 490-8.
- Ratto N, Boffano M, Pellegrino P, et al. (2020) The intraoperative use of aortic balloon occlusion technique for sacral and pelvic tumor resections: A case-control study. *Surg Oncol*, **32**: 69-74.
- Tang X, Guo W, Yang R, et al. (2010) Use of aortic balloon occlusion to decrease blood loss during sacral tumor resection. *J Bone Joint Surg Am*, **92**(8): 1747-53.
- Wei L, Xiang Y, Zhuang J, et al. (2018) Application of abdominal aorta blockade in pelvic sacral tumor resection and reconstruction. *Chinese Journal of Bone and Joint Surgery*.
- Iskan HZ, Unal EU, Akkaya B, et al. (2021) Color doppler ultrasound for surveillance following EVAR as the primary tool. *J Card Surg*, **36**(1): 111-7.
- Wang Y, Huang G, Jiang T, et al. (2019) Application of abdominal aortic balloon occlusion followed by uterine artery embolization for the treatment of pernicious placenta previa complicated with placenta accreta during cesarean section. *J Interv Med*, **2**(3): 113-7.
- Kong L, Yu Y, Li F, et al. (2020) Intra-aortic balloon occlusion decreases blood loss during open reduction and internal fixation for delayed acetabular fractures: A retrospective study of 43 patients. *J Invest Surg*, **33**(5): 468-73.
- Saraçoğlu A, Ezelsoy M, Saraçoğlu KT (2019) Does Transfusion of Blood and Blood Products Increase the Length of Stay in Hospital? *Indian J Hematol Blood Transfus*, **35**(2): 313-20.

17. Morrissey PE, Gordon F, Shaffer D, et al. (1998) Combined liver-kidney transplantation in patients with cirrhosis and renal failure: effect of a positive cross-match and benefits of combined transplantation. *Liver Transpl Surg*, **4**(5): 363-9.
18. Xing X, Zhong G, Xiang-Yang B, et al. (2013) Liver resection for the treatment of the patients with giant hepatic tumor without intraoperative blood transfusion. *Journal of General Surgery for Clinicians(Electronic Version)*.
19. Liu Y, Shan N, Yuan Y, et al. (2022) The clinical evaluation of pre-operative abdominal aortic balloon occlusion for patients with placenta increta or percreta. *J Matern Fetal Neonatal Med*, **35**(25): 6084-9.
20. Wang YL, Su FM, Zhang HY, et al. (2017) Aortic balloon occlusion for controlling intraoperative hemorrhage in patients with placenta previa increta/percreta. *J Matern Fetal Neonatal Med*, **30**(21): 2564-8.
21. Yin H and Hu R (2022) Outcomes of prophylactic abdominal aortic balloon occlusion in patients with placenta previa accreta: a propensity score matching analysis. *BMC Pregnancy Childbirth*, **22**(1): 502.

