

Isolated scapular metastasis from breast carcinoma

H. Baysal^{1*}, B. Baysal², M. Tarik Tatoglu³, O. Alimoglu⁴

¹Istanbul Medeniyet University Goztepe Prof. Dr. Suleyman Yalcin City Hospital, General Surgery, Istanbul, Turkey

²Istanbul Medeniyet University Faculty of Medicine, Radiology, Istanbul, Turkey

³Istanbul Medeniyet University Goztepe Prof. Dr. Suleyman Yalcin City Hospital Nuclear Medicine, Istanbul, Turkey

⁴Istanbul Medeniyet University Faculty of Medicine General Surgery, Istanbul, Turkey

► Case report

*Corresponding author:

Hakan Baysal, M.D.

E-mail:

hakanbaysal_tr@yahoo.com

Received: October 2022

Final revised: January 2023

Accepted: February 2023

Int. J. Radiat. Res., July 2023;
21(3): 605-608

DOI: 10.52547/ijrr.21.3.35

ABSTRACT

Breast cancer is the most common cancer in women and the most common cause of cancer-related death in women worldwide. Distant metastases in breast cancer occur in the bones, lungs, liver, and brain. Surgical treatment is recommended because the resection of primary tumor in breast cancer has a positive effect on prognosis and survival. The importance of ablative therapy has increased with the development of systemic treatments for a small number of organ metastases, which are referred to as oligometastases. Patients with isolated bone metastases have better prognosis than those with other visceral metastases. In single bone metastases, systemic and local treatments are preferred using a multidisciplinary approach. This case report presents a breast cancer patient with contralateral isolated scapula glenoid metastases, which have not been reported in the literature.

Keywords: Breast cancer, metastases, scapula.

INTRODUCTION

Breast cancer is the most common cancer in women. Distant metastases in breast cancer are most common in the bones, lungs, liver, and brain. Bone metastases are frequently observed in the pelvis, ribs, thoracic and cervical vertebrae, skull, and long bones, which are rich in bone marrow ⁽¹⁾. Herein, we represent the current advances in the diagnosis and treatment of isolated scapula glenoid metastases caused by breast cancer, which, to our knowledge, have not been reported yet.

CASE REPORT

A 56-year-old woman was admitted to the Orthopedic Department with left shoulder pain that had been ongoing for 2 months. On physical examination, the patient's left shoulder movement was painful; limited joint movement was detected. Magnetic resonance imaging (MRI) (1.5 Tesla General Electric, MR450w, Chicago, Illinois, USA) of the left shoulder showed an expansile and destructive mass lesion in the left scapular glenoid, covering the glenohumeral articular surface; joint extension was not detected (figure 1a-d). Positron emission tomography/ computed tomography (PET/CT) (Philips Gemini TF 64, Philips Medical Systems, Best, The Netherlands) fusion images (figure 2a,d) at the time of diagnosis revealed metastatic lytic-sclerotic

bone lesions with intensely increased 18F-Fluorodeoxyglucose (FDG) uptake at the glenoid level of the left scapula (SUDmax:7.2). Concurrently, a primary lesion in the right breast and axillary metastases were observed. Treatment response was evaluated at 6 months using PET/CT fusion (figure 2b,e). PET/CT images showed a nearly complete metabolic response and significant sclerosis development at the left scapula glenoid level (SUDmax:2.1). Sclerosis was observed more prominently and minimal FDG uptake was noted; these may be secondary response to radiotherapy (RT) (figure 2c,f). Core-needle biopsy was performed on the scapula; US-guided tru-cut and fine-needle aspiration biopsies were obtained from the right breast and axilla. The results of pathological analysis showed that Luminal A breast invasive ductal carcinoma was compatible with breast carcinoma metastases of the axilla and scapula. Laboratory results of a patient who had undergone thyroidectomy with benign pathology 25 years ago and bilateral mastopexy surgery 15 years ago showed only mild Ca 15-3 elevation of 32.3 U/ml (0-26). The patient was diagnosed with breast cancer and isolated contralateral scapula metastasis; local palliative RT (Varian, DMX model, Linear Accelerator, Palo Alto, California, USA) (3-Gy 10 fractions daily) hormone therapy (Ribociclib, Letrozole), and Denosumab treatment regimen were administered to

the scapula. PET/CT maximum intensity projection (MIP) imaging was performed to evaluate the response to the 6-month treatment; the results showed increased FDG uptake in the right breast outer quadrant, right axillary fossa, and left scapula level regression (figure 3). The patient underwent a right modified radical mastectomy. Tumor response to neoadjuvant chemotherapy (NAC) in the breast

was T-D/A-D (no response) invasive NOS-Luminal A; response to NAC in the axilla was N-C/A-D (therapeutic effect was noted, but metastasis remained) 7/6+. The patient, whose pathological stage was accepted as ypT1cN2aM1LOV0R0 (AJCC 2018), had been receiving active treatment for 24 months with clinical complete response.

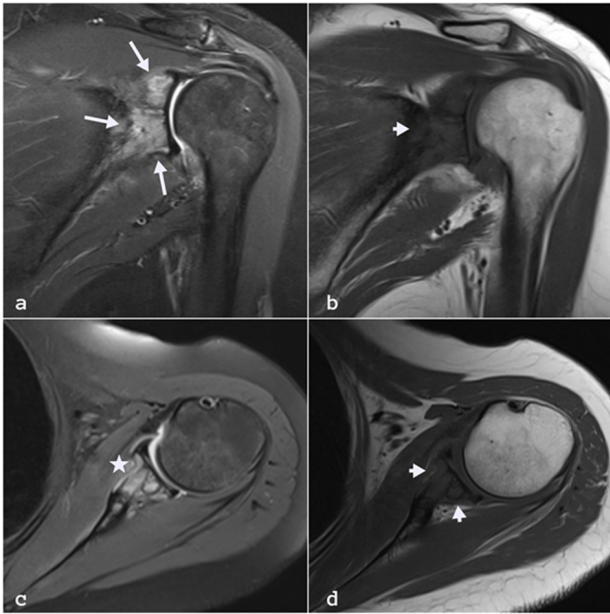


Figure 1. The left shoulder joint MRI examination; An expansile mass lesion is observed in the left scapula glenoid, covering the glenohumeral articular surface, heterogeneously hyperintense on coronal fat-suppressed PD-weighted sequence (a) and hypointense on coronal T1-weighted sequence (b). Fat-suppressed PD (c) and axial T1-weighted sequences (d) taken in the axial plane showed expansion in the anterior and posterior bone contour and destruction in the cortex, and joint extension was not detected.

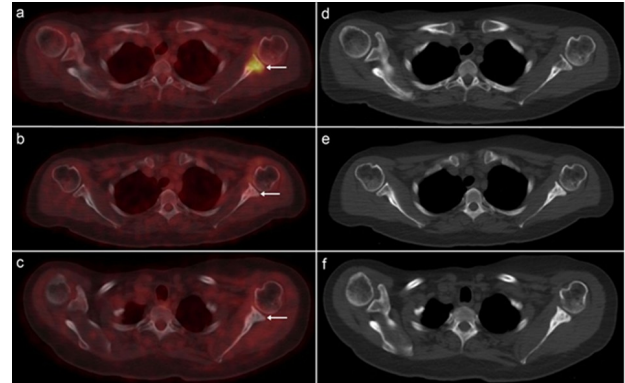
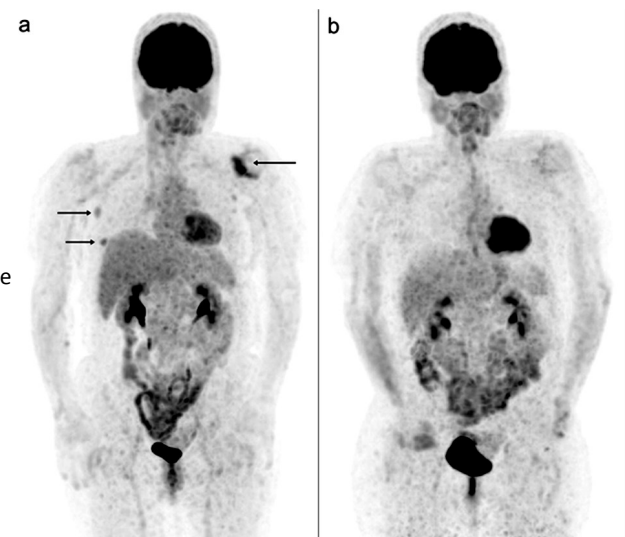


Figure 2. PET/CT fusion (a) CT (d) images at the time of diagnosis; metastatic lytic sclerotic bone lesion showing intensely increased FDG uptake at the glenoid level of the left scapula (SUDmax:7.2). Evaluation of response to treatment at 6 months PET/CT fusion (b) CT (e) images; In the left scapula glenoid level, in the lytic-sclerotic-looking lesion with intensely increased FDG uptake observed in the previous study, a nearly complete metabolic response and significant sclerosis development, which is interpreted in favor of a sclerotic response to treatment, is observed (SUDmax: 2.1). In the current PET/CT fusion (c) CT (f) images; While it was observed that sclerosis became more prominent at the sclerotic lesion level with minimal FDG uptake observed in the previous study at the left scapula glenoid level, it is interpreted that minimal FDG uptake, similar to the previous study, may be compatible with changes secondary to RT.

Figure 3. Appearances of metastatic lesions with increased FDG uptake observed in the right breast outer quadrant, right axillary fossa, and left scapula level, marked with an arrow in the PET/CT MIP image performed for primary focus search at the time of diagnosis (a). In the PET/CT MIP image (b) performed to evaluate the response to the 6-month treatment, it is seen that the increased FDG uptake was observed in the previous study in the right breast outer quadrant, right axillary fossa, and left scapula level is regressed.



DISCUSSION

Treatments developed based on the signaling pathways involved in breast cancer with isolated bone metastases are constantly developing, and multidisciplinary approaches are preferred. Metastasis may develop in 20–30% of early stage breast cancers despite improvements in treatment (2). Bone metastases are observed in approximately 70% patients with metastatic breast cancer; although its biological behavior is better than that of other organ cancers, the 5-year survival rate may fall below 30% in distant metastasis cases (3). With advances in systemic treatments, ablative therapy's importance for patients with few organ metastases, called oligometastases, has increased. Bone metastasis has a better prognosis than do other visceral metastases (4). The mean survival time of patients with bone metastases is 24–65 months (4). The self-seeding theory in metastatic breast cancer supports surgical intervention for primary tumors. Herein, surgery was performed on the primary tumor because the patient was oligometastatic. In retrospective studies, oligometastatic disease, operable local visceral organ metastasis, and bone metastasis positively affected survival (5). Clinically, bone metastasis may present with severe pain, hypercalcemia, bone marrow failure, pathological fracture, spinal cord compression or it may sometimes occur asymptotically and only be discoverable on scans (6). Restricted range of motion accompanying severe arm and shoulder pain was present here; the possibility of these complaints being cancer warning signs should be considered. Metastases, often the sclerotic type, can be seen in the lytic-sclerotic type in patients with prolonged survival. Herein, the lesion was osteolytic. Although breast cancer bone metastases are mostly seen as osteolytic, 15–20% of the cases are in osteoblastic form (7). In treatment of patients with breast cancer metastatic to the bone, the clinical scenario and tumor-specific biology should be considered (8). Seven metastatic pathways are identified: the TGF- β signaling pathway, OPG/RANK/RANKL signaling pathway, PI3K-AKT-mTOR signaling pathway, IGF system, Wnt signaling pathway, and Hippo signaling pathway (6). The receptor activator of the nuclear factor- κ B ligand (RANKL)/RANK inhibitors and bisphosphonates are currently the most widely used agents (9). Next-generation nitrogen-containing bisphosphonates (e.g., risedronate, pamidronate, ibandronate, zoledronic acid, and alendronate) inhibit farnesyl pyrophosphate synthase (FPPS) and are regarded as more effective osteoclast inhibitors (10). Our patient was treated with an aromatase inhibitor (Letrozole), RANKL inhibitor (Denosumab), CDK 4/6 inhibitor (Ribosiklib), and palliative RT (3 Gy 10 fractions daily) for 6 months; complete response was achieved.

Conventional RT provides clinically significant pain relief with an 18–21 month-median response period in 80% patients with uncomplicated oligometastatic bone metastasis (11). The most common RT techniques used are stereotactic body radiation therapy (SBRT), stereotactic ablative radiation therapy, and hypofractionated image-guided radiation therapy (12). A randomized study review demonstrated equivalent results for pain control and toxicity in breast cancer patients with uncomplicated bone metastasis treated with fractionated and single fraction exposure with an 8-Gy dose (13). Recent studies reported that SBRT presents improved pain response, compared with that by conventional RT (14). However, randomized trials comparing conventional RT with SBRT reported contradictory results. In one study, no significant difference was observed between RT and SBRT (15). Future studies should focus on determining patient subgroups with high probability of benefiting from SBRT treatment. In addition to RT, orthopedic surgical interventions are performed according to the location and condition of the affected bone. Surgical treatment for bone lesion was not considered for the patient because the lesion site carries a risk for impaired movement of the arms and shoulders postoperatively.

CONCLUSION

Patients with isolated bone metastases have better prognosis than do those with other visceral metastases. This is the first report of isolated breast cancer metastasis in the glenoid of the scapula. More signaling pathways, besides seed and soil hypothesis and their potential relations, should be explored. Breast cancer bone metastases is preventable; future therapeutic strategies that will prolong patient survival can be established on solid bases. Isolated bone metastases from metastatic breast cancer should be evaluated by using a multidisciplinary approach and treated with systemic and local treatment methods.

ACKNOWLEDGMENT

None

Disclosure: The authors report no proprietary or commercial interest in any product mentioned or concept discussed in this article.

Ethical Consideration: This study was conducted under the standards of the ethics committee of Istanbul Medeniyet University Goztepe Research and Training Hospital. The approval number is 2022/0152. Written informed consent was obtained from the patient.

Funding: This research did not receive any specific grant from funding agencies in the public, commercial, or not-for-profit sectors.

Author Contributions: Conceptualization: HB, BB, MTT, OA; study design: HB, BB, MTT,OA; defining the study: HB, BB; extensive literature search: HB, BB; data acquisition: HB, BB, MTT,OA; data analysis: HB, BB, MTT,OA; manuscript writing: HB, BB, MTT. All authors have read and approved the final version of the manuscript.

REFERENCES

- Riggio AI, Varley KE, Welm AL (2021) The lingering mysteries of metastatic recurrence in breast cancer. *British Journal of Cancer*, **124(1)**: 13–26.
- Wang R, Zhu Y, Liu X, Liao X, He J, Niu L (2019) The Clinicopathological features and survival outcomes of patients with different metastatic sites in stage IV breast cancer. *BMC Cancer*, **19(1)**: 1091.
- Noone AM, Howlander N, Krapcho M, Miller D, Brest A, Yu M, et al. SEER Cancer Statistics Review, 1975-2015, National Cancer Institute. Bethesda, MD, https://seer.cancer.gov/csr/1975_2015/, based on November 2017 SEER data submission, posted to the SEER website, April 2018.
- Pulido C, Vendrell I, Ferreira AR, Casimiro S, Mansinho A, Alho I, et al. (2017) Bone metastasis risk factors in breast cancer. *Ecancermedicalscience*, **11**: 715.
- Harris E, Barry M, Kell MR (2013) Meta-analysis to determine if surgical resection of the primary tumour in the setting of stage IV breast cancer impacts on survival. *Annals of surgical oncology*, **20(9)**: 2828–2834.
- Song X, Wei C, Li X (2022) The Signaling Pathways Associated With Breast Cancer Bone Metastasis. *Front Oncol*, **12**: 855609.
- Wu X, Li F, Dang L, Liang C, Lu A, Zhang G (2020) RANKL/RANK System-Based Mechanism for Breast Cancer Bone Metastasis and Related Therapeutic Strategies. *Frontiers in Cell and Developmental Biology*, **8**: 76.
- Marazzi F, Orlandi A, Manfrida S, Masiello V, Di Leone A, Massaccesi M, et al. (2020) Diagnosis and Treatment of Bone Metastases in Breast Cancer: Radiotherapy, Local Approach and Systemic Therapy in a Guide for Clinicians. *Cancers*, **12(9)**: 2390.
- Clézardin P, Coleman R, Puppo M, Ottewill P, Bonnelye E, Paycha F, et al. (2021) Bone metastasis: mechanisms, therapies, and biomarkers. *Physiol Rev*. **101(3)**: 797-855.
- Wang L, Fang D, Xu J, Luo R (2020) Various pathways of zoledronic acid against osteoclasts and bone cancer metastasis: a brief review. *BMC Cancer*, **20(1)**: 1059.
- van der Velden J, Willmann J, Spátek M, Oldenburger E, Brown S, Kazmierska J, et al. (2022) ESTRO ACROP guidelines for external beam radiotherapy of patients with uncomplicated bone metastases. *Radiother Oncol*. **173**: 197-206.
- Kraus KM, Winter J, Zhang Y, Ahmed M, Combs SE, Wilkens JJ, et al. (2022) Treatment Planning Study for Microbeam Radiotherapy Using Clinical Patient Data. *Cancers*, **14(3)**: 685.
- Rich SE, Chow R, Raman S, Liang Zeng K, Lutz S, Lam H, et al. (2018) Update of the systematic review of palliative radiation therapy fractionation for bone metastases. *Radiother Oncol*. **126(3)**: 547-557. Erratum in: *Radiother Oncol*. 2019 Jun; 135:201.
- Sit D, Zhao B, Chen KT, Lohrisch C, Olson R, Nichol A, et al. (2022) The Effect of Breast Cancer Subtype on Symptom Improvement Following Palliative Radiotherapy for Bone Metastases. *Clinical Oncology (Royal College of Radiologists (Great Britain))*, **34(4)**: 267-273.
- Pielkenrood BJ, van der Velden JM, van der Linden YM, Bartels MMT, Kasperts N, Verhoeff JJC, et al. (2021) Pain Response After Stereotactic Body Radiation Therapy Versus Conventional Radiation Therapy in Patients With Bone Metastases-A Phase 2 Randomized Controlled Trial Within a Prospective Cohort. *Int J Radiat Oncol Biol Phys*. **110(2)**: 358-367.