

Observation on the therapeutic effect of chemotherapy combined with Banxia Xiexin decoction on duodenal cancer under CT enhanced scanning

Y. Gou and H. Zhou*

Department of General Surgery, The People's Hospital of Changshou Chongqing, Chongqing, 401220, China (mainland)

ABSTRACT

► Original article

***Corresponding author:**

Hongze Zhou

E-mail: dufu2614@gmail.com

Received: February 2023

Final revised: May 2023

Accepted: June 2023

Int. J. Radiat. Res., October 2023;
21(4): 633-637

DOI: 10.52547/ijrr.21.4.5

Keywords: Chinese herbal medicine, Banxia Xiexin Decoction, chemotherapy, CT.

Background: Banxia Xiexin Decoction (BXD) is reported to be effective in the treatment of gastrointestinal diseases. In this work, we evaluated the effects of chemotherapy combined with Banxia Xiexin Decoction on duodenal cancer using Computed tomography (CT) enhanced scanning. **Materials and Methods:** Totally 80 cases diagnosed with duodenal cancer were selected, and the data of patients were retrospectively analyzed. They were randomly allocated into the treatment and control groups with 40 patients in each group. Participants in the treatment group received serotonin blocker (granisetron) combined with chemotherapy drugs, and oral administration of Banxia Xiexin Decoction to prevent nausea, vomiting and other gastrointestinal reactions. Those in the control group received chemotherapy drugs, combined with serotonin blocker (granisetron). CT enhanced scan, magnetic resonance imaging (MRI) and pathological examination were performed, and pathological diagnosis was used as the gold standard for treatment effect evaluation. **Results:** For patients in the treatment group, 13 were analyzed, 15 were clear, 9 had no effect, and 3 were negative, with a total effect of 93.50%; For patients in the control group, there are 6 patients with control, 16 patients with obvious results, 12 patients with benefits, and 6 with no benefits, with a total results of 87.00%. All the results were significantly different between the two groups ($P < 0.05$). **Conclusion:** Banxia Xiexin decoction has the advantages of low cost, obvious benefits, and few side effects in the treatment of nausea and vomiting of duodenal cancer patients, which is suitable for medical treatment.

INTRODUCTION

The incidence of duodenal adenocarcinoma is below 0.5/100,000, accounting for 0.3% to 1.0% of gastrointestinal tumors and 25% to 35% in small intestinal malignant tumors^(1, 2). Primary duodenal carcinoma (PDC) specifically refers to malignant tumors originating in each segment of the duodenum. The clinical manifestations of patients lack specificity, and the means of examination is limited, which often lead to ignorance and misdiagnosis⁽³⁾. The delayed diagnosis may result in local invasion or distant metastasis of the tumor, thus missing the opportunity for radical cure⁽⁴⁾. With the continuous development of detection technologies such as endoscopic ultrasonography, endoscopic retrograde cholangiopancreatography (ERCP) and the deepening understanding of the disease, many PDCs are correctly diagnosed at an early stage. Treatment options such as surgery, chemotherapy are mainly recommended for patients with duodenal adenocarcinoma. Surgical treatment is the first choice, which varies according to the differentiation, location, and degree of accumulation of the tumors⁽⁵⁾.

However, the prognosis remains poor in these patients and the 5-year survival of around 50% can be achieved after surgery and other anti-cancer therapy^(6, 7).

Accumulating evidence has revealed that herbal traditional Chinese medicine (TCM) provides an effective approach in the management of gastrointestinal disorders^(8, 9). Banxia Xiexin Decoction (BXD) is a classic TCM prescription recorded in *Treatise on Febrile Diseases and Synopsis of Prescriptions of the Golden Chamber*. It contains 7 types of Chinese herbal medicine including Banxia (washed) half a liter, Scutellaria baicalensis, dried ginger, ginseng, licorice (burned) each three or two, Coptis chinensis (one or two), and jujube (brown) twelve, and is mainly used to treat digestive system diseases, and studies also reveal the anti-tumor property of this prescription^(10, 11). For example, this formula is reported to inhibit the proliferation and alleviate the drug sensitivity of drug-resistant gastric cancer cells via the IL6/JAK/STAT3 signaling⁽¹¹⁾. A case report has shown that BXD combined with afatinib is effective to treat advanced gallbladder cancer, and the symptoms such as diarrhea disappear

and the tumor was controlled ⁽¹²⁾. Lu *et al.* have indicate that BXD could block irinotecan-induced diarrhea in the treatment of small cell lung cancer.

In this study, we aimed to observe and evaluate the therapeutic effect of Banxia Xiexin Decoction on duodenal cancer using CT enhanced scanning technology, which may provide novel therapeutic options for duodenal adenocarcinoma patients.

MATERIALS AND METHODS

General information

In this retrospective study, a total of 80 outpatients and inpatients in our hospital from January 2004 to December 2015 were included. Based on the principle of random drawing, patients were randomized into the control or treatment groups in a 1:1 ratio. The general information of patients was shown in table 1. Inclusion criteria: Primary duodenal cancer confirmed by pathological examination, endoscopy, surgery, gastrointestinal angiography, computed tomography (CT) and magnetic resonance imaging (MRI). Exclusion criteria: Pancreas, bile duct and other periampullary carcinomas; Carcinoid, neuroendocrine carcinoma, lymphoma and sarcoma. Totally 80 primary duodenal carcinoma (PDC) patients were included in this study. The information of basic clinical characteristics and tumor characteristics of patients was collected. PDC stages were defined based on the American Joint Committee on Cancer (AJCC) staging criteria, the 7th edition in 2010, and the degree of histological differentiation was differentiated according to the World Health Organization (WHO) classification criteria; the tumor grade was defined as well, moderate, poor and undifferentiated according to the WHO standard grading system.

Table 1. Clinical features of patients.

Variable	Control group (n=40)	Treatment group (n=40)	P
Sex			
Male/female	17/23	18/22	0.822
Age (years)	64.2±2.3	63.8±1.9	0.399
Tumor size (cm)			0.633
≤4	28	26	
>4	12	14	
AJCC stage			0.873
I	6	4	
II	10	12	
III	18	19	
IV	6	5	
Tumor grade			0.828
well	11	12	
moderate	17	19	
poor	8	7	
undifferentiated	4	2	

AJCC, American Joint Committee on Cancer

Inspection method

Patients with suspected primary duodenal

adenocarcinoma underwent enhanced CT scan, MRI and pathological examination, and pathological diagnosis was the gold standard. The day before the examination, the patient was informed with general instructions, and fast for 3 hours before the examination. For CT enhanced scan examination, a 16-slice spiral CT scanner (GE Healthcare, USA, model: GE16 row) was used. Patients were instructed to take a supine position, with the head first, and raise the arms to the top of the head. The electrodes were then placed, and the skin of patients was kept dry. Then patients were instructed to relax the abdomen, hold the breath for 5~6sec and start scanning. The parameters were set as follows: Voltage 120kV, current 240mA, scanning layer thickness 3mm, and matrix 512×512. Then all patients were scanned from the top of the diaphragm to the iliac crest, and enhanced scanning was performed after the plain scan according to the specific situation of the patient. Patients were injected with 100 mL Meglumine Meglumine Injection (A Bleike Xinyi Pharmaceutical Co., Ltd., Shanghai, China; Chinese medicine approved word H31023021, specification: 50mL: 30g) via cubital vein using high-pressure syringes (Toshiba, Japan), according to the patient's body weight of 1.2 mL/kg, the rate of 3.0 mL/sec. Then, 50 mL of normal saline was injected at the same speed to rinse. Eighty seconds after injection, scanning was started, and the scanning was delayed for 25 sec in the arterial phase, 60 sec in the portal venous phase, and 120 sec in the equilibrium phase.

After scanning, image reconstruction is performed on the original data. For MRI examination, a magnetic resonance scanner (Siemens, Germany, model: SiemensSkyra1.5) was used. Patient were maintained at supine position, with the arms raised to the top of the head, and the body phased array coil. During the scan, patients were asked to hold the breath, and then scanned from the top of the diaphragm to the iliac crest. The sequence included coronal, sagittal, and axial. The scan sequence was set up under slice thickness of 4.0 mm, field of view at 40cm×30cm, T1-weighted imaging (T1WI) (TR420ms, TE42ms), T2-weighted imaging (T2WI) (TR3000ms, TE110ms).

After the plain scan, enhanced scan was performed, and 100 mL of Meglumine Meglumine Injection was injected into the peripheral cubital vein of patients at the speed of 3.0 mL/sec. The delayed scan was 25 sec in the arterial phase, 60 sec in the portal venous phase, and 120 sec in the equilibrium phase. The above examinations were conducted by 2 or more experienced physicians to observe and analyze the imaging situation of patients in the two groups, followed by the final diagnosis.

Observation indicators

The detection results of enhanced CT scan and MRI were compared in patients with suspected primary duodenal adenocarcinoma ⁽¹³⁾.

CT enhanced scan and MRI were compared in patients with primary duodenal adenocarcinoma lesions capsule enhancement performance, including no obvious enhancement, incomplete annular enhancement, complete annular enhancement (14).

The diagnosis of CT-enhanced scanning and MRI were compared in the diagnosis of liver cancer, including specificity, sensitivity, accuracy, positive value and poor prognosis (15). Specificity = number of true negatives / (false + false positives) number of patients \times 100%, sensitivity = number of true positives / (true positives + untrue) number \times 100%, precision = (true + false positive) number / all events \times 100%, positive betting rate = true positive / (true positive + negative) \times 100%, negative prediction rate = negative / (true negative + false negative) \times 100%.

The imaging pictures of typical cases of primary duodenal adenocarcinoma diagnosed by CT enhanced scan and MRI examination were analyzed (figure 1).

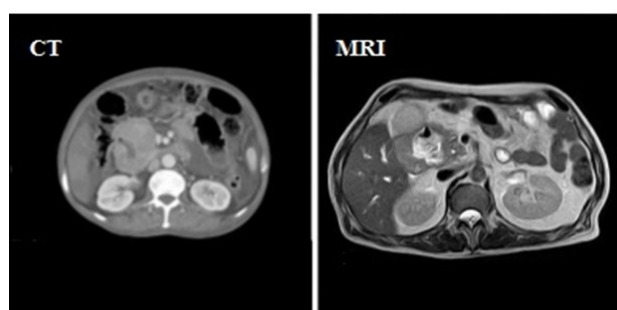


Figure 1. CT enhanced scan and MRI examination showing typical cases of primary duodenal adenocarcinoma.

Treatment methods

Patients in the treatment group received serotonin blocker (granisetron, Fu'an Pharmaceutical Group Ningbo Tianheng Pharmaceutical Co. Ltd.) combined with chemotherapeutic drugs, and orally administrated with Banxia Xiexin decoction (150 ml at a time, twice a day) provided by our hospital to prevent nausea, vomiting and other gastrointestinal tract reaction. Patients in the control group received chemotherapy drugs, and serotonin blockers (granisetron) was used to prevent gastrointestinal reactions such as nausea and vomiting.

Statistical methods

Statistical analysis was conducted with Statistical analysis software (SAS, SAS Institute Inc., USA). The enumeration data were expressed as rate (%), and comparison between groups was subject to the X^2 test. The difference was statistically significant when $P < 0.05$.

RESULTS

Patient characteristics

As shown in table 1, data of totally 80 PDC patients were retrospectively analyzed. Patients in

the control group consisted of 17 males and 23 females, with an average age of 64.2 ± 2.3 years old; the treatment group contained 18 males and 22 females, and the average age was 63.8 ± 1.9 years old. No significant difference was found between the baseline characteristics of two groups of patients ($P > 0.05$).

Comprehensive treatment efficacy analysis

The control rate was 33.00% and the total efficiency was 93.50% for patients in the treatment group and 14.00% and 87.00% for the treatment group, respectively. The overall performance of the two groups was significantly different ($P < 0.05$), indicating that the treatment group was more effective in the therapy of PDC patients than the control group (table 2).

Table 2. Comprehensive efficacy analysis.

Group	n	clinical control	effective	efficient	invalid	total efficiency
Treatment group	40	13 (33.00%)	15 (37.00%)	9 (22.00%)	3 (7.00%)	93.50%
Control group	40	5 (14.00%)	16 (40.00%)	12 (30.00%)	6 (15.00%)	87.00%

Analysis of the treatment efficacy to prevent nausea and vomiting in the two groups

The symptoms were significantly alleviated in patients treated with BXD combined with chemotherapy drugs relative to the control group ($P = 0.004$), which suggested that the combined treatment with Banxia Xiexin decoction showed better performance to prevent nausea and vomiting in chemotherapy patients (table 3).

Table 3. Analysis of main symptoms and curative effect.

Symptom	Group	After treatment				Between groups	
		-	+	++	+++	X^2	P
Nausea	Treatment group	21	5	3	2	8.105	0.004
Vomit	Control group	14	6	4	6		

As shown in table 4, the changes in symptoms and signs in the two groups were subject to Ridit analysis, and we found significant differences in the changes of symptoms such as poor appetite and abnormal stool between the two different interventions ($P < 0.05$).

Table 4. Analysis of curative effect of various symptoms.

Symptom	Group	After treatment				Between groups	
		-	+	++	+++	X^2	P
Poor appetite	Treatment group	15	18	4	3	4.371	0.037
	Control group	10	12	13	5		<0.05
Abnormal stool	Treatment group	21	11	5	2	4.465	0.035
	Control group	14	10	11	5		<0.05
Bloating after eating	Treatment group	23	10	5	2	2.967	0.085
	Control group	18	6	10	6		>0.05
Tiredness	Treatment group	18	11	7	4	3.481	0.062
	Control group	11	10	13	6		>0.05
Pale complexion	Treatment group	22	10	5	3	1.60	0.206
	Control group	18	8	12	8		>0.05

As shown in table 5, the data were statistically processed by the X^2 test in the RxC Table. There is no difference in the tongue quality within the treatment or control group before and after the treatment ($p>0.05$). In addition, the tongue quality of patients between groups also exhibited no statistical difference ($p>0.05$).

Table 5. Analysis of tongue quality.

Group	n	Before and after treatment	light	dim	other	within the group		Between groups after treatment	
						χ^2	P	χ^2	P
Treatment group	40	before therapy	21	15	4	0.277	0.871	2.809	0.245
		After treatment	22	13	5				
Control group	40	before therapy	23	13	4	3.28	0.194		
		After treatment	15	20	5				

As shown in table 6, data were analyzed by the X^2 test of the RxC Table, and we found that the tongue coating was not significantly improved after the treatment within the treatment or control groups ($p>0.05$). Moreover, we found that there was no significant difference in efficacy between the two groups.

Table 6. Comparison of tongue coating between the two groups before and after treatment.

Group	n	Before and after treatment	thin white	white and greasy tongue coating	other	within the group		Between groups	
						χ^2	P	χ^2	P
Treatment group	40	Before therapy	13	23	4	0.234	0.890	0.958	0.611
		After treatment	15	21	4				
Control group	40	Before therapy	14	21	5	0.395	0.821		
		After treatment	13	20	7				

As shown in table 7, the data of the two groups were analyzed by X^2 analysis of the R x C table, and there was no significant improvement in the pulse condition before and after the treatment in the treatment or control groups ($p>0.05$). We also found that there was no statistical difference between the treatment group and the control group in the pulse condition of patients ($P>0.05$).

Table 7. Comparison of pulse condition in the two groups before and after treatment.

Group	n	Before and after treatment	pulse condition				within the group		Between groups	
			normal	Shen Xi	thin strings	other	χ^2	P	χ^2	P
Treatment group	40	Before therapy	6	26	6	3	1.732	0.630	0.078	0.995
		After treatment	10	21	6	3				
Control group	40	Before therapy	5	23	7	4	1.372	0.712		
		After treatment	9	22	6	3				

DISCUSSION

Primary duodenal adenocarcinoma is a rare but aggressive tumor associated with poor prognosis. The low incidence and insufficient therapy data are obstacle on the consensus of oncologic treatment (16). In this study, we revealed that participants in the treatment group showed improved treatment performance relative to those in the control group, and the treatment group showed higher treatment efficacy to prevent nausea and vomiting and improved symptoms such as poor appetite and abnormal stool.

Banxia Xiexin Decoction is a classical medical formula designed by Zhang Zhongjing for the treatment of cold-heat complex in the Han Dynasty. It is mainly applied in the treatment of vomiting, diarrhea, epigastric distention and fullness, and tongue greasiness and yellowing (17). Previous studies have also demonstrated the effectiveness of this prescription for the therapy of digestive tumors (12, 18, 19). Accumulating evidence shows that Banxia Xiexin Decoction is efficient and reliable for the therapy of chronic atrophic gastritis (20, 21). In our work, the treatment effects of compound synergistic Banxia Xiexin decoction on duodenal cancer was observed and evaluated using enhanced CT scan. We demonstrated that the control rate after the administration of BXD reached 33.00% and the total effective value reached 93.50%, which were evidently higher than those without BXD treatment with a control rate of 14.00% and the total effective value of 87.00%. It is indicated that Banxia Xiexin Decoction can attenuate the side effects induced by chemotherapy and also enhance anti-tumor effects on primary duodenal adenocarcinoma.

Nausea or vomiting are common side effects in the chemotherapy of duodenal cancer (22). Clinically, the Banxia Xiexin Decoction can harmonize liver and spleen, dissipate distension syndrome, disperse nodule, enrich qi, and nourish Yin (23). In TCM, the syndromes of patients are judged based on the tongue manifestation, pulse palpation and other specific symptoms (24). Moreover, it is reported that the Banxia Xiexin Decoction has the effects of improving gastrointestinal motility (25).

In this study, the symptoms including vomiting and nausea were significantly improved in the treatment group, while the symptoms such as bloating after eating, tiredness and pale complexion were not significantly improved. Additionally, we found that the tongue quality, tongue coating as well as the pulse condition of patients in the two groups showed no statistical difference.

Currently, Banxia Xiexin Decoction has a wide range of pharmacological effects in the modern pharmacological research, and many pharmacological effects have achieved definite curative effect in clinical treatment (11, 17, 26). It is mainly effective for

gastrointestinal diseases such as ulcers and tumors, and also plays a certain role in regulating human endocrine metabolism, regulating neurotransmitters, and improving mood⁽¹⁰⁾. The results of our study also supported the effectiveness of Banxia Xiexin Decoction combined with chemotherapy in duodenal cancer. In clinical practice, Banxia Xiexin Decoction can be used as a Chinese herbal formula in full, disassembled, modified, or combined with other formulas or Western medicines, which can improve clinical efficacy, delay and block the occurrence and development of adverse events. With its affordable price, wide range of effects and high safety, it is worthy of in-depth research and application.

In conclusion, the effectiveness of Banxia Xiexin decoction is demonstrated in the combined treatment with chemotherapy for duodenal cancer patients, which prevents and controls the side effects such as nausea and vomiting and enhances the treatment efficacy, providing a promising option for medical treatment of duodenal cancer.

ACKNOWLEDGMENT

None.

Funding: None.

Conflicts of interests: The authors declare no conflicts of interest in this study.

Ethical consideration: This study was approved by the Ethics Committee of The People's Hospital of Changshou Chongqing (approval number: CQ2020-01L).

Author contribution: Yang Gou, Hongze Zhou conceived and designed the study; Yang Gou collected the clinical data; Yang Gou and Hongze Zhou conducted the data analysis; Yang Gou wrote the draft manuscript and Hongze Zhou reviewed and edited the manuscript; Both authors approved the final version of manuscript.

REFERENCES

- Zhang Z, Lei Y, Wang D, et al. (2022) Case Report: A case of advanced duodenal adenocarcinoma in complete remission after chemotherapy combined with targeted therapy and radiotherapy. *Frontiers in Oncology*, **12**: 968110.
- Manur JG and Jain HM (2021) A case of duodenal adenocarcinoma treated with primary chemoradiation. *Journal of Cancer Research and Therapeutics*, **17**(4): 1101-3.
- Yamamoto N, Washimi K, Murakawa M, et al. (2021) Primary Duodenal Carcinoma with Embryonal Carcinoma Features in a Young Man. *Case Reports in Gastroenterology*, **15**(1): 269-75.
- Jiang S, Zhao R, Li Y, et al. (2018) Prognosis and nomogram for predicting postoperative survival of duodenal adenocarcinoma: A retrospective study in China and the SEER database. *Scientific Reports*, **8**(1): 7940.
- Cloyd JM, George E, Visser BC (2016) Duodenal adenocarcinoma: Advances in diagnosis and surgical management. *World Journal of Gastrointestinal Surgery*, **8**(3): 212-21.
- Meijer LL, Alberga AJ, de Bakker JK, et al. (2018) Outcomes and Treatment Options for Duodenal Adenocarcinoma: A Systematic Review and Meta-Analysis. *Annals of Surgical Oncology*, **25**(9): 2681-92.
- García-Molina FJ, Mateo-Vallejo F, Franco-Osorio Jde D, et al. (2015) Surgical approach for tumours of the third and fourth part of the duodenum. Distal pancreas-sparing duodenectomy. *International Journal of Surgery (London, England)*, **18**: 143-8.
- Teschke R, Wolff A, Frenzel C, et al. (2015) Herbal traditional Chinese medicine and its evidence base in gastrointestinal disorders. *World Journal of Gastroenterology*, **21**(15): 4466-90.
- Song H, Qiu J, Yu C, et al. (2022) Traditional Chinese Medicine prescription Huang-Qi-Jian-Zhong-Tang ameliorates indomethacin-induced duodenal ulcers in rats by affecting NF-κB and STAT signaling pathways. *Biomedicine & pharmacotherapy = Biomedecine & Pharmacotherapie*, **156**: 113866.
- Wang W, Gu W, He C, et al. (2022) Bioactive components of Banxia Xiexin Decoction for the treatment of gastrointestinal diseases based on flavor-oriented analysis. *Journal of ethnopharmacology*, **291**: 115085.
- Feng X, Xue F, He G, et al. (2021) Banxia xiexin decoction affects drug sensitivity in gastric cancer cells by regulating MGMT expression via IL-6/JAK/STAT3-mediated PD-L1 activity. *International Journal of Molecular Medicine*, **48**(2):1-11.
- Su L, Wang MM, Xu MR, et al. (2019) Banxia Xiexin Decoction () Combined with Afatinib in Treatment of Advanced Gallbladder Cancer: Case Report and Literature Review. *Chinese Journal of Integrative Medicine*, **25**(4): 303-6.
- Zhang Z, Jia G, Pan G, et al. (2022) Comparison of the diagnostic efficacy of (68) Ga-FAPI-04 PET/MR and (18)F-FDG PET/CT in patients with pancreatic cancer. *European Journal of Nuclear Medicine and Molecular Imaging*, **49**(8): 2877-88.
- Ando A, Hagiwara Y, Sekiguchi T, et al. (2020) Contrast-enhanced magnetic resonance imaging revealing the joint capsule pathology of a refractory frozen shoulder. *The Open Orthopaedics Journal*, **14**(1):39-45.
- Hu W, Liu Z, Xiao X, et al. (2020) Comparison of diagnostic efficacy of MRI and PET/CT in lung cancer of mouse with spinal metastasis. *Cellular and Molecular Biology (Noisy-le-Grand, France)*, **66**(3): 138-42.
- Jensen KK, Storkholm JH, Chen I, et al. (2022) Long-term results after resection of primary duodenal adenocarcinoma: A retrospective cohort study. *International journal of surgery (London, England)*, **100**: 106599.
- Lu H, Qin J, Han N, et al. (2018) Banxia Xiexin Decoction Is Effective to Prevent and Control Irinotecan-Induced Delayed Diarrhea in Recurrent Small Cell Lung Cancer. *Integrative cancer therapies*, **17**(4): 1109-14.
- Yan S, Yue Y, Wang J, et al. (2019) Banxia Xiexin decoction, a traditional Chinese medicine, alleviates colon cancer in nude mice. *Annals of Translational Medicine*, **7**(16): 375.
- Feng X, Xue F, He G, et al. (2021) Banxia Xiexin Decoction Inhibits the Expression of PD-L1 Through Multi-Target and Multi-Pathway Regulation of Major Oncogenes in Gastric Cancer. *OncoTargets and Therapy*, **14**: 3297-307.
- Ji Q, Yang Y, Song X, et al. (2020) Banxia Xiexin Decoction in the treatment of chronic atrophic gastritis: A protocol for systematic review and meta-analysis. *Medicine*, **99**(42): e22110.
- Cao Y, Zheng Y, Niu J, et al. (2020) Efficacy of Banxia Xiexin decoction for chronic atrophic gastritis: A systematic review and meta-analysis. *PLoS One*, **15**(10): e0241202.
- Kim K, Chie EK, Jang JY, et al. (2012) Role of adjuvant chemoradiotherapy for duodenal cancer: a single center experience. *American Journal of Clinical Oncology*, **35**(6): 533-6.
- Wang J, Yang B, Li L (2019) Effect of Banxia Xiexin decoction combined with weifuchun on serum epidermal growth factor, serum pepsinogen and gastrin expression in patients with chronic atrophic gastritis. *Jo Liaoning Coll Tradit Chin Med*, **21**: 154-7.
- Ji Q, Luo YQ, Wang WH, et al. (2016) Research advances in traditional Chinese medicine syndromes in cancer patients. *Journal of Integrative Medicine*, **14**(1): 12-21.
- Tian J, Li M, Liao J, et al. (2013) Chinese herbal medicine banxia-xiexin decoction treating diabetic gastroparesis: a systematic review of randomized controlled trials. *Evidence-based complementary and alternative medicine : eCAM*, **2013**: 749495.
- Wang B, Zeng KW, Hong ZF, et al. (2020) Banxia Xiexin Decoction () Treats Diabetic Gastroparesis through PLC-IP(3)-Ca(2+)/NO-cGMP-PKG Signal Pathway. *Chinese Journal of Integrative Medicine*, **26**(11): 833-8.

