

Breast-specific gamma imaging versus ultrasound and mammography for breast cancer diagnosis: A meta-analysis

Y. Zhang¹, D. Zhu², R. Feng^{3*}

¹Department of General Surgery, ²Department of Radiology, ³Department of Orthopedics, the Ninth Affiliated Hospital of Guangxi Medical University, Beihai, Guangxi Province, China

► Original article

ABSTRACT

*Corresponding author:

Ruibin Feng, MMed,

E-mail:

fengruibin0915@163.com

Received: February 2023

Final revised: June 2023

Accepted: June 2023

Int. J. Radiat. Res., January 2024;
22(1): 27-33

DOI: 10.52547/ijrr.21.1.5

Keywords: BSGI, ultrasound, mammography, breast cancer, meta-analysis.

Background: Breast cancer (BC) is presently reported to have the highest incidence of cancer in females globally. Several imaging methods are available for early BC diagnosis and for improving its treatment outcomes. The present meta-analysis compared the effectiveness of breast-specific gamma imaging (BSGI), mammography, and ultrasound for diagnosing BC. **Material and Methods:** Relevant studies on this topic were retrieved from the PubMed, Scopus, and EMBASE databases. Pooled sensitivity and specificity as well as the area under the curve (AUC) value of a summary receiver operating characteristic (SROC) curve of the three imaging modalities were compared. **Results:** Ten studies were retrieved, which included 2621 lesions from 2482 patients. The pooled sensitivity values of BSGI, ultrasound, and mammography were 0.90, 0.88, and 0.75, respectively (95% confidence interval (CI): 0.88-0.91, 0.86-0.89, and 0.72-0.77, respectively). The pooled specificity values of BSGI, ultrasound, and mammography were 0.83, 0.67, and 0.76, respectively (95% CI: 0.81-0.85, 0.64-0.69, and 0.74-0.78, respectively). The AUC values of BSGI, ultrasound, and mammography were 0.9355, 0.8644, and 0.8221, respectively. **Conclusions:** Compared to ultrasound and mammography, BSGI has the best diagnostic performance to discern malignant and benign breast lesions and could play a crucial role in diagnosing BC in women who have dense breasts.

INTRODUCTION

Breast cancer (BC) has emerged as a prevalent cancer in women worldwide ⁽¹⁾. Several imaging modalities have been developed for the prompt diagnosis of BC and for improving treatment outcomes ⁽²⁾. The optimal strategy to detect BC, however, remains unclear. Although mammography is frequently used to detect BC and has excellent sensitivity and specificity ⁽³⁾, it shows diminished accuracy for BC detection in women having dense breasts ⁽⁴⁾. Rice *et al.* identified mammographic breast density as a high-risk factor for BC ⁽⁵⁾. Thus, the assessment of supplemental imaging modalities is crucial for enhancing the accuracy of early BC diagnosis ⁽⁶⁾.

Ultrasound, as an adjunct to mammography, is also frequently used to diagnose BC and exhibits an additive effect regarding patient benefits ⁽⁷⁾. Ultrasound does not use ionizing radiation, which is its main advantage over mammography. Furthermore, ultrasound combined with mammography could accelerate the BC detection rate in women who have dense breasts ⁽⁸⁾. Ultrasound is, however, highly an operator-dependent process; consequently, it can yield a high false-positive detection rate in breasts with high density ⁽⁹⁾.

Breast-specific gamma imaging (BSGI), a scintigraphy method, involves administering

technetium-99m (^{99m}Tc)-sestamibi. This radiotracer's distribution is determined using a gamma camera with a small field of view and high resolution that is designed specifically to detect BC ⁽¹⁰⁾. Unlike ultrasound, which is an anatomical method, BSGI uses the principle of functional imaging to diagnose BC that cannot be easily detected by mammography ⁽¹¹⁾. This technique is advantageous because (1) its sensitivity is not altered by breast density and (2) it is not operator-dependent ⁽¹²⁾. Although BSGI is highly sensitive and specific in detecting BC ⁽¹³⁻¹⁴⁾, very few studies have evaluated the diagnostic efficacy of this technique relative to mammography and ultrasound in the same cohort of patients ⁽¹⁵⁾.

Moreover, because BSGI exposes the entire body to ionizing radiation, it is not used routinely in clinical practice. Therefore, in the present meta-analysis, we aimed to compare BSGI, mammography, and ultrasound with regard to their diagnostic relevance in distinguishing malignant and benign BC lesions and thus evaluate BSGI's performance in routine clinical practice. We believe that the present meta-analysis is the first to compare the relative diagnostic efficacy of these three diagnostic modalities for BC. Our work will help clinicians to make informed decisions regarding the application of BSGI for screening patients with BC in clinical settings.

MATERIALS AND METHODS

This meta-analysis is registered on the International Platform of Registered Systematic Review and Meta-analysis Protocols (INSPLAY). The trial registration number is INPLASY202230148 (doi: 10.37766/inplasy2022.3.0148).

Search strategy

The EMBASE, PubMed, and Scopus databases were reviewed systematically, and all relevant studies published up to December 30, 2021, were retrieved. No language restrictions were applied during the search strategy. The search terms used were as follows: “breast neoplasms” or “breast cancer” or “breast carcinoma” and “BSGI” or “breast-specific gamma imaging” or “molecular breast imaging.” After initial search was completed, we performed a manual search of the references of the relevant studies to identify more articles.

Inclusion and exclusion criteria

We included (1) studies that examined at least 30 patients with BSGI, ultrasound, and mammography, (2) studies that described the histopathological assessment of the lesion, and (3) studies that provided adequate data for the meta-analysis. Based on these criteria, we excluded reviews, letters, comments, case reports, and conference abstracts. The data of patients who underwent chemotherapy and studies with incomplete data were also excluded.

Data extraction

Two researchers independently extracted the data. For constructing 2×2 contingency tables, true-positive (TP) and true-negative (TN) as well as false-positive (FP) and false-negative (FN) values were extracted directly or calculated from the provided data. Both researchers resolved the disagreements through discussion until they reached a consensus.

Quality assessment

Two researchers independently evaluated the applicability and quality of the chosen studies by using the Quality Assessment of Diagnostic Accuracy Studies 2 (QUADAS-2) tool. Both researchers addressed any disagreements through discussion until they reached a consensus⁽¹⁶⁾.

Statistical analysis

The TP, TN, FP, and FN values were extracted or calculated from the selected articles and statistically analyzed using the MetaDisc software version 1.4 (Universidad Complutense, Madrid, Spain). Threshold effects on heterogeneity were evaluated using Spearman's correlation coefficient and deemed significant at $P < 0.05$. Heterogeneity was also tested using the inconsistency index (I^2) test and the Cochran-Q test. $P < 0.05$ and $I^2 > 50\%$ suggest the

presence of heterogeneity⁽¹⁷⁾ we estimated publication bias by plotting a Deek's funnel plot with STATA version 14.0 (Stata Corp, College Station, TX, USA). Furthermore, $P < 0.05$ indicated significant publication bias⁽¹⁸⁾. For significant heterogeneity, the random-effects model was applied for statistical analysis. Furthermore, pooled sensitivity and specificity as well as diagnostic odds ratio (DOR), positive likelihood ratio (PLR), and negative likelihood ratio (NLR) together with their 95% confidence intervals (95% CIs) were estimated and compared for the three imaging modalities. The area under the curve (AUC) value of a summary receiver operating characteristic (SROC) curve was also analyzed.

RESULTS

Literature search

The initial search retrieved 563 articles. Forty potentially eligible studies were selected, and following detailed evaluations, 10 best-matched articles were chosen for final meta-analysis. The flowchart for selecting articles is depicted in figure 1.

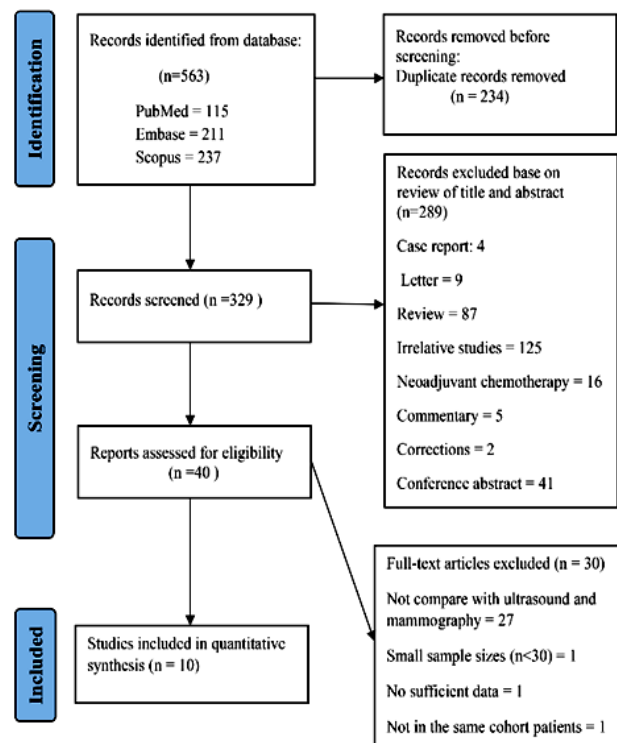


Figure 1. Flowchart showing literature identification and selection.

Features of the included articles and their quality assessment

The 10 selected studies^(12, 19-27) involved 2621 lesions in 2482 patients, of which 1303 (49.7%) were malignant lesions and 1318 (50.3%) were benign lesions. Table 1 summarizes the features of these studies. Nine studies (90%) used a retrospective design, while only 1 study adopted a prospective

research design. The studies were conducted in China (n=4), Korea (n=4), the United States (n=1), and Austria (n=1). Figure 2 illustrates the results of the QUADAS-2 tool for examining the quality of the

methodology used in the studies. A moderately high QUADAS-2 score was obtained for the studies, thereby indicating good methodological quality.

Table 1. Characteristics of the 10 studies included in the meta-analysis.

Study	Country	Study Design	Patients/ Lesions (n)	Mean Age (range)	Benign/Malignant Lesions(n)	Reference Standard
Kim et al. 2012 ⁽¹²⁾	Korea	Retro	121/228	45.0± 8.1	75/153	Biopsy
Lee et al. 2012 ⁽¹⁹⁾	Korea	Retro	471/474	49.63±10.43	364/110	Biopsy Follow up
Weigert et al. 2012 ⁽²⁰⁾	USA	Retro	329/329	NR	196/133	Biopsy Follow up
Park et al. 2014 ⁽²¹⁾	Korea	Retro	114/118	49.6 ±9.8	76/42	Biopsy Follow up
Meissnitzer et al. 015 ⁽²²⁾	Austria	Pro	67/92	NR	25/67	Biopsy
Cho et al. 2016 ⁽²³⁾	Korea	Retro	162/162	NR	96/66	Biopsy Surgical pathology
Yu et al. 2016 ⁽²⁴⁾	China	Retro	287/287	48.2 (32-75)	119/168	Surgical pathology
Liu-1 et al. 2020 ⁽²⁵⁾	China	Retro	177/177	53.5 (23-89)	60/117	Biopsy Surgical pathology
Liu-2 et al. 2020 ⁽²⁶⁾	China	Retro	390/390	49.7(23–89) ^a 45.3(19–74) ^b	161/229	Biopsy Surgical pathology
Zhang et al. 2020 ⁽²⁷⁾	China	Retro	364/364	50.12 ± 10.92 (23-79)	146/218	Biopsy Surgical pathology

a: Malignant group; b: Benign group; Retro: Retrospective; Pro: Prospective; NR: Not reported.

Heterogeneity tests and publication bias

No significant threshold effect was noted for BSGI (P=0.829), ultrasound (P=0.446), and mammography (P=0.244). However, the Cochran-Q and I^2 values of DOR for BSGI (P=0.01 and 68.7%, respectively), ultrasound (P=0.01 and 68.7%, respectively), and mammography (P=0.00 and 87.6%, respectively) were below 0.05 and above 50%, respectively, thus indicating the studies had substantial heterogeneity. Hence, we applied the random-effects model to pool the statistical data from the 10 studies. Deek's funnel plots revealed no significant publication bias for all 3 modalities (figure 6).

Pooled diagnostic values

Table 2 presents the pooled specificity and sensitivity, DOR, PLR, and NLR of BSGI, ultrasound, and mammography determined according to the random-effects meta-analysis model. Figures 3 and 4 show the forest plots for sensitivity and specificity, respectively. BSGI had the highest sensitivity (0.90) followed by ultrasound (0.88) and mammography (0.75). Similarly, BSGI showed the highest specificity (0.83), followed by mammography (0.76) and ultrasound (0.67). Figure 5 illustrates the SROC for each modality. The AUC values to differentiate malignant and benign BC lesions for BSGI, ultrasound, and mammography were 0.9355, 0.8644, and 0.8221, respectively (standard error [SE] = 0.015, 0.065, and 0.038, respectively). Our data indicated that compared to mammography and ultrasound, BSGI exhibited the best diagnostic performance to discern malignant BC lesions from benign BC lesions.

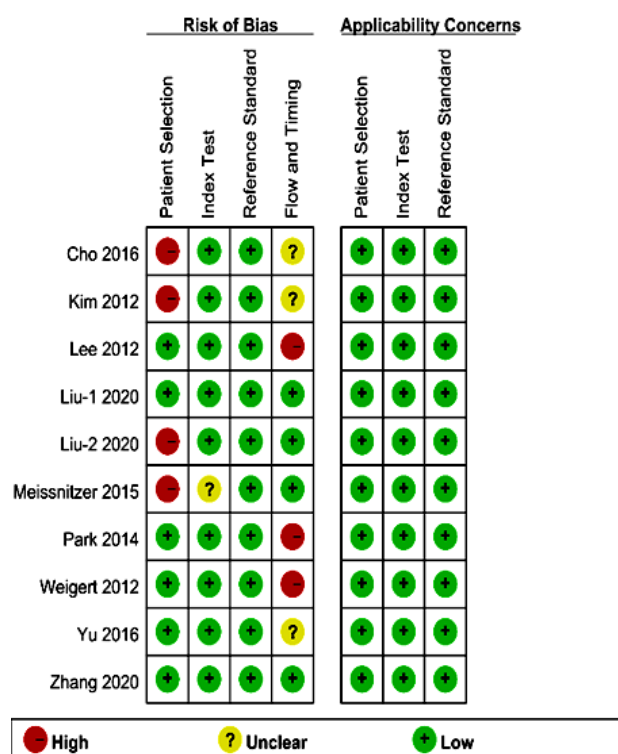


Figure 2. Quality evaluation of all 10 studies included in the meta-analysis according to QUADAS-2.

Table 2. Meta-analysis of the diagnostic performance of three image modalities.

Technology	Sensitivity (95% CI)	Specificity (95% CI)	P LR (95% CI)	NLR (95% CI)	DOR (95% CI)	AUC
BSGI	0.90 (0.88-0.91)	0.83 (0.81-0.85)	5.09 (3.66-7.07)	0.13 (0.09-0.18)	43.02 (27.20-68.06)	0.9355
Ultrasound	0.88 (0.86-0.89)	0.67 (0.64-0.69)	2.37 (1.61-3.47)	0.19 (0.13-0.28)	13.99 (7.82-25.02)	0.8644
Mammography	0.75 (0.72-0.77)	0.76 (0.74-0.78)	2.80 (1.90-4.14)	0.35 (0.27-0.46)	8.91 (4.94-16.07)	0.8221

P LR: positive likelihood ratio; NLR: negative likelihood ratio; DOR: diagnostic odds ratio; CI: confidence interval

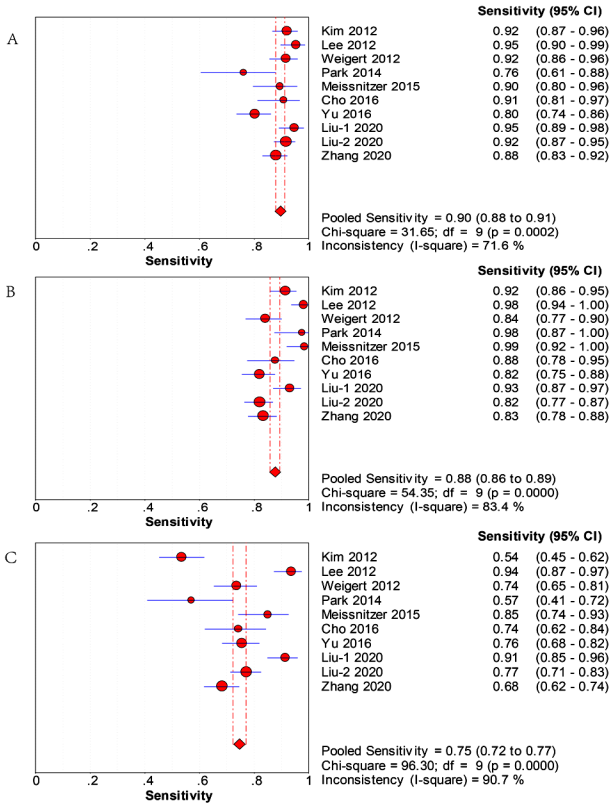


Figure 3. Forest plots for sensitivity of the included studies using BSGI (A), ultrasound (B), and mammography (C). CI: confidence interval.

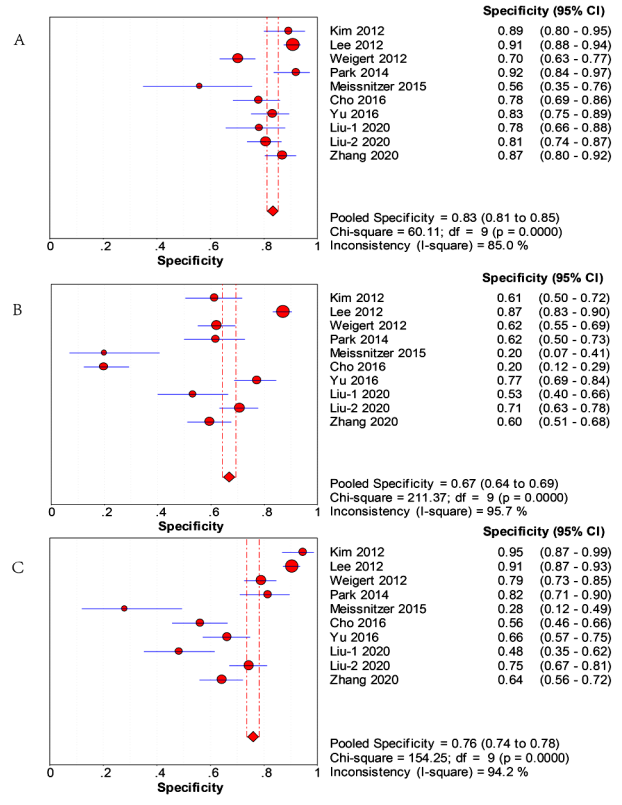


Figure 4. Forest plots for specificity of the included studies using BSGI (A), ultrasound (B), and mammography (C). CI: confidence interval.

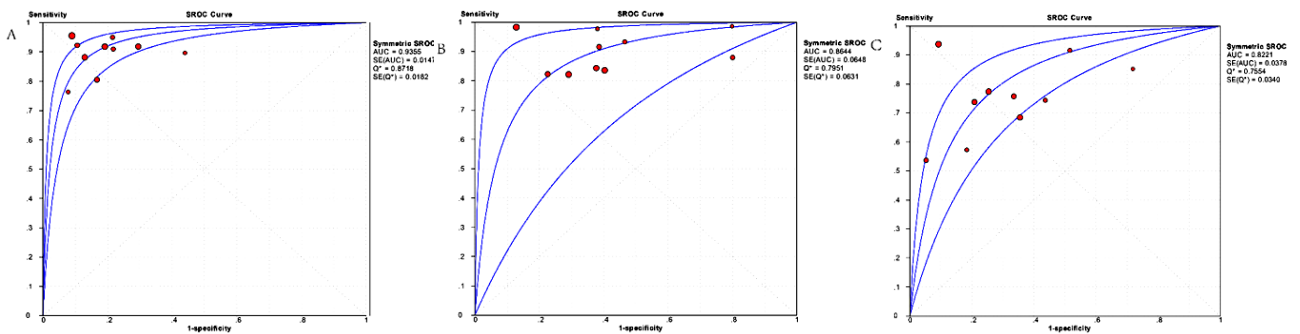


Figure 5. Summary receiver operating characteristic curves of BSGI (A), ultrasound (B), and mammography (C). AUC: area under the curve; SROC: summary receiver operating characteristic; SE: standard error.

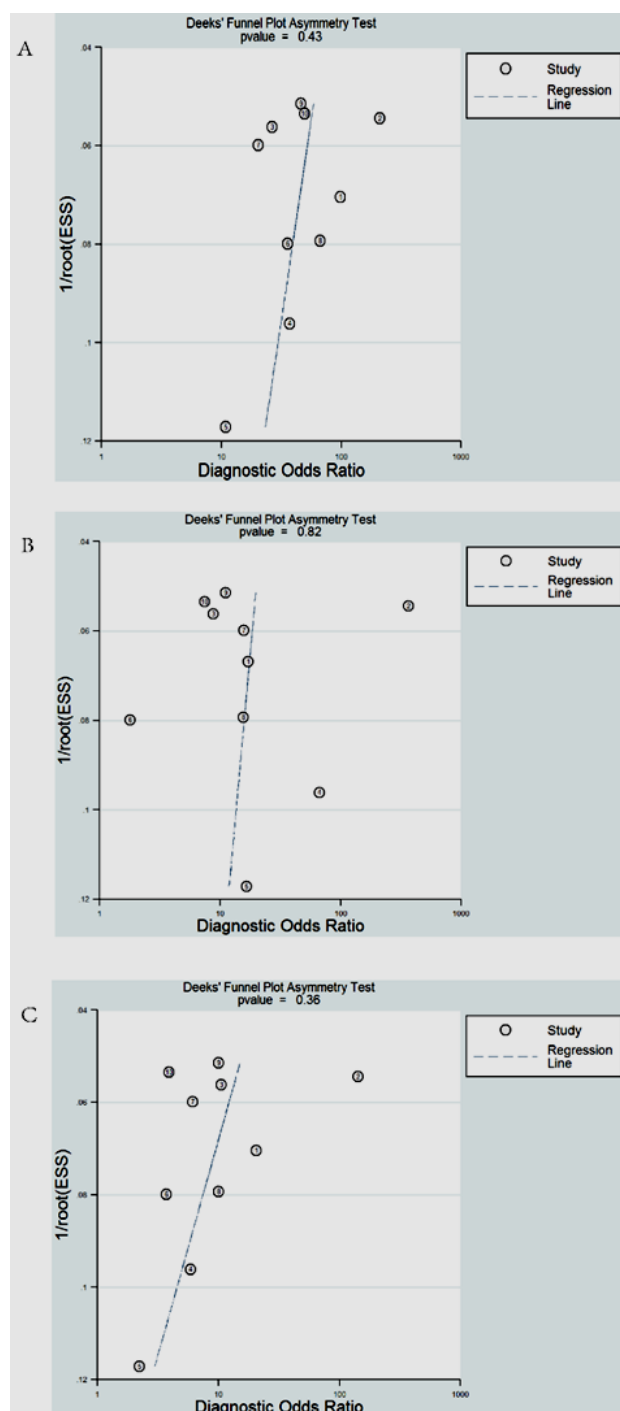


Figure 6. Publication bias of BSGI (A), ultrasound (B), and mammography (C) using Deek's funnel plot.

DISCUSSION

An early diagnosis of BC is essential to decrease BC-related mortality. In preceding years, mammography has remained the gold standard for detecting BC. However, BC often manifests as no calcified masses, which might not be easily diagnosed by mammography, particularly in Asian women who have dense breasts⁽²⁸⁾. The density of a breast is an additional risk factor that could lead to BC^(5, 29);

therefore, supplemental imaging modalities are required. Physiological imaging as a supplementary imaging technique can enhance BC detection. According to previous studies, BSGI has a high sensitivity to detect BC and could be used together with other imaging techniques in women, regardless of their breast density⁽¹³⁾. In a retrospective study by Chung et al., 266 women having 302 BC lesions were examined; the authors observed that BSGI exhibited higher specificity than adjunctive ultrasound with no sensitivity loss for detecting BC in women showing calcifications diagnosed through mammography; this indicated that adjunctive BSGI could function as a complementary imaging technique for early BC detection in women showing suspicious findings on mammography⁽¹⁵⁾. Consistent with these findings, Yu *et al.* showed a higher specificity of BSGI than that of ultrasound, mammography, or magnetic resonance imaging (MRI) to diagnose BC lesions; moreover, BSGI exhibited a high sensitivity for distinguishing ductal carcinoma in situ⁽²⁴⁾. Similarly, in our meta-analysis, BSGI exhibited superior diagnostic performance in discerning benign and malignant lesions in BC patients and thus could be a critical method for clinically diagnosing BC in women who have dense breasts. In this meta-analysis, several studies were conducted in Chinese and Korean populations. Among these Asian populations, around 75% of the participants had heterogeneously or exceedingly dense breasts. BSGI shows high diagnostic effectiveness, particularly regarding specificity, for women with dense breasts^(19, 25). Our combined results revealed that BSGI had the highest specificity, sensitivity, as well as diagnostic efficacy compared to ultrasound and mammography. These findings indicate that BSGI can show excellent diagnostic performance for Asian women with heterogeneously or exceedingly dense breasts.

Furthermore, in our meta-analysis, BSGI had a PLR of 5.09, an NLR of 0.13, and an overall DOR of 43.02, thus indicating that it has high diagnostic efficacy for detecting breast lesions. Our findings were consistent with those of previous meta-analyses⁽¹⁴⁾ but differed slightly from the study of Tadesse *et al.*⁽³⁰⁾. The difference might be due to the difference in lesion characteristics and the image interpretation methods used in both studies. Chae *et al.* reported that BSGI showed relatively low diagnostic performance for multiple invasive lobular carcinomas⁽³¹⁾. However, Yu *et al.* revealed that BSGI had a high sensitivity for discriminating ductal carcinoma in situ⁽²⁴⁾. Moreover, compared to traditional planar scintigraphy, BSGI exhibited a high sensitivity in detecting tumors < 1 cm⁽³²⁾.

BSGI involves the administration of ^{99m}Tc-sestamibi, which tends to accumulate more in cancer cells than in normal cells. This differential uptake between cancer and normal cells facilitates using semi-quantitative tools to characterize BC

lesions ⁽²⁴⁾. Compared to a visual analysis alone, semi-quantitative analyses can significantly augment the distinction between benign and malignant breast lesions ⁽²¹⁾. In contrast, ultrasound examination with a handheld device lacks consistency in the process of image acquisition; moreover, image interpretation is exclusively an operator-dependent process.

BSGI, with excellent specificity, increases suspicious findings' detection in cases with negative results for ultrasound or mammography, thus suggesting that BSGI could facilitate to avoid conducting unnecessary invasive biopsies. However, some benign breast lesions such as fibrocystic breast disease, fibroadenomas, and benign breast hyperplasia can cause FP results in BSGI ⁽²¹⁾. In our meta-analysis, ^{99m}Tc-sestamibi was used as a nonspecific radiotracer for BSGI imaging in all studies, and it can be taken up and concentrated by hyperplastic benign lesions, thereby decreasing its diagnostic accuracy. BSGI also exposes the entire body to a radiation dose ranging from 6.29 to 9.44 mSv. Therefore, BSGI is frequently used to confirm the findings of inconclusive mammography results but not as an alternative ⁽¹⁴⁾. Nevertheless, the radiation dose of a BSGI scan can be substantially reduced by administering a lower dose of ^{99m}Tc-sestamibi. Rhodes et al. noted that a 300 MBq dose of ^{99m}Tc-sestamibi (2.4 mSv as the effective dose) can still have a high supplementary cancer detection rate of approximately 8.8/1000 women having mammographically dense breasts ⁽³²⁾. However, additional studies are required to confirm whether lower doses of ^{99m}Tc-sestamibi can offer the same diagnostic accuracy as standard doses.

There are a few limitations of our meta-analysis. First, the number of studies included was small. Therefore, more studies are required to validate these findings. Second, several included studies recruited only Asian populations. Asian women show a tendency to possess denser breasts. Therefore, the generalizability of the findings to other global populations is limited. Finally, high heterogeneity was noted among the selected studies; this may have limited comparing research findings between different studies.

CONCLUSION

Compared to ultrasound and mammography, BSGI showed the best diagnostic performance in discerning benign breast lesions and malignant breast lesions. However, this meta-analysis enrolled only 10 studies, with the majority of them being conducted in Asia. Consequently, additional research is required to generalize the findings of the present meta-analysis.

ACKNOWLEDGMENT

The authors would like to thank TopEdit

(www.topedit.com) for its linguistic assistance during the preparation of this manuscript.

Funding: This work did not receive any external funding.

Conflicts of interests: There are no competing interests to declare.

Ethical consideration: All the data included in this study were extracted from published articles.

Author contributions: Conceptualization, data curation, investigation, formal analysis, and writing original manuscript draft (YZ); investigation, formal analysis, and reviewing (DZ); investigation, formal analysis, reviewing, and editing (RF).

REFERENCES

1. Sung H, Ferlay J, Siegel RL, et al. (2021) Global Cancer Statistics 2020: GLOBOCAN estimates of incidence and mortality worldwide for 36 cancers in 185 countries. *CA Cancer J Clin*, **71**(3): 209-249.
2. Mann RM, Hooley R, Barr RG, Moy L (2020) Novel approaches to screening for breast cancer. *Radiology*, **297**(2): 266-285.
3. Drukteinis JS, Mooney BP, Flowers CI, Gatenby RA (2013) Beyond mammography: new frontiers in breast cancer screening. *Am J Med*, **126**(6): 472-479.
4. Pike MC and Pearce CL (2013) Mammographic density, MRI background parenchymal enhancement and breast cancer risk. *Ann Oncol*, **24**(8): viii37-viii41.
5. Rice MS, Bertrand KA, Vander Weele TJ, et al. (2016) Mammographic density and breast cancer risk: a mediation analysis. *Breast Cancer Res*, **18**(1): 94.
6. Oeffinger KC, Fontham ET, Etzioni R, et al. (2015) American Cancer Society. Breast cancer screening for women at average risk: 2015 guideline update from the American cancer society. *JAMA*, **314**(15): 1599-1614.
7. Ohuchi N, Suzuki A, Sobue T, et al. (2016) Sensitivity and specificity of mammography and adjunctive ultrasonography to screen for breast cancer in the Japan Strategic Anti-cancer Randomized Trial (J-START): a randomized controlled trial. *Lancet*, **387**(10016): 341-348.
8. Shen S, Zhou Y, Xu Y, et al. (2015) A multi-centre randomised trial comparing ultrasound vs mammography for screening breast cancer in high-risk Chinese women. *Br J Cancer*, **112**(6): 998-1004.
9. Berg WA, Zhang Z, Lehrer D, et al. (2012) Detection of breast cancer with addition of annual screening ultrasound or a single screening MRI to mammography in women with elevated breast cancer risk. *JAMA*, **307**(13): 1394-1404.
10. Jones EA, Phan TD, Blanchard DA, Miley A (2009) Breast-specific gamma-imaging: molecular imaging of the breast using ^{99m}Tc-sestamibi and a small-field-of-view gamma-camera. *J Nucl Med Technol*, **37**(4): 201-205.
11. Brem RF, Ruda RC, Yang JL, et al. (2016) Breast-specific γ -imaging for the detection of mammographically occult breast cancer in women at increased risk. *J Nucl Med*, **57**(5): 678-684.
12. Kim BS, Moon BI, Cha ES (2012) A comparative study of breast-specific gamma imaging with the conventional imaging modality in breast cancer patients with dense breasts. *Ann Nucl Med*, **26**(10): 823-829.
13. Rechtman LR, Lenihan MJ, Lieberman JH, et al. (2014) Breast-specific gamma imaging for the detection of breast cancer in dense versus nondense breasts. *AJR Am J Roentgenol*, **202**(2): 293-298.
14. Sun Y, Wei W, Yang HW, Liu JL (2013) Clinical usefulness of breast-specific gamma imaging as an adjunct modality to mammography for diagnosis of breast cancer: a systemic review and meta-analysis. *Eur J Nucl Med Mol Imaging*, **40**(3): 450-463.
15. Chung HW, So Y, Yang JH, et al. (2017) Adjunctive breast-specific gamma imaging for detecting cancer in women with calcifications at mammography. *Ann Surg Oncol*, **24**(12): 3541-3548.
16. Whiting PF, Rutjes AW, Westwood ME, et al. (2011) QUADAS-2: a revised tool for the quality assessment of diagnostic accuracy studies. *Ann Intern Med*, **155**(8): 529-536.

17. Higgins JP and Thompson SG (2002) Quantifying heterogeneity in a meta-analysis. *Stat Med*, **21**(11): 1539-1558.
18. Deeks JJ, Macaskill P, Irwig L (2005) The performance of tests of publication bias and other sample size effects in systematic reviews of diagnostic test accuracy was assessed. *J Clin Epidemiol*, **58** (9): 882-893.
19. Lee A, Chang J, Lim W, et al. (2012) Effectiveness of breast-specific gamma imaging (BSGI) for breast cancer in Korea: a comparative study. *Breast J*, **18**(5): 453-458.
20. Weigert JM, Bertrand ML, Lanzkowsky L, et al. (2012) Results of a multicenter patient registry to determine the clinical impact of breast-specific gamma imaging, a molecular breast imaging technique. *AJR Am J Roentgenol*, **198**(1): W69-75.
21. Park KS, Chung HW, Yoo YB, et al. (2014) Complementary role of semiquantitative analysis of breast-specific gamma imaging in the diagnosis of breast cancer. *AJR Am J Roentgenol*, **202**(3): 690-695.
22. Meissnitzer T, Seymer A, Keinrath P, et al. (2015) Added value of semi-quantitative breast-specific gamma imaging in the work-up of suspicious breast lesions compared to mammography, ultrasound and 3-T MRI. *Br J Radiol*, **88**(1051): 20150147.
23. Cho MJ, Yang JH, Yu YB, et al. (2016) Validity of breast-specific gamma imaging for Breast Imaging Reporting and Data System 4 lesions on mammography and/or ultrasound. *Ann Surg Treat Res*, **90**(4): 194-200.
24. Yu X, Hu G, Zhang Z, et al. (2016) Retrospective and comparative analysis of (99m)Tc-Sestamibi breast specific gamma imaging versus mammography, ultrasound, and magnetic resonance imaging for the detection of breast cancer in Chinese women. *BMC Cancer*, **16**: 450.
25. Liu H, Zhan H, Sun D (2020) Comparison of 99mTc-MIBI scintigraphy, ultrasound, and mammography for the diagnosis of BI-RADS 4 category lesions. *BMC Cancer*, **20**(1): 463.
26. Liu H, Zhan H, Sun D, Zhang Y (2020) Comparison of BSGI, MRI, mammography, and ultrasound for the diagnosis of breast lesions and their correlations with specific molecular subtypes in Chinese women. *BMC Med Imaging*, **20**(1): 98.
27. Zhang Z, Wang W, Wang X, et al. (2020) Breast-specific gamma imaging or ultrasonography as adjunct imaging diagnostics in women with mammographically dense breasts. *Eur Radiol*, **30**(11): 6062-6071.
28. Tozaki M, Isomoto I, Kojima Y, et al. (2015) The Japanese Breast Cancer Society Clinical Practice Guideline for screening and imaging diagnosis of breast cancer. *Breast Cancer*, **22**(1): 28-36.
29. Boyd NF, Guo H, Martin LJ, et al. (2007) Mammographic density and the risk and detection of breast cancer. *N Engl J Med*, **356**(3): 227-236.
30. Belhocine TZ, Blankenberg FG, Kartachova MS, et al. (2015) (99m) Tc-Annexin A5 quantification of apoptotic tumor response: a systematic review and meta-analysis of clinical imaging trials. *Eur J Nucl Med Mol Imaging*, **42**(13): 2083-2097.
31. Chae IH, Cha ES, Lee JE, et al. (2018) Invasive Lobular Carcinoma: Detection and Multiplicity with Multimodalities. *Ewha Med J*, **41** (2): 27-34.
32. Rhodes DJ, Hruska CB, Conners AL, et al. (2015) Journal club: molecular breast imaging at reduced radiation dose for supplemental screening in mammographically dense breasts. *AJR Am J Roentgenol*, **204**(2): 241-251.

