

Diagnostic efficiency of DCE-MRI combined with DWI for breast cancer and the relationship between imaging characteristics and molecular biological markers

F. Guo^{1,2,#}, L. Zhu^{1,2,#}, C. Ma^{1,3}, M. Zou^{1,3}, Y. Gao^{1,3}, N. Lv^{1,3}, Q. Qi^{4*}

¹Department of Radiology, the First Affiliated Hospital of Bengbu Medical University, Bengbu, China

²School of Medical Imaging, Bengbu Medical University, Bengbu, China

³Graduate School, Bengbu Medical University, Bengbu, China

⁴School of Basic Medicine, Bengbu Medical University, Bengbu, China

ABSTRACT

► Original article

*Corresponding author:

Qi Qi, BM.,

E-mail: qq233003@163.com

Received: February 2023

Final revised: March 2024

Accepted: March 2024

Int. J. Radiat. Res., October 2024;
22(4): 955-961

DOI: 10.61186/ijrr.22.4.955

Keywords: Breast cancer, dynamic contrast-enhanced magnetic resonance imaging, diffusion-weighted imaging, molecular biology, marker.

#These authors contributed equally to this work as co-first author.

Background: To analyze the diagnostic efficiency of DCE-MRI combined with DWI for breast cancer and the relationship between imaging characteristics and molecular biological markers. **Materials and Methods:** A total of 120 patients with suspected breast lesions in the hospital were enrolled between January 2021 and October 2023, all underwent MRI examination to obtain DCE-MRI and DWI data. Taking results of pathological diagnosis as the golden standard, diagnostic efficiency of DCE-MRI combined with DWI for breast cancer was analyzed by Kappa consistency test. The expressions of ER, PR, HER-2 and Ki-67 in cancer tissues was detected by immunohistochemistry. The relationship between DCE-MRI, DWI characteristics and molecular biological markers was analyzed. **Results:** The consistency Kappa value between MRI and pathology 0.817, and its sensitivity, specificity and accuracy were 96.05%, 84.09% and 91.67%, respectively. In patients with breast cancer, tumor diameter was significantly correlated with the expressions of ER, HER-2 and Ki-67 in cancer tissues, tumor morphology was significantly correlated with the expressions of ER, PR, HER-2 and Ki-67, tumor margin was significantly correlated with the expressions of ER and PR, TIC type was significantly correlated with Ki-67 expression, EPER was significantly correlated with HER-2 expression, TTP was significantly correlated with Ki-67 expression, ADC value was significantly correlated with Ki-67 expression, and the above differences were statistically significant ($P < 0.05$). **Conclusion:** DCE-MRI combined with DWI has high diagnostic efficiency for breast cancer, and their imaging characteristics are related to molecular biological markers to some extent. Imaging examination can further reflect biological behaviors of breast cancer indirectly.

INTRODUCTION

The incidence of breast cancer ranks the first among female malignant tumors. According to the latest data from the 2020 International Agency for Research on Cancer survey, the number of new breast cancer in the world has reached 2.26 million, exceeding lung cancer for the first time and becoming the "world's leading cancer" ⁽¹⁾. In China, breast cancer is also the most common cancer in women. The incidence of breast cancer is increasing at about 4% per year, and the age tends to be younger gradually ⁽²⁾. There are no specific symptoms in the early stage of breast cancer, which is easy to be ignored and not treated in time. Because the etiology of breast cancer is not clear, it is impossible to carry out primary prevention from the etiology, but from the observation of the effect of breast cancer treatment, the earlier the treatment of early breast cancer, the better the effect. Therefore, it is necessary

to pay attention to the early detection of breast cancer and carry out breast cancer screening to improve the survival rate of breast cancer patients. With the development of science and technology, there are more and more imaging methods for breast diseases. Magnetic resonance imaging (MRI) is the most sensitive imaging technology for early detection of breast cancer. It has the advantages of multi-parameter, multi-sequence and functional imaging, which can evaluate the changes of tumor morphology, hemodynamics and tissue function metabolism, and can also show the relationship between tumor and chest wall, axillary lymph node metastasis, etc. It provides a more reliable basis for making surgical plans ⁽³⁾. Diffusion-weighted imaging (DWI) is a new MRI imaging technology that appeared in the late 20th century. Dwi can directly reflect the diffusion characteristics of water molecules in human tissues, and it is the only non-invasive imaging technology to detect the

diffusion motion of water in the human body. dynamic contrast-enhanced magnetic resonance imaging (DCE-MRI) can directly process the original image data, not only can diagnose the body's blood circulation state, It is also possible to quantify the pathophysiological characteristics of the responding tissue based on the parameters of multiple microcirculation ^(4,5). This study aims to analyze the diagnostic efficacy of DCE-MRI combined with DWI in breast cancer and the relationship between imaging features and molecular biological markers, in order to improve clinical understanding of the disease and provide more diagnostic basis. Over the past few decades, diagnostic techniques for breast cancer have made significant progress. However, with the increasing demand for early detection and personalized treatment strategies, there is an urgent need for more precise diagnostic tools and methods. Although Dynamic Contrast-Enhanced Magnetic Resonance Imaging (DCE-MRI) and Diffusion-Weighted Imaging (DWI) have been used separately for the diagnosis and characterization of breast cancer, the potential of their combined application to improve diagnostic accuracy has not been fully explored. This study analyzes the comprehensive efficacy of DCE-MRI and DWI combined for the diagnosis of breast cancer and for the first time, delves into the relationship between imaging features and molecular biological markers of breast cancer. Our findings not only underscore the importance of this combined strategy in enhancing the early detection rate of breast cancer but also provide a new perspective for understanding the molecular biology characteristics of breast cancer through imaging technology. Furthermore, this study provides important scientific evidence for the use of imaging data to devise personalized treatment plans, opening new avenues for the management of breast cancer.

MATERIAS AND METHODS

Study design

From January 2021 to October 2023, suspected breast lesions in our hospital were selected as the research objects, and all were female. Inclusion criteria: 1. Suspected breast cancer by ultrasound and clinical examination; 2. MRI examination could be performed in all patients without relevant contraindications; 3. Informed consent of patients and their families. Exclusion criteria: 1. Previous history of breast surgery; 2. The presence of other malignant tumors; 3. The presence of infectious diseases or immune system disorders; 4. Serious injury of vital organs; 5. Previous history of cardiac pacemaker therapy; 6. MRI could not be completed due to the presence of metallic foreign bodies; 7. Patients with epilepsy and claustrophobia.

This study was approved by the ethics committee.

Signed written informed consents were obtained from the patients and/or guardians.

Management

MRI examination

A Philips Achieva 3.0T dual-gradient MRI scanner manufactured in the Netherlands, equipped with a SENSE 7 breast dedicated coil, was utilized. The patient was in a prone position, and the bilateral breasts were naturally overhanging in the center of the breast coil. It was necessary to ensure that all breast tissue was in the coil, there was no wrinkle between the skin and the breast, the bilateral breasts were symmetrical, the nipples were perpendicular to the ground, and the sternal midline was on the midline of the coil.

Axial T1 Weighted Image (T1WI) parameters of fat suppression: Repetition Time (TR) was 400 ms, Echo Time (TE) was 10 ms, FOV was 350 mm×350 mm, matrix was 234×225, slice thickness was 4.5 mm, slice spacing was 1 mm.

T2 Weighted Image (T2WI) parameters: TR was 5000 ms, TE was 60 ms, FOV was 350 mm×350 mm, matrix was 336×303, slice thickness was 4.5 mm and slice spacing was 1.0 mm.

DWI parameters: TR was 3000 ms, TE was 59 ms, FOV was 350 mm×350 mm, matrix was 320×350, slice thickness was 4.5 mm, slice spacing was 1.0 mm and b values were 0 and 800 s/mm², respectively.

DCE-MRI examination: TR was 4.8 ms, TE was 2.4 ms, FOV was 350 mm×350 mm, matrix was 320×350, slice thickness was 2.0 mm, and slice spacing was 1.0 mm. A total of 6 phases of images were collected. In the first phase, the mask was used, and then the contrast agent gd-DTPA was rapidly injected with a high-pressure syringe at a dose of 0.2 mmol/kg and an injection rate of 2 mL/s.

MRI IMAGE Analysis

The data were analyzed by three radiologists with more than 5 years of experience in radiological diagnosis. DWI: After scanning, the original images were transferred to the workstation. The software was used to reconstruct the parameters of DWI and measure the data, and the early apparent diffusion coefficient (ADC) of the lesions was calculated. DCE-MRI: The obvious area of the lesion was regarded as the region of interest (ROI), and the timesignal in intensity curve (TIC) was drawn. early phase enhancement rate (EPER) and time to peak (TTP) were calculated. Two radiologists with more than 5 years of imaging diagnosis experience comprehensively analyzed the MRI images of all the included patients. If there was any disagreement, a unified conclusion was reached after discussion.

Detection of molecular biomarkers

Surgical biopsy specimens were fixed in 10% neutral formalin, routinely dehydrated, embedded in

paraffin, sectioned and immunohistochemical staining was performed by ABC method. The expression of estrogen receptor (ER) and progesterone receptor (progesterone receptor) in cancer tissues was observed under a light microscope. PR), human epidermal growth factor 2 (HER-2) and cell proliferation antigen marker (Ki-67). The results showed that ER and PR were positive: more than 25% of the cancer cells showed brown staining; HER-2 positive: more than 30% of the cancer cells showed brownish yellow staining; Ki-67 was positive: more than 10% of the cancer cells showed brownish yellow nuclear staining. Specifically, the immunohistochemistry staining used the Dako EnVision+ System-HRP (AEC) kit, produced by Agilent Technologies, with the company located in the United States. The ABC staining reagent was provided by Vector Laboratories, also based in the United States. Furthermore, other materials used for specimen fixation in 10% neutral buffered formalin, dehydration, and embedding were sourced from Sigma-Aldrich (part of Merck KGaA), a company based in Germany.

Statistical analysis

Statistic Package for Social Science (SPSS) 22.0 software (IBM, Armonk, NY, USA) was used to analyze the obtained data, and the measurement data were expressed as ($\pm s$) and analyzed by t test. Count data were expressed as examples or rates, and chi-square test was performed. $P < 0.05$ was considered statistically significant. The consistency of MRI and pathological diagnosis was compared by Kappa consistency test. Kappa value ≥ 0.7 indicated high consistency, Kappa value between 0.4 and 0.7 indicated medium consistency, and Kappa value < 0.4 indicated weak consistency.

RESULTS

A total of 120 patients with suspected breast lesions diagnosed in our hospital from January 2021 to October 2023 were enrolled. All patients were female, aged from 25 to 69 years, with an average age of 47.11 ± 11.06 years. There were 67 cases in the left breast and 53 cases in the right breast.

Diagnostic efficacy analysis of MRI for breast cancer

Among the 120 patients, 76 patients were diagnosed as breast cancer positive by pathological examination, and 80 patients were detected as breast cancer positive by MRI. The Kappa value of consistency analysis between MRI and pathological examination was 0.817, the sensitivity was 96.05%, the specificity was 84.09%, the accuracy rate was 91.67% and the positive predictive value was 91.25%. The negative predictive value was 92.50%. Refer to table 1. This emphasizes the significant value

of MRI as a non-invasive diagnostic tool in the early detection of breast cancer. Its high sensitivity means that MRI can effectively identify cases of breast cancer, while its high accuracy demonstrates its strong ability to differentiate between cancerous and non-cancerous lesions.

Table 1. Diagnostic efficacy analysis of MRI for breast cancer.

MRI	Pathological examination		Total
	Positive	Negative	
Positive	73	7	80
Negative	3	37	40
Total	76	44	120

Note: ER: Estrogen Receptor, PR: Progesterone Receptor.

MRI features of breast cancer patients

All 76 breast cancer patients had a single lesion. Tumor diameter: > 2 cm in 51 cases (67.11%), ≤ 2 cm in 25 cases (32.89%); Tumor morphology: round in 28 cases (36.84%), lobulated in 25 cases (32.89%), irregular in 23 cases (30.27%); Tumor margin: smooth in 26 cases (34.21%), burr in 33 cases (43.42%), not smooth in 17 cases (22.37%); The enhancement patterns were uniform in 40 cases (52.63%), uneven in 25 cases (32.89%) and circular in 11 cases (14.48%). TIC type: type I 6 cases (7.89%), type II 29 cases (38.16%), type III 41 cases (53.95%); EPER: (216.47 ± 34.56) %; TTP was (185.74 ± 36.44) s; The mean ADC value was $(1.13 \pm 0.25) \times 10^{-3} \text{ mm}^2/\text{s}$. A typical case is shown in figure 1. This section provides a detailed description of the MRI imaging characteristics of breast cancer patients, including tumor diameter, morphology, margins, and enhancement patterns. Through the statistical data of these features, we can see that MRI not only helps in diagnosing breast cancer but also provides important information about the tumor's biological characteristics. For instance, most tumors have a diameter greater than 2cm, and the majority of tumors display heterogeneous enhancement and irregular morphology. These characteristics may be associated with the tumor's aggressiveness and prognosis.

Expression of molecular biological markers in breast cancer patients

The immunohistochemical results of 76 cases of breast cancer tissues showed that 49 cases (64.47%) were ER positive and 27 cases (35.53%) were negative. 39 cases (51.32%) were PR positive and 37 cases (48.68%) were PR negative. 42 cases (55.26%) were HER-2 positive and 34 cases (44.74%) were HER-2 negative. Ki-67 was positive in 56 cases (73.68%) and negative in 20 cases (26.32%). A typical case is shown in figure 2. The findings of this section reveal the correlation between MRI imaging characteristics and molecular biomarkers of breast cancer, such as ER, PR, HER-2 and Ki-67. Specifically, the tumor diameter shows a positive correlation with the expression of ER, HER-2 and Ki-67. This may indicate that MRI imaging features can, to a certain extent, reflect the molecular biological characteristics

of the tumor, thereby providing a more personalized basis for clinical treatment.

Relationship between MRI imaging features and molecular biological markers in BC patients

The tumor diameter was correlated with the expression of ER, HER-2 and Ki-67 ($P < 0.05$), but not with the expression of PR ($P > 0.05$). Tumor morphology was not related to the expression of ER, PR, HER-2 and Ki-67 ($P < 0.05$). The tumor margin was related to the expression of ER and PR ($P < 0.05$), but not to the expression of PR and Ki-67. The

enhancement pattern was not related to the expression of ER, PR, HER-2 and Ki-67 ($P > 0.05$). TIC type was related to the expression of Ki-67 ($P < 0.05$), but not to the expression of ER, PR and HER-2 ($P > 0.05$). EPER was correlated with HER-2 expression ($P < 0.05$), but not with ER, PR and Ki-67 expression ($P > 0.05$). TTP was correlated with Ki-67 expression ($P < 0.05$), but not with ER, PR and HER-2 expression ($P > 0.05$). The ADC value was correlated with the expression of Ki-67 ($P < 0.05$), but not with the expression of ER, PR and HER-2 ($P > 0.05$). Refer to table 2.

Table 2. Relationship between MRI imaging features and molecular biological markers in breast cancer patients.

MRI imaging features	ER		χ^2/t	P	PR		χ^2/t	P
	Positive (n=49)	Negative (n=27)			Positive (n=39)	Negative (n=37)		
Diameter of tumor			3.921	0.048			2.399	0.121
>2 cm	29	22			23	28		
≤2 cm	20	5			16	9		
Morphology of tumor			6.399	0.041			9.187	0.010
Quasi-circular	21	7			8	20		
Lobulated	18	7			16	9		
Irregularity	10	13			15	8		
Margin of tumor			11.701	0.003			7.524	0.023
Smooth	10	16			8	18		
Rag	26	7			22	11		
Lenrodiscontinuity	13	4			9	8		
Schedule of Reinforcement			3.081	0.214			1.299	0.522
Uniform	29	11			23	17		
Mix	15	10			11	14		
Annular	5	6			5	6		
TIC type			0.120	0.942			0.202	0.904
I	4	2			3	3		
II	18	11			14	15		
III	27	14			22	19		
EPER (%)	217.95±35.87	213.78±32.18	0.503	0.617	218.89±37.37	213.92±31.60	0.624	0.534
TTP (s)	189.11±39.76	179.62±30.41	1.078	0.285	188.53±33.57	182.80±39.47	0.683	0.497
ADC Value ($10^{-3}/\text{mm}^2/\text{s}$)	1.15±0.27	1.09±0.21	0.999	0.321	1.15±0.24	1.11±0.26	0.697	0.488
MRI imaging features	HER-2		χ^2/t	P	Ki-67		χ^2/t	P
	Positive (n=42)	Negative (n=34)			Positive (n=56)	Negative (n=20)		
Diameter of tumor			14.719	<0.001			6.960	0.008
>2 cm	35	16			42	9		
≤2 cm	7	18			14	11		
Morphology of tumor			11.686	0.003			9.548	0.008
Quasi-circular	10	18			23	5		
Lobulated	15	10			14	11		
Irregularity	17	6			19	4		
Margin of tumor			0.555	0.758			2.316	0.314
Smooth	13	13			21	5		
Rag	19	14			22	11		
Lenrodiscontinuity	10	7			13	4		
Schedule of Reinforcement			0.095	0.954			0.066	0.968
Uniform	27	13			30	10		
Mix	12	13			18	7		
Annular	3	8			8	3		
TIC type			5.839	0.054			12.411	0.002
I	3	3			5	1		
II	12	17			16	13		
III	27	14			35	6		
EPER (%)	223.78±38.14	207.44±30.14	2.035	0.045	217.33±35.17	214.06±32.85	0.363	0.718
TTP (s)	191.46±37.87	178.67±34.67	1.520	0.133	191.66±37.17	169.16±34.40	2.368	0.021
ADC Value ($10^{-3}/\text{mm}^2/\text{s}$)	1.16±0.27	1.09±0.23	1.199	0.234	1.20±0.28	0.93±0.17	4.044	<0.001

Note: ER: Estrogen Receptor, PR: Progesterone Receptor, EPER: early phase enhancement rate, TTP: Time To Peak, ADC Value: Apparent Diffusion Coefficient, TIC type: Time-Intensity Curve.

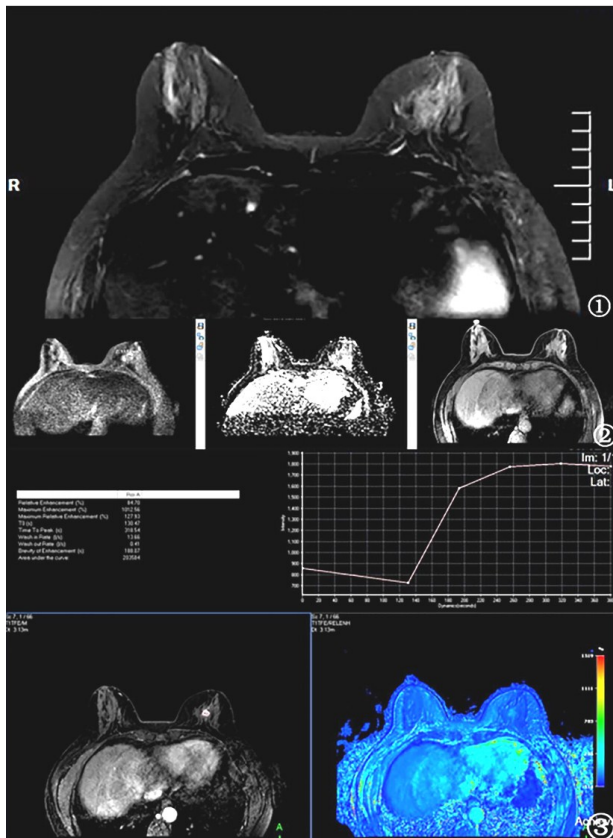


Figure 1. Figure 1 is Conventional MRI images, figure 2 is DWI image, figure 3 shows the DCE-MRI image.

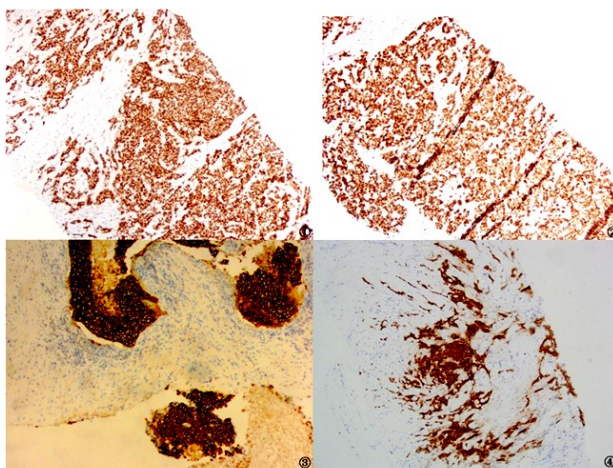


Figure 2. Immunohistochemical staining of breast cancer markers.

Note: Figure 1 is ER positive pathological picture, 200× magnification, figure 2 shows PR positive pathological picture, 200× magnification, figure 3 is the HER-2 positive pathological picture, 400× magnification, figure 4 shows the Ki-67 positive pathological picture, 400× magnification.

DISCUSSION

The etiology of breast cancer is still unclear. So far, the exact cause of breast cancer has not been found, but many high-risk factors related to the incidence of breast cancer have been found, such as a

variety of endocrine hormones are directly related to the incidence of breast cancer, and genetic factors are also high-risk factors of breast cancer (6). The symptoms of early breast cancer are not obvious, while advanced breast cancer can occur distant metastasis of cancer cells and multiple organ lesions, which directly threaten the life of patients. Therefore, early diagnosis of breast cancer is the key to improve the survival rate of patients. In recent years, MRI plays an important role in early diagnosis, surgical planning and efficacy evaluation of breast cancer due to its good soft tissue and spatial resolution. Studies (7) have confirmed that compared with digital mammography, tomography, ultrasound and other examination methods, MRI has a higher kappa value of 0.828 in the diagnosis of breast cancer. The kappa value of MRI in the diagnosis of breast cancer in this study was 0.817, which was similar to the above reports, further confirming the advantage of MRI in the diagnosis of breast cancer. However, the cost of MRI is high, and some patients with metal materials such as cardiac pacemakers are not suitable for MRI examination. Therefore, MRI can be used to assist the diagnosis of highly suspected breast cancer patients to obtain more information about the lesions.

Breast MRI is a new medical imaging technology that uses the principle of nuclear magnetic resonance to act on breast tissue through a strong magnetic field and generate magnetic resonance signals for multiple acquisition to form images for diagnosis. Its imaging is clearer, the diagnosis is more accurate, the lesions can be all-round, multi-angle intuitive and three-dimensional display and the resolution is high for small lesions. It is mainly aimed at the display of the overall state of the breast and the differentiation of benign and malignant breast space-occupying lesions (8). DWI is the only non-invasive method that can detect the diffusion characteristics of water molecules in vivo, which can detect the inflammatory changes of breast tissue in patients at early stage, and quantitatively evaluate the progression of the disease by measuring the ADC value (9). DCE-MRI is a new type of magnetic resonance examination technology, mainly through intravenous injection of an appropriate amount of water-soluble contrast agent, shortening the T1 time of protons around the nodal contrast agent, resulting in early enhancement kinetics change imaging measures, which can indirectly reflect human blood perfusion and vascular sclerosis (10). Molecular biological diagnostic techniques have been widely used in the clinical diagnosis, efficacy evaluation and prognosis of a variety of malignant tumors. If a breast nodule or mass is found in the body by imaging examination, the nature of the nodule or mass can be determined by histopathological examination (11-13). The results of this study found that the tumor diameter was related to the expression of ER, HER-2 and Ki-67 in breast cancer patients, the tumor morphology was related

to the expression of ER, PR, HER-2 and Ki-67, the tumor margin was related to the expression of ER and PR, the TIC type was related to the expression of Ki-67, and EPER was related to the expression of HER-2. TTP was related to Ki-67 expression, and ADC value was related to Ki-67 expression. Previous studies ⁽¹⁴⁻¹⁶⁾ have reported that tumor diameter, tumor morphology and tumor margin are closely related to the occurrence and development of breast cancer. TIC classification can effectively reflect the hemodynamic information of cancer tissue. Previous studies ⁽¹⁷⁻¹⁹⁾ reported that MR Dynamic enhanced TIC curve combined with ADC had great clinical value in differentiating benign and malignant breast lesions, which could greatly improve the diagnostic accuracy of breast cancer. ER, PR, HER-2 and Ki-67 are commonly used clinical tumor molecular biological markers. A number of studies ⁽²⁰⁾ have confirmed that the expression of ER, PR, HER-2 and Ki-67 is significantly related to the prognosis and survival of breast cancer patients. In comparing existing literature, this study found a significant correlation between DCE-MRI and DWI imaging features and molecular biomarkers of breast cancer, in contrast to previous reports. Combined with the above reports, this study suggests that the imaging features of DCE-MRI and DWI have a certain correlation with molecular biological markers. Patients with larger tumor diameter, spicled tumor edge and uneven tumor enhancement may have higher cancer cell invasion, faster disease progression, and poor prognosis.

In conclusion, DCE-MRI combined with DWI has a high diagnostic efficiency for breast cancer and its imaging features are correlated with molecular biological markers, and further imaging methods can be used to indirectly reflect the biological behavior of breast cancer. This study also has limitations. For example, it is a single-center study and the sample size is small, so it still needs to be further expanded for further research.

To conclude, this discussion highlights the intricate relationship between advanced imaging techniques, such as DCE-MRI and DWI, and the molecular biology of breast cancer, illustrating how these tools not only enhance diagnostic accuracy but also provide insights into the disease's progression and prognosis. The findings underscore the importance of integrating imaging features with molecular markers to develop a more nuanced understanding of breast cancer. However, it is important to acknowledge the limitations of this study, including its single-center design and small sample size, which necessitate further research with larger, multi-center cohorts to validate and extend these findings. Through continued investigation and technological advancements, we can hope to improve early detection, tailor treatments more effectively, and ultimately enhance outcomes for patients with

breast cancer.

ACKNOWLEDGMENT

This work was supported by the First Affiliated Hospital of Bengbu Medical University (Project number: 2021JC02).

Conflict of interests: The authors declare that they have no conflict of interests.

REFERENCES

1. Jang H, Baek JG, Kim W and Sohn, JH (2021) Assessment of intensity modulated radiation therapy in left breast cancer including regional nodes without the internal mammary node: secondary cancer risks on thyroid and stomach. *International Journal of Radiation Research*, **19**(4): 921-928.
2. Ramtohlul T, Djerroudi L, Lissavali E, Nhy C, Redon L, Ikni L, Djelouah M, Journo G, Menet E, Cabel L, Malhaire C, Tardivon A (2023) Multiparametric MRI and Radiomics for the Prediction of HER2-Zero, -Low, and -Positive Breast Cancers. *Radiology*, **308**(2): e222646. doi: 10.1148/radiol.222646. PMID: 37526540.
3. Zhao X, Bai JW, Guo Q, Ren K, Zhang GJ (2023) Clinical applications of deep learning in breast MRI. *Biochim Biophys Acta Rev Cancer*, **1878**(2): 188864. doi: 10.1016/j.bbcan.2023.188864. Epub 2023 Feb 21. PMID: 36822377.
4. Saleem TH, Rizk MA, Abdelhazef NF, Sabra A and Radwan E (2024) Upregulation of BRCA1 and 2 protein expression is associated with dysregulation in amino acids profiles in breast cancer. *Molecular Biology Reports*, **51**(1): 50.
5. Siqueira PB, de Sousa RM and de Amorim I, et al. (2024) The APE1/REF-1 and the hallmarks of cancer. *Molecular Biology Reports*, **51**(1): 47.
6. Adesoye T, Schumacher JR, Neuman HB, Edge S, McKellar D, Winchester DP, Francescatti AB, Greenberg CC (2018) Alliance ACS-CRP CCDD breast cancer surveillance working group. Use of breast imaging after treatment for locoregional breast cancer (AFT-01). *Ann Surg Oncol*, **25**(6): 1502-1511. doi: 10.1245/s10434-018-6359-z. Epub 2018 Feb 15. PMID: 29450753; PMCID: PMC6925599.
7. Henderson LM, Hubbard RA, Zhu W, Weiss J, Wernli KJ, Goodrich ME, Kerlikowske K, DeMartini W, Ozanne EM, Onega T (2018) Pre-operative breast magnetic resonance imaging use by breast density and family history of breast cancer. *J Womens Health (Larchmt)*, **27**(8): 987-993. doi: 10.1089/jwh.2017.6428. Epub 2018 Jan 15. PMID: 29334616; PMCID: PMC6104247.
8. Sella T, Dowton AA, Meyer ME, Ruddy KJ, Yeh ED, Barry WT, Partridge AH (2020) The utility of magnetic resonance imaging in early-stage breast cancer survivors-An institutional experience and literature review. *Breast J*, **26**(9): 1673-1679. doi: 10.1111/tbj.13997. Epub 2020 Aug 4. PMID: 32754998.
9. Rakıcı SY and Eren M (2023) Intensity-modulated radiation therapy (IMRT) with couch rotation in right unilateral breast cancer.
10. Yu Y, He Z, Ouyang J, Tan Y, Chen Y, Gu Y, Mao L, Ren W, Wang J, Lin L, Wu Z, Liu J, Ou Q, Hu Q, Li A, Chen K, Li C, Lu N, Li X, Su F, Liu Q, Xie C, Yao H (2021) Magnetic resonance imaging radiomics predicts preoperative axillary lymph node metastasis to support surgical decisions and is associated with tumor microenvironment in invasive breast cancer: A machine learning, multicenter study. *EBio-Medicine*, **69**: 103460. doi: 10.1016/j.ebiom.2021.103460. Epub 2021 Jul 4. PMID: 34233259; PMCID: PMC8261009.
11. Sarli A, Mozdarani H, Rakhshani N, Mozdarani S (2019) Relationship study of the verified human epidermal growth factor receptor 2 amplification with other tumor markers and clinicohistopathological characteristics in patients with invasive breast cancer, using chromogenic in situ hybridization. *Cell Journal (Yakhteh)*, **21**(3): 322.
12. Zhao Y, Yu Z and Song Y, et al. (2024) The regulatory network of CREB3L1 and its roles in physiological and pathological conditions. *International Journal of Medical Sciences*, **21**(1): 123-136.
13. Lam DL, Houssami N, Lee JM (2017) Imaging surveillance after primary breast cancer treatment. *Ajr Am J Roentgenol*, **208**(3): 676-686. doi: 10.2214/AJR.16.16300. Epub 2017 Jan 11. PMID: 28075622; PMCID: PMC5458742.
14. Yamaguchi H, Chang LC and Chang OS, et al. (2024) MRCK as a

- potential target for claudin-low subtype of breast cancer. *International Journal of Biological Sciences*, **20(1)**: 1-14.
15. Witowski J, Heacock L, Reig B, Kang SK, Lewin A, Pysarenko K, Patel S, Samreen N, Rudnicki W, Łuczyńska E, Popiela T, Moy L, Geras KJ (2022) Improving breast cancer diagnostics with deep learning for MRI. *Sci Transl Med*, **14(664)**: eabo4802. doi: 10.1126/scitranslmed. abo4802. Epub 2022 Sep 28. PMID: 36170446; PMCID: PMC10323699.
 16. Goh T, Dao K, Rives AF, Fishman MDC, Slanetz PJ (2021) Systemic diseases affecting the breast: Imaging, diagnosis, and management. *Clin Imaging*, **77**: 76-85. doi: 10.1016/j.clinimag.2021.02.021. Epub 2021 Feb 24. PMID: 33652268.
 17. Ab Mumin N, Ramli Hamid MT, Wong JHD, Rahmat K, Ng KH (2022) Magnetic resonance imaging phenotypes of breast cancer molecular subtypes: A systematic review. *Acad Radiol*, **29 Suppl 1**: S89-S106. doi: 10.1016/j.acra.2021.07.017. Epub 2021 Sep 2. PMID: 34481705.
 18. Whelan TJ, Fyles A, Parpia S, Nielsen T and Levine MN (2023) LUMINA: Using molecular biomarkers to guide decision making for breast radiotherapy. *Radiotherapy and Oncology*, **190**: 110074.
 19. Seyfettin A, Dede I, Hakverdi S, Düzel Asig B, Temiz M, Karazincir S (2022) MR imaging properties of breast cancer molecular subtypes. *Eur Rev Med Pharmacol Sci*, **26(11)**: 3840-3848. doi: 10.26355/eurrev_202206_28951. PMID: 35731053.
 20. Rachetta E, Osano S, Astegiano F, Martincich L (2016) Breast cancer surveillance. *Minerva Ginecol*, **68(5)**: 509-516. Epub 2016 Feb 29. PMID: 26924173.

