

Value of color Doppler ultrasonography in diagnosis of carotid atherosclerotic plaque in cerebral infarction patients

L. Guo¹, X. Guo², R. Kong^{3*}

¹Department of Neurology, Yantaishan Hospital, Yantai City, Yantai, Shandong, China

²Department of Gerontology, Yantaishan Hospital, Yantai City, Yantai, Shandong, China

³Department of Functional Neurology, Wuxi People's Hospital, Wuxi, Jiangsu, China

ABSTRACT

► Short Report

*Corresponding author:

Rong Kong, M.D.,

E-mail: kkrr83@163.com

Received: November 2023

Final revised: March 2024

Accepted: March 2024

Int. J. Radiat. Res., January 2025;
23(1): 245-248

DOI: 10.61186/ijrr.23.1.245

Keywords: Cerebral infarction, carotid stenosis, color Doppler ultrasonography.

Background: To assess the value of color Doppler ultrasonography (CDUS) in diagnosing carotid atherosclerotic plaque (CAP) in cerebral infarction (CI) patients.

Materials and Methods: Totally 100 CI patients in our hospital from March 2021 to March 2023 were included in the study group (SG), and another 98 patients who received physical examination at the same time were included in the control group (CG). CDUS was performed to determine the type, distribution and total detection rate of carotid atherosclerotic plaque, and to evaluate carotid blood flow parameters, carotid intima-media thickness (IMT) and stenosis degree in the two groups. **Results:** No significant difference of plaque in the proportion of external carotid artery (ECA), internal carotid artery (ICA), common carotid artery (CCA) and carotid artery bifurcation between the two groups ($P>0.05$). Relative to the CG, the detection rate of each type of carotid atherosclerotic plaque in the SG was significantly higher ($P=0.03$ and $P<0.001$), peak systolic flow velocity (PSV), minimum diastolic flow velocity (EDV), and resistance index (RI) of carotid blood flow were lower, and IMT was higher in the SG ($P<0.05$), and the proportion of mild, moderate and severe carotid artery stenosis in the SG were higher ($P<0.01$ and $P<0.001$). **Conclusion:** CDUS can detect the distribution and quantity of plaques, determine the type and stability of plaques, and assess the carotid blood flow parameters and stenosis, which is valuable for the diagnosis of CAP in CI, and guides the formulation of clinical treatment plan.

INTRODUCTION

Cerebral infarction is caused by a variety of factors related to regional blood supply obstruction of brain tissue, leading to ischemic hypoxic lesion necrosis. It mostly occurs in middle-aged and elderly people, often complicated with atherosclerosis, hyperlipidemia, hypertension, and diabetes⁽¹⁾. The early symptoms such as dizziness, temporary limb numbness, weakness or transient ischemic attack are often ignored due to the short duration and mild severity^(2, 3). Atherosclerotic plaque is the accumulation of extracellular lipid particles, foam cells, and debris deposited in the intima of the arterial wall as a lipid or necrotic core surrounded by the fibrous cap⁽⁴⁾. Its development is considered as a necessary step for atherosclerosis, which is closely linked to the occurrence of CI in elderly people^(5, 6). Moreover, the development of atherosclerotic plaque usually takes a long period, while the onset of cerebral infarction is urgent, which calls for effective diagnosis in clinic⁽⁷⁾. The location table of carotid artery is easy to observe, and its lesions are earlier than coronary artery and cerebral artery, thus carotid artery is regarded as a window to detect systemic arteriosclerosis⁽⁸⁾. Currently, computed tomography

(CT), digital subtraction angiography, magnetic resonance angiography, and other methods are effective for the diagnosis and evaluating the anatomical changes of carotid atherosclerotic plaque in CI^(9, 10). Among them, color Doppler ultrasound (CDUS) is widely used in the diagnosis of carotid atherosclerotic plaques in CI due to its simple operation, repeated detection, non-invasiveness, and effective detection of plaque distribution, size, and location⁽¹¹⁾. It is effective with high sensitivity and specificity in detecting artery plaque and stenosis, and has shown predictive value in the diagnosis of carotid atherosclerosis-related diseases⁽¹²⁾. In view of this, this study investigated the application value of CDUS in the diagnosis of carotid atherosclerotic plaque in cerebral infarction patients. The findings of this study possibly provide clues for the diagnosis and formulation of treatment plans for CI patients.

MATERIALS AND METHODS

General data

Totally 100 cerebral infarction patients visiting our hospital from March 2021 to March 2023 were included in the study group (SG), and another 98

patients who received physical examination at the same time in our hospital were selected into the control group (CG). The demographic information of patients was shown in table 1. There was no statistical difference in the basic data of patients between groups ($P < 0.05$).

Inclusion criteria: (1) met the diagnostic criteria for carotid atherosclerotic plaque with cerebral infarction; (2) CI diagnosis was confirmed through magnetic resonance imaging or computed tomography of the head; (3) conscious, communicated without barriers; (4) informed of the study contents, and provided the informed consent letter.

Exclusion criteria: (1) with diabetes, hypertension, cognitive impairment, heart, liver and kidney dysfunction; (2) with malignant tumor; (3) poor compliance; (4) lack of clinical data.

Table 1. Basic characteristics of cerebral infarction patients.

| Characteristics | Control group (n=98) | Study group (n=100) | P value |
|--------------------------|----------------------|---------------------|---------|
| Gender | | | 0.89 |
| Male | 50 | 52 | |
| Female | 48 | 48 | |
| Age (years) | 61.21±6.12 | 61.25±6.18 | 0.96 |
| Course of disease (days) | 3.91±2.86 | - | - |
| BMI (kg/m ²) | 22.7±3.1 | 23.5±2.9 | 0.06 |

Methods

CDUS was performed using the IU-22 color Doppler ultrasonography instrument (Philips Healthcare, Amsterdam, The Netherlands) with probe frequency at 5 ~ 12 MHz. The subjects were told to take a horizontal position, shift the head to the opposite side of the examination area by 45°, relax the neck and keep it straight, and fully expose the neck on the examined side. The ECA, ICA, bifurcation of carotid artery, proximal carotid artery, distal carotid artery and middle carotid artery were examined respectively. The blood flow of the study subjects could be clearly observed through two-dimensional acoustic image, and the observed plaque distribution, plaque shape and size, and plaque type were carefully recorded.

Observation indicators

(1) The plaque sites including ECA, ICA, CCA and carotid artery bifurcation and detection rate were recorded and compared.

(2) The carotid atherosclerotic plaque type and detection rate according to ultrasonic echo characteristics: (1) Soft plaque: mixed echo, plaque protruding from the vascular cavity. (2) Ulcer plaque: low echo, irregular plaque. (3) Flat plaque: overall thickening, a few protrusions, increased blood vessel wall thickness. (4) Hard plaque: strong echo, accompanied by sound shadow. Flat plaque and hard plaque were collectively referred to as stable plaques.

(3) Carotid blood flow parameters including PSV, EDV, RI, and carotid IMT were analyzed in the two

groups. Normal: IMT < 1.0 mm; Thickening: 1.1 mm ≤ IMT < 1.2 mm; Atherosclerotic plaque formation: IMT ≥ 1.2 mm.

(4) The degree of carotid artery stenosis was as follows: mild carotid artery stenosis: stenosis rate < 30%; Moderate carotid artery stenosis: 30% ~ 69%; Carotid artery severe stenosis: 70% ~ 90%.

Statistical analysis

SPSS 21.0 statistical software (SPSS Inc., Chicago, USA) was adopted for data processing and analyses. Measurement data are shown as the mean ± standard deviation, and comparison between groups was subject to the t-test. The statistical data are expressed as rate (%) and Chi-Squared test was used for comparison. $P < 0.05$ indicated statistical significance.

RESULTS

Plaque sites in CI patients and control individuals

In the CG, 5 participants (5.10%) showed plaques at ECA, 10 participants (10.20%) showed plaques at ICA, 21 participants (21.43%) showed plaques at CCA, and 52 patients (53.06%) showed plaques at carotid artery bifurcation. In the SG, 6 CI patients (6.00%) showed plaques at ECA, 12 CI patients (12.00%) showed plaques at ICA, 25 patients (25%) showed plaques at CCA, and 58 patients (58.00%) showed plaques at carotid artery bifurcation. Most of the plaques occurred at the carotid artery bifurcation for both CI patients and control individuals, and no significant difference of plaque site was found between groups ($P > 0.05$). As shown in figure 1, the CI patient showed multiple plaque at the ECA and ICA for bilateral carotid, and stenosis was observed at the left ECA (50-69%) (figure 1A). For the healthy control individual, the blood flow in the bilateral carotids showed no obvious abnormality in the CDUS examination (figure 1B).

Table 2. Plaque sites in CI patients in CI patients and control individuals.

| Groups | N | ECA | ICA | CCA | Carotid artery bifurcation |
|---------------|-----|-----------|-------------|-------------|----------------------------|
| Control group | 98 | 5 (5.10%) | 10 (10.20%) | 21 (21.43%) | 52 (53.06%) |
| Study group | 100 | 6 (6.00%) | 12 (12.00%) | 25 (25.00%) | 58 (58.00%) |
| χ^2 | | 0.08 | 0.16 | 0.35 | 0.49 |
| P | | 0.78 | 0.69 | 0.55 | 0.48 |

CI, cerebral infarction; N, number; ECA, external carotid artery; ICA, internal carotid artery; CCA, common carotid artery.

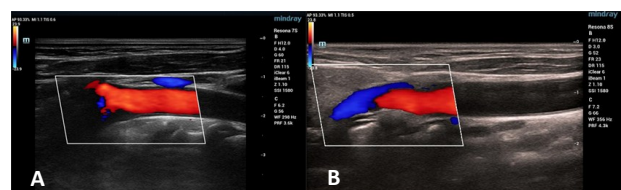


Figure 1. (A) The CDUS images of a CI patient. (B) The CDUS images of a healthy control individual.

Type of carotid plaque and total detection rate in CI patients and control individuals

In the CG, 8 participants (8.16%) showed soft plaques, 12 participants (12.24%) showed flat plaque, and 5 participants (5.10%) showed hard plaque, and the total incidence rate of carotid atherosclerotic plaque was 25.51%. However, the detection rate of each type of carotid atherosclerotic plaque in the SG was significantly higher relative to the CG ($P=0.03$ and $P<0.001$). Totally 26 patients (26%) were detected with soft plaque, 5 patients (5%) showed ulcer plaque, 33 patients (33%) showed flat plaque, and 24 patients (24%) showed hard plaque, and the total incidence rate of carotid atherosclerotic plaque was 88% (table 3).

Table 3. Type and incidence of carotid atherosclerotic plaque in CI patients and control individuals

| Groups | N | Soft plaque | Ulcer plaque | Flat plaque | Hard plaque | Total incidence rate |
|---------------|-----|-------------|--------------|-------------|-------------|----------------------|
| Control group | 98 | 8 (8.16%) | 0 (0.00%) | 12 (12.24%) | 5 (5.10%) | 25 (25.51) |
| Study group | 100 | 26 (26.00%) | 5 (5.00%) | 33 (33.00%) | 24 (24.00%) | 88 (88.00) |
| χ^2 | | 11.07 | 5.03 | 12.14 | 14.14 | 78.89 |
| P | | <0.001 | 0.03 | <0.001 | <0.001 | <0.001 |

CI, cerebral infarction; N, number.

Carotid blood flow parameters and IMT in CI patients and control individuals

The carotid blood flow parameters including PSV, EDV and RI and carotid IMT in the CG and SG were also detected. The results revealed that PSV, EDV and RI of carotid blood flow in the SG were lower, while IMT in the SG was higher compared with the CG ($P<0.05$, figure 2A-D).

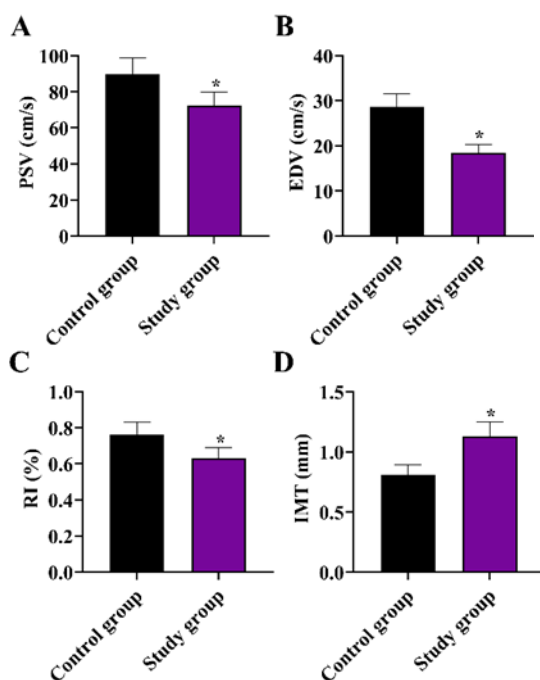


Figure 2. Carotid blood flow parameters and IMT in CI patients and control individuals. (A) PSV, (B) EDV, (C) RI, (D) IMT.

* $P<0.05$.

Degree of carotid artery stenosis in CI patients and control individuals

In the CG, 12 participants (12.24%) showed mild stenosis, 7 participants (7.14%) showed moderate stenosis and 2 participants (2.04%) showed severe stenosis. In the SG, 44 patients (44%) showed mild stenosis, 25 patients (25%) showed moderate stenosis and 13 patients (13%) showed severe stenosis. Additionally, the proportion of carotid artery stenosis at all degree in the SG were higher relative to the CG ($P<0.01$ and $P<0.001$) (table 4).

Table 4. Degree of carotid artery stenosis in CI patients in the control or study group.

| Groups | N | Mild stenosis | Moderate stenosis | Severe stenosis |
|---------------|-----|---------------|-------------------|-----------------|
| Control group | 98 | 12 | 7 | 2 |
| Study group | 100 | 44 | 25 | 13 |
| χ^2 | | 24.61 | 11.85 | 8.49 |
| P | | <0.001 | <0.001 | <0.01 |

CI, cerebral infarction; N, number.

DISCUSSION

The occurrence of cerebral infarction is related to carotid atherosclerosis, which will lead to cerebrovascular stenosis or occlusion, resulting in insufficient blood and oxygen supply of brain arteries. Release of carotid atherosclerotic plaque can cause cerebral artery embolism in patients, thus inducing cerebral infarction disease. The formation and progression of carotid atherosclerosis usually involve three stages, including the damage of vascular endothelial function, thickening of arterial intima and the formation of plaque⁽¹³⁾. When the plaque ruptures, it will burst into the lumen, and result in the lipid and collagen exposure, platelet activation, and subsequent thrombosis, ulceration or bleeding, and finally the formation of cerebral infarction. Therefore, early diagnosis and detection of carotid atherosclerosis is very important to improve the clinical prognosis of patients⁽¹⁴⁾.

Currently, imaging techniques are the main methods for the diagnosis of carotid atherosclerotic plaques in cerebral infarction. CT, MRI and angiography are commonly used imaging modalities, and the application of these kinds of imaging technologies can directly observe the unknown occurrence, type and quantity of carotid atherosclerotic plaque in patients, and the clinical application effects are ideal, but their operations are complicated, and the costs are high, and the application is limited⁽¹⁵⁾. On the contrary, the color Doppler ultrasound with simple operation, low cost, repeatable examination, is commonly applied in the clinical diagnosis of many diseases⁽¹⁶⁾. In our study, the CDUS results displayed no significant difference of plaque distribution in the proportion of ECA, ICA, CCA and carotid artery bifurcation between SG and

CG. The detection rate of each type of carotid atherosclerotic plaques in the SG was higher relative to the CG ($P < 0.05$, table 2), which was consistent with a previous work proposed by Jiang *et al.* (17). PSV, EDV and RI of carotid blood flow in the SG were at lower level relative to CG, while IMT in the SG was higher relative to the CG (Figure 2). The incidence of all types of carotid atherosclerotic plaque was also significantly higher in SG compared with the CG (table 3), which was consistent with the previous findings that the incidence of carotid atherosclerotic plaque stability is closely associated with the cerebral infarction (18, 19). The proportion of mild, moderate and severe carotid artery stenosis in the SG were higher than those in the CG (table 4). CDUS is effective in judging the degree of artery stenosis and blood flow in patients, and can determine the type, distribution, and quantity of plaque based on ultrasound images in time, and is efficient to diagnose mild and moderate carotid artery stenosis, which was in line with the previous findings (20). Due to the high risk of artifacts in the detection of calcified plaque, the inspection accuracy will decrease, but color Doppler ultrasound can effectively avoid the adverse impact of artifacts on the inspection results, ensuring the effectiveness of the inspection.

In conclusion, for the diagnosis of carotid atherosclerotic plaques in cerebral infarction, the color Doppler ultrasound technology can detect the distribution and quantity of plaques, determine the plaque type and stability, and assess the carotid blood flow parameters and stenosis, showing guiding significance for the formulation of clinical treatment plan, and is valuable for widespread application.

ACKNOWLEDGMENTS

Not applicable.

Funding

Not applicable.

Conflicts of interests: The authors have no conflicts of interest to declare.

Ethical consideration: This study was approved by the Ethics Committee of Yantaishan Hospital (approval number: 2020011, 12 March, 2020).

Author contribution: L.G. and R.K. conceived and designed the study. L.G. and X.G. collected the data and conducted the data analysis. L.G. wrote the original draft, and X.G. and R.K. reviewed and revised the manuscript. All authors read and approved the final version of the manuscript.

REFERENCES

- Zhao, Y, Zhang X, Chen X, *et al.* (2022) Neuronal injuries in cerebral infarction and ischemic stroke: From mechanisms to treatment. *Int J Mol Med*, **49**(2).
- Saia V and Pantoni L (2009) Progressive stroke in pontine infarction. *Acta Neurol Scand*, **120**(4): 213-5.
- Takase KI (2020) Cardiogenic cerebral infarction in the parietal lobe predicts the development of post-stroke epilepsy. *Seizure*, **80**: 196-200.
- Vergallo R and Crea F (2020) Atherosclerotic plaque healing. *N Engl J Med*, **383**(9): 846-857.
- Xu M, He XY, Huang P (2020) The Relationship between the Mean Platelet Volume and Carotid Atherosclerosis and Prognosis in Patients with Acute Cerebral Infarction. *Biomed Res Int*, **2020**: 6685740.
- Ahmadi A, Argulian E, Leipsic J, *et al.* (2019) From Subclinical Atherosclerosis to Plaque Progression and Acute Coronary Events: JACC State-of-the-Art Review. *J Am Coll Cardiol*, **74**(12): 1608-1617.
- Arboix A and Martí-Vilalta JL (2009) Lacunar stroke. *Expert Rev Neurother*, **9**(2): 179-96.
- Ni T, Fu Y, Zhou W, *et al.* (2020) Carotid plaques and neurological impairment in patients with acute cerebral infarction. *PLoS One*, **15**(1): e0226961.
- Yuan C (2008) Carotid atherosclerosis and magnetic resonance imaging. *JACC Cardiovasc Imaging*, **1**(1): 58-60.
- Manrique-Zegarra M, García-Pastor A, Castro-Reyes E, *et al.* (2022) CT angiography for diagnosis of carotid near-occlusion: a digital subtraction angiography validation study. *Neuroradiology*, **64**(9): 1729-1735.
- Grant EG, Benson CB, Moneta GL, *et al.* (2003) Carotid artery stenosis: gray-scale and Doppler US diagnosis--Society of radiologists in ultrasound consensus conference. *Radiology*, **229**(2): 340-6.
- Caiati C, Lepera ME, Pollice P, *et al.* (2020) A new noninvasive method for assessing mild coronary atherosclerosis: transthoracic convergent color Doppler after heart rate reduction. Validation vs. intracoronary ultrasound. *Coron Artery Dis*, **31**(6): 500-511.
- Song T and Chen WD (2021) Berberine inhibited carotid atherosclerosis through PI3K/AKT/mTOR signaling pathway. *Bioengineering*, **12**(1): 8135-8146.
- Jiang C, Zhang J, Zhu J, *et al.* (2021) Association between coexisting intracranial artery and extracranial carotid artery atherosclerotic diseases and ipsilateral cerebral infarction: a Chinese Atherosclerosis Risk Evaluation (CARE-II) study. *Stroke Vasc Neurol*, **6**(4): 595-602.
- Brinjikji W, Huston J 3rd, Rabinstein AA, *et al.* (2016) Contemporary carotid imaging: from degree of stenosis to plaque vulnerability. *J Neurosurg*, **124**(1): 27-42.
- Murray CSG, Nahar T, Kalashyan H, *et al.* (2018) Ultrasound assessment of carotid arteries: Current concepts, methodologies, diagnostic criteria, and technological advancements. *Echocardiography*, **35**(12): 2079-2091.
- Jiang L and Zhao Y (2017) The value of color Doppler ultrasound in the diagnosis of lower extremity vascular disease in type 2 diabetes and an analysis of related factors. *Minerva Endocrinol*, **42**(3): 223-227.
- Chen L, Yang Q, Ding R, *et al.* (2018) Carotid thickness and atherosclerotic plaque stability, serum inflammation, serum MMP-2 and MMP-9 were associated with acute cerebral infarction. *Exp Ther Med*, **16**(6): 5253-5257.
- Wang J, Wang L, Shen Y, *et al.* (2022) Relationship between carotid artery angle and plaque morphology in acute cerebral infarction patients. *Neurologist*, **27**(5): 240-244.
- Macharzina RR, Kocher S, Messé SR, *et al.* (2018) 4-Dimensionally guided 3-dimensional color-Doppler ultrasonography quantifies carotid artery stenosis with high reproducibility and accuracy. *JACC Cardiovasc Imaging*, **11**(3): 386-396.