

Task-based fMRI study of activation in the brain network: A seed-based functional connectivity analysis

M. Chen^{1*}, Y. Chen², X. Wang¹, X. Ye¹, Z. Huang³, W. Wu⁴

¹Affiliated Hospital of Hangzhou Normal University, Hangzhou, China

²Zhejiang University, School of Medicine, Hangzhou, China

³Affiliated Mental Health Center, Zhejiang University, School of Medicine, Hangzhou, China

⁴Hangzhou Normal University, Hangzhou, China

ABSTRACT

► Original article

*Corresponding author:

Meiyuan Chen, M.D.,

E-mail: evonne_myi@163.com

Received: April 2024

Final revised: June 2024

Accepted: July 2024

Int. J. Radiat. Res., April 2025;
23(2): 371-378

DOI: 10.61186/ijrr.23.2.316

Keywords: Functional magnetic resonance imaging (fMRI), Brain activation, seed-based functional connectivity, therapeutic targets.

Background: Task-based functional magnetic resonance imaging (fMRI) is an effective method for noninvasively studying brain activity. We aim to find representative brain areas of the swallowing movement and compare the functional connectivity differences in these areas. **Materials and Methods:** A total of 23 participants were recruited to undergo task-based fMRI scans. Subject-level statistical analysis and group-level activation analysis were conducted using SPM12. Seed-based Functional Connectivity (FC) analyses were conducted to construct FC in brain level. We used two-sample t-test to identify distinctive FC patterns in various seeds. The relationship between FC values and swallowing frequency was also explored. **Results:** In experiment I, group-level activation patterns were observed in 30-second saliva swallowing trial task, but not in 18s-on task. Two sample t-tests showed that the seed located in right pericentral area (Seed3) had significantly more intensive FC than that located in cingulum (Seed5) with left postcentral gyrus, the seed located in left pericentral area (Seed4) had significantly more intensive FC than those located in cerebellum (Seed1,2) or in Seed5 with right postcentral gyrus, Seed5 had significantly more intensive FC than Seed1,2,4 with right middle frontal gyrus, right superior frontal gyrus and left supplementary motor area separately. No significant positive or negative correlations between swallowing frequency and seed-based FC values were found. **Conclusions:** Saliva swallowing trial task with self-paced rhythm in sufficient time can activate swallowing-related brain regions effectively. The activation peaks in bilateral pericentral area are representative in swallowing process and could be new therapeutic targets for poststroke dysphagia instead of traditional route.

INTRODUCTION

After a stroke, dysphagia is a significant risk factor for pneumonia. Additionally, it has been linked to a longer hospital stay, higher death rates, and negative long-term results^(1, 2). In recent years, growing clinical studies and reviews have shown that repeated Transcranial Magnetic Stimulation (rTMS) can be a new therapeutic tool for the rehabilitation of dysphagia after stroke. A thorough evaluation and meta-analysis of rTMS's effectiveness for the rehabilitation of dysphagia following a stroke revealed that it outperforms traditional training⁽³⁾. Numerous studies on the use of rTMS to treat post-stroke dysphagia shown an improvement in swallowing function when viewed under videofluoroscopy⁽⁴⁻⁸⁾. The swallow hotspot was the stimulation target in the vast majority of these rTMS therapy investigations. The stimulation site is roughly determined by previous studies or by locating the hotspot area of the swallowing muscle, performed mainly in the motor cortex area of the pharynx

(ipsilateral, contralateral, or bilateral hemisphere of the pharynx)^(4-6, 8-10) or cerebellum⁽¹¹⁻¹⁶⁾. Although most of them showed improvement in swallowing function, it has never been studied which stimulation site is better.

A potent method for noninvasively examining brain function is functional magnetic resonance imaging (fMRI), which recognizes variations in the blood oxygen level-dependent signal (BOLD) as an indirect measure of neuronal activity⁽¹⁷⁾. The quick advancement of neuroimaging technology has made it possible to do task-based fMRI, which can pinpoint the precise brain areas that are active during a certain task. Previous studies using fMRI to assess areas of cerebral cortical activation during swallowing have shown that fMRI is a useful imaging modality for investigating changes in neuronal activity in the bilateral hemispheres during swallowing⁽¹⁸⁾. Therefore, we attempted to use fMRI scans to determine the therapeutic stimulation site of poststroke dysphagia based on swallowing task rather than the traditional route described above,

which has never been studied.

It takes dynamic neuronal coordination at both the cortex and subcortical levels to carry out the intricate behavior of swallowing. Some research looked at the impact of consuming saliva, water, and barium during fMRI scans⁽¹⁹⁻²²⁾; others examined swallowing saliva and/or water⁽²³⁻³¹⁾. Swallowing saliva was found to elicit significantly higher BOLD responses in regions important for swallowing than swallowing water and barium⁽³²⁾. The specific experimental design refers to previous studies^(24, 33-40) consisted of task blocks of 36s (with 18 seconds of trial duration and 18 seconds of rest interval) in Run 1 and task blocks of 60s (with 30s trial duration and 30s rest interval) in Run 2, and compare which of them is more suitable for our experiment.

Resting-state fMRI seed-based functional connectivity is a systems-level method to evaluate the link between the seed region and other brain areas. It is an example of the temporal synchronization of scattered brain areas that are connected to certain functions^(41, 42). We want to look into how the peaks activated by swallowing saliva differ in terms of functional connection networks.

In summary, we decided to use saliva swallowing task-based fMRI scans to determine the brain areas that best represents the swallowing movement and compare these areas by statistical analysis of seed-based functional connectivity. All this is to conduct our future studies on the comparison between the traditional stimulation site and the precise task-based fMRI scan stimulation site in TMS treatment of post-stroke dysphagia. Additionally, for individuals undergoing radiation therapy, this approach might be crucial in treating radiation-induced dysphagia. Activation peaks in the bilateral pericentral areas that are critical in the swallowing process may be identified, and we are able to successfully stimulate brain regions related to swallowing utilizing task-based functional magnetic resonance imaging (fMRI) and seed-based functional connectivity analysis. These discoveries offer fresh avenues for the treatment of radiation-induced dysphagia, which could lead to the creation of more efficient rehabilitation techniques and enhance patients' quality of life.

MATERIALS AND METHODS

Participants

Advertisements were used to find eight right-handed healthy participants for experiment I (3 females, ages 18 to 28, mean age standard deviation: $25.8y \pm 1.0$) and fifteen right-handed healthy participants for experiment II (9 females, ages 18 to 28, mean age standard deviation: $24.9y \pm 1.5$). Each subject gave written informed consent and disclosed no history of drunkenness, head injury, or

neurological or mental disorder. The Affiliated Hospital of Hangzhou Normal University's Ethics Committee approved and carried out the entire study. Trial registration number (TRN) is ChiCTR2100054835, with the date of registration: 28 December 2021. <https://www.chictr.org.cn>

Experimental design

All participants had operant training prior to the fMRI experiment to make sure they understood the entire technique, including the rest, task-related functional, and structural scans. During the task trials, participants were told to repeatedly swallow in a regular, comfortable, self-paced cadence while wearing cervical gears to reduce head motion. Additionally, earplugs were worn to lessen scanner noise.

In experiment I, eight participants underwent two task fMRI sessions. During Run 1, participants were required to complete a block design saliva swallowing challenge while being scanned for six minutes on an MRI machine. When an image of an arrow appeared in the center of the screen, participants began to swallow their saliva on their own. An 18-second image was followed by an 18-second fixation. There are 10 blocks in all, with each block lasting 36 seconds. The image lasted for 30 seconds during Run 2, then there was a 30 second fixation. There were 6 blocks total, with each block lasting 60 seconds. Then, in between the two runs, a T1 scan for the structural picture was conducted, during which the subjects were asked to be awake but comfortable, keep their eyes closed, and remain as still as possible. Subject One performed Run 1 first, followed by Run 2, whereas Subject Two performed Run 2 first, followed by Run 1, and so on.

In experiment II, fifteen subjects got two fMRI scans: one while at rest and the other while performing a task (Run 2, which performed better based on experiment I). Participants in the resting-state fMRI session were instructed to keep their eyes closed, unwind, stay as still as possible, not think about anything specific, and avoid dozing off. Additionally, the video was captured while scanning and showed how frequently each trial involved swallowing.

MRI data acquisition

Using a GE 3T scanner (MR-750, GE Medical Systems, Milwaukee, WI), MRI data were gathered at the Center for Cognition and Brain Disorders (CCBD) at Hangzhou Normal University. An 8-minute resting-state session and a 6-minute task session were included in the gradient-echo echo planar imaging (EPI) scanning sessions. The parameters were as follows: repetition time (TR)=2000 ms, echo time (TE)=30 ms, flip angle (FA)=90°, 43 slices with no gap, matrix=64 64, field of view (FOV)=220 220 mm, acquisition voxel size=3.44 3. For precise

localization, a high resolution T1 anatomical picture was scanned (176 sagittal slices, thickness=1 mm, TR=8.1 ms, TE=3.1 ms, FA=8°, FOV=250250 mm).

MRI data analyses

Task and resting-state fMRI data were preprocessed using DPABI_V6.0 (<http://rfmri.org/dpabi>)⁽⁴³⁾, a tool based on the Statistical Parametric Mapping (SPM12) on the MATLAB platform (MathWorks, Natick, MA, United States).

Task fMRI data preprocessing

The following steps were taken in the task data preprocessing: taking into account the acquisition latency between slices; all participants' heads moved no more than 3 millimeters in translation or 3 degrees in rotation in any direction during rigid-body realignment for estimation and correction of the motion displacement; the co-registration of the functional pictures with the T1 image, followed by the normalization to MNI space using the echo-planar imaging (EPI) template for statistical parametric mapping 12 (SPM12, <https://www.fil.ion.ucl.ac.uk/spm/software/spm12/>); spatial smoothing with a 6-mm FWHM (full width at half maximum) Gaussian kernel.

Resting-state fMRI preprocessing

Slice-timing correction was first carried out, after which the first 10 volumes were eliminated. Following that, a six-parameter (rigid body) linear transformation was used to realign the time series of photographs for each patient. Due to head motion that was more than 3 mm in translation or 3 degrees in rotation in any direction, two participants in experiment II were disqualified. The resting-state fMRI data based on rigid-body transformation were then resampled into 3 mm 3 mm 3 mm cubic voxel and normalized to a Montreal Neurological Institute space using the echo-planar imaging template⁽⁴⁴⁾. In order to reduce spatial noise, functional pictures were spatially smoothed using a 6 mm 6 mm 6 mm Gaussian kernel with full width at half maximum. Finally, linear trends estimation was carried out. On all-time series, we applied temporal bandpass filtering (0.01-0.1 Hz).

In DPARSF, FC was investigated using a seed-voxel correlation technique. The peak coordinates was used as the seed point (coordinates: x=27, y=-60, z=-57) in cerebellum_8_R, (coordinates: x=-21, y=-66, z=-51) in cerebellum_8_L, and (coordinates: x=66, y=-6, z=9) in temporal_sup_R, and (coordinates: x=-57, y=-18, z = 24) in Postcentral_L, and (coordinates: x=-3, y=27, z=27) in Cingulum_Ant_L with a radius of 6 mm. The time series of the seed reference and all brain voxels outside of the seed region were then correlated voxel-by-voxel. The correlation coefficients were transformed to Z values using the Fisher r-to-Z transformation.

Using BrainNet Viewer⁽⁴⁵⁾, the outcomes were shown on the surface of the brain and showed decreased or enhanced regional functional connections from seeds.

Statistical analysis

Task fMRI activation detection

SPM12 was used for statistical analysis at the group level and subject-level activation analyses (high-pass filtering, >1/128 Hz, was chosen under "fMRI Model specification"). There were no group-level activation patterns during Run 1 of experiment I. Group-level activation map in Run 2 of experiment I was recorded as figure 1 and table 1 (GRF corrected, voxel level $P < 0.0001$, cluster level $P < 0.05$, two tailed). In experiment II, the group-level activation map was also preserved as figure 2 and table 2 (GRF corrected, voxel level $P < 0.0001$, cluster level $P < 0.05$, two tailed). Later functional connectivity analysis used the peak coordinates as the seeds.

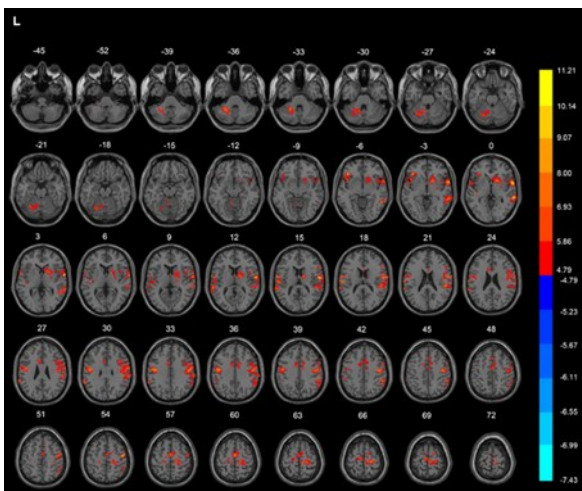


Figure 1. T-score map showing activation for saliva swallowing (hot colors) in transverse slices for Run 2 in experiment I (voxel level $P < 0.0001$, cluster level $P < 0.05$, GRF corrected, cluster size > 10 voxels). L: left hemisphere

Table 1. Brain regions activated by saliva swallowing. AAL: Anatomical Automatic Labeling, L: left, R: right.

Regions (AAL)	Voxel number	T-value	Peak		
			X	Y	Z
Cerebellum_6_L	138	10.9698	-24	-51	-36
Postcentral_L	156	9.5707	-45	-9	36
Precentral_R	188	11.1973	63	3	0
Putamen_R	70	7.5066	18	9	-3
Supp_Motor_Area_R	91	8.1124	0	-9	60

Table 2. Brain regions activated by saliva swallowing for experiment II. The peak coordinates were used as the seeds in later functional connectivity analysis. AAL: Anatomical Automatic Labeling, L: left, R: right.

	Regions (AAL)	Voxel number	T-value	Peak		
				X	Y	Z
Seed1	Cerebellum_8_R	63	8.0396	27	-60	-57
Seed2	Cerebellum_8_L	131	10.1833	-21	-66	-51
Seed3	Temporal_Sup_R	89	9.3734	66	-6	9
Seed4	Postcentral_L	307	10.1881	-57	-18	24
Seed5	Cingulum_Ant_L	69	9.4145	-3	27	27

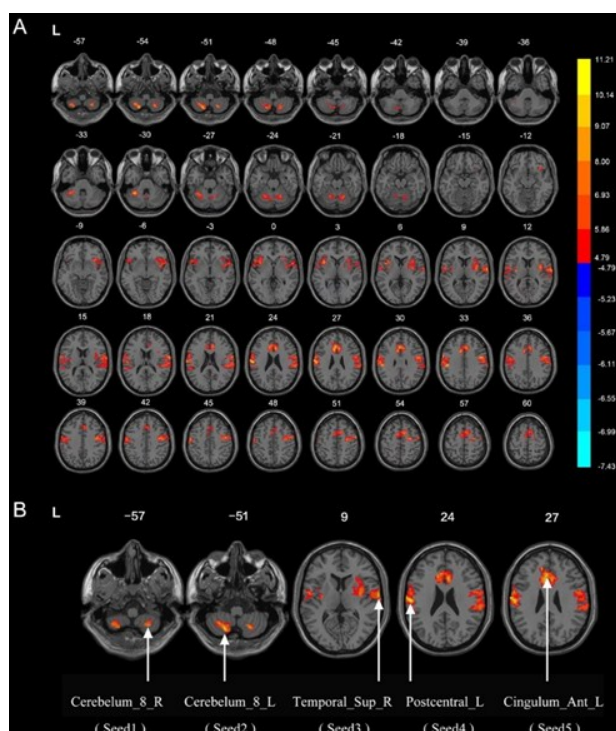


Figure 2. A. T-score map showing activation for saliva swallowing (hot colors) in transverse slices for experiment II (voxel level $P < 0.0001$, cluster level $P < 0.05$, GRF corrected, cluster size > 10 voxels). **B.** The five specific peak points of brain regions activated by saliva swallowing, selected individually as seeds 1-5. L: left, R: right.

Resting-state fMRI functional connectivity

For generating voxel-wise functional connectivity of resting-state fMRI data, the coordinates of the fMRI saliva swallowing peak voxel in table 2 were used as seeds. In experiment II, the functional connectivity was determined by first calculating the mean time course of a sphere (radius 6 mm) centered at the seed coordinate. The two-sample t-test was used to determine how seed affected FC. Additionally, the multiple-comparison correction was carried out using the Gaussian random field (GRF) method. The cluster-level p value was set at 0.005 (two-tailed), while the statistical threshold was set at $P < 0.001$.

Relationship between FC and swallowing frequency

We also performed a partial correlation analysis on the mean FC values from the clusters that were significantly more extensive than the rest to see whether swallowing frequency is relevant. An illustration of the correlation between FC values and swallowing frequency was created using GraphPad Prism 8.0 (La Jolla, CA, USA).

RESULTS

Run 1 versus Run 2 in experiment I

For Run 1, no activation patterns were found in

group-level. As shown in figure 1 and table 1, saliva swallowing in Run 2 led to activation patterns in the left cerebellum, bilateral pericentral gyrus, right putamen and right supplementary motor area (voxel level $P < 0.0001$, cluster level $P < 0.05$, GRF corrected, cluster size > 10 voxels).

Brain areas of saliva swallowing task fMRI activation in experiment II

As shown in figure 2A and table 2, saliva swallowing in experiment II led to activation patterns in the bilateral cerebellum, right superior temporal gyrus, left postcentral gyrus and left anterior cingulate gyrus. (Voxel level $P < 0.0001$, cluster level $P < 0.05$, GRF corrected, cluster size > 10 voxels). The peak voxels and coordinates of brain regions activated by saliva swallowing shown in figure 2B and table 2 were used as the seeds in resting-state fMRI functional connectivity analysis.

Seed-based functional connectivity

Seed1 showed extensive functional connectivity with the bilateral cerebellum, bilateral putamen, right insula, left middle and inferior temporal gyrus, right superior temporal gyrus, left supplementary motor area, bilateral precentral gyrus (figure 3A). Seed2 showed extensive functional connectivity with the bilateral cerebellum, right inferior temporal gyrus, bilateral insula, bilateral superior parietal lobule, right middle cingulate, left precentral gyrus, right superior frontal gyrus and frontal inferior operculum gyrus (figure 3B). Seed3 showed extensive functional connectivity with the bilateral superior temporal gyrus, right middle temporal gyrus, left supplementary motor area and right postcentral gyrus (figure 3C). Seed4 showed extensive functional connectivity with bilateral cerebellum, bilateral postcentral gyrus, bilateral thalamus, bilateral middle temporal gyrus, left lingual gyrus, right middle cingulate, left precentral gyrus, left superior parietal lobule and right superior frontal gyrus (figure 3D). Seed5 showed extensive functional connectivity with the right calcarine, vermis of the cerebellum, left insula, left inferior occipital gyrus, bilateral middle frontal gyrus, left anterior cingulate, right supramarginal gyrus and left precuneus (figure 3E).

Two sample t-tests showed that Seed3 had significantly more intensive functional connectivity than Seed5 in left postcentral gyrus (figure 4A and table 3), Seed4 had significantly more intensive functional connectivity than Seed1, Seed2, Seed5 in right postcentral gyrus (figure 4BCD and table 3), Seed5 had significantly more intensive functional connectivity than Seed1, Seed2, Seed4 in right middle frontal gyrus, right superior frontal gyrus and left supplementary motor area separately (figure 4E-G and table 3). For other seeds in pairs, no discernibly stronger functional connection was discovered.

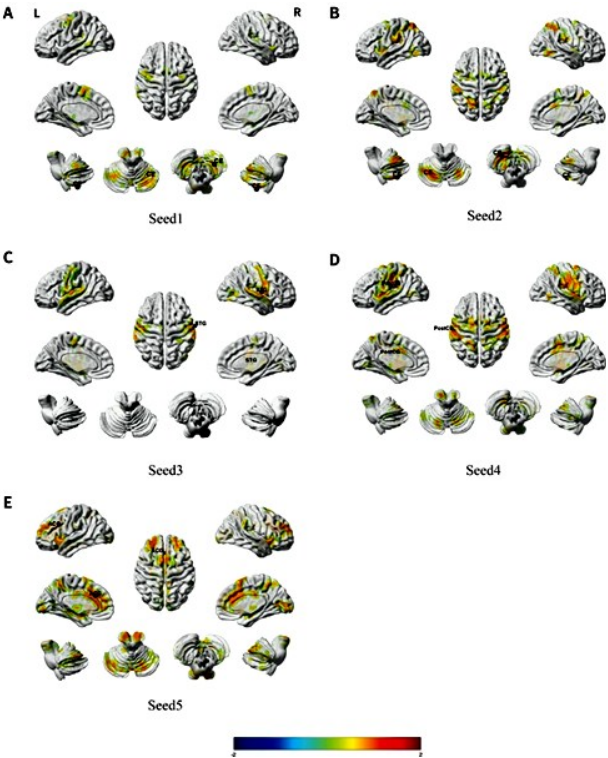


Figure 3. Seed1-5 based whole brain functional connectivity, mapped on the brain surface using BrainNet Viewer (Xia et al., 2013) (voxel level $P < 0.0001$, cluster level $P < 0.05$, GRF corrected, cluster size > 10 voxels). The blue spheres were localizations of seeds. Colors indicate t scores. CE, cerebellum; STG, superior temporal gyrus; PostCG, postcentral gyrus; ACG, anterior cingulate gyrus. L, left hemisphere; R, right hemisphere.

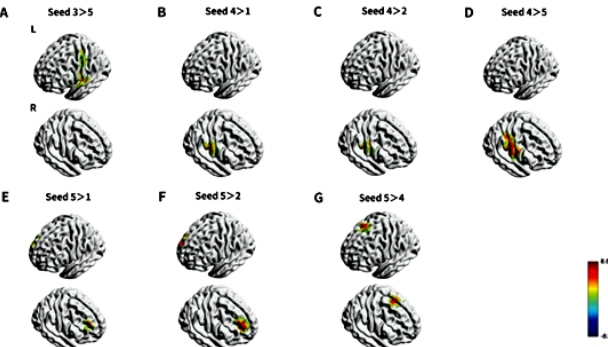


Figure 4. The differences between seed-based functional connectivity. The warm color mapped on the brain surface indicates more intensive Seed3-based functional connectivity than Seed5-based functional connectivity in left postcentral gyrus (A), more intensive Seed4-based functional connectivity than Seed1,2,5-based functional connectivity in right postcentral gyrus (B,C,D), more intensive Seed5-based functional connectivity than Seed1,2,4-based functional connectivity in right middle frontal gyrus (E), right superior frontal gyrus (F) and left supplementary motor area separately (G) (two-sample t-test, voxel level $P < 0.001$, cluster level $P < 0.005$, GRF corrected).

Relationship between FC and swallowing frequency

Based on Seed 3,4,5, no significant positive or negative correlations were discovered between

swallowing frequency and function connection values (figure 5).

Table 3. Regions of changed resting state functional connectivity in participants with different seeds. AAL: Anatomical Automatic Labeling, L: left, R: right.

	Regions (AAL)	Voxels	T-value	Peak		
				X	Y	Z
Seed3>5	Postcentral_L	259	5.3408	-57	-9	9
Seed4>1	Postcentral_R	187	6.2847	60	-15	24
Seed4>2	Postcentral_R	189	6.0507	63	-15	30
Seed4>5	Postcentral_R	744	8.6589	60	-15	24
Seed5>1	Frontal_Mid_R	134	5.9223	27	45	30
Seed5>2	Frontal_Sup_R	263	7.323	21	51	24
Seed5>4	Supp_Motor_Area_L	209	7.0568	9	18	69

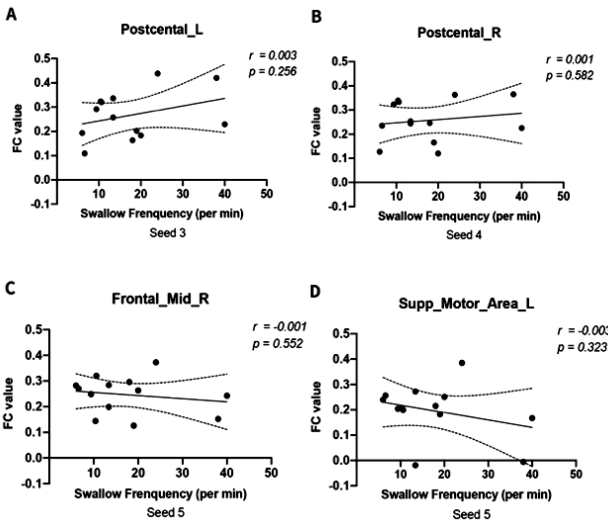


Figure 5. Correlation of swallowing frequency and functional connectivity values based on different seeds. FC: functional connectivity, L: left, R: right.

DISCUSSION

30s-on saliva swallowing trial task led to activation patterns in the left cerebellum, bilateral pericentral gyrus, right putamen and right supplementary motor area while no activations patterns were found in 18s-on task in group level. The peak voxels and coordinates of brain regions activated by saliva swallowing in experiment II were used as the seeds in resting-state fMRI functional connectivity analysis. Two sample t-tests showed that seed in right pericentral area (Seed3), seed in left pericentral area (Seed4) and seed in cingulum (Seed5) had significantly more intensive functional connectivity than some of other seeds.

Our results show that run 2 is better than run 1 for the saliva swallowing task. This may be due to the fact that the 30 s saliva swallowing trial allows more swallows in each block than the 18 s trail, although the number of repetitions is reduced compared to the 18 s trail, the 30 s on-task can activate the swallowing-related brain regions more. In previous studies, the task of swallowing saliva was designed with 10 s to 40 s task trails and equally long rest

intervals, with a total session duration of 2 min 30s to 9 min (24, 33-40). It also seems that to successfully activate swallowing-related brain regions, it is more important to give subjects sufficient time for voluntary swallowing in each block. Therefore, we chose run 2 as the task for the following experiment. The group-level activation patterns in run 2 are the left cerebellum, bilateral pericentral gyrus, right putamen, and right supplementary motor area, all of which are considered functional representational brain regions of swallowing (46), consistent with the findings in the previous review (47). Lateralization is seen in the right putamen and left cerebellum during performance of run 2 in eight healthy participants in experiment I. At the group level, lateralization of particular brain regions vital to swallowing has been documented; however, the results are not always constant and may change depending on the characteristics of swallowing (48, 49). And this may be due to the small number of subjects in experiment I, the result of bilateral activation was obtained after expanding the number of subjects in experiment II.

The functional representative areas of swallowing has been extensively studied, and have been described as follows: bilateral inferior precentral and postcentral gyri (29, 38), bilateral anterior insula (19, 50), anterior cingulate cortex (29), bilateral temporal pole, supplementary motor area (SMA) (35, 50), and bilateral cerebellum (35, 37). All these are highly consistent with the brain areas activated by saliva swallowing task in our experiment (figure 2A). The task we designed can effectively activate swallow-related brain areas, which provides us with a reliable basis for identifying swallow activation peaks.

The traditional rTMS stimulation site is roughly determined by locating the hot-spot area of a single swallowing muscle, e.g., the mylohyoid or pharyngeal muscle (4-6, 8-10). Swallowing is a complex process consisting of a hierarchical sequence of primary motor and somatosensory processes. It is not accurate enough to use a single muscle hot-spot area as rTMS treatment site for poststroke dysphagia. Numerous previous studies have shown that fMRI is a useful imaging technique for investigating changes in neuronal activity in the brain during swallowing, including motor, sensory and autonomic components (51). We believe that peak voxels activated by saliva swallowing in fMRI scans could be better stimulation sites than those identified by traditional route.

The primary motor cortex (M1, precentral gyrus, Brodmann's area 4) was found to be the most prevalent region of activation related to swallowing tasks, following with the primary sensory cortex (S1, postcentral gyrus, somatosensory cortex, Brodmann's area 3, 2, 1) (52). Our study showed that seeds in bilateral cerebellum and pericentral area (Seed1-4) have extensive functional connectivity with the primary motor cortex or the primary sensory cortex. Two sample t-tests showed that seed

in right pericentral area (Seed3) had significantly more intensive functional connectivity than Seed5 in left postcentral gyrus, seed in left pericentral area (Seed4) had significantly more intensive functional connectivity than Seed1, Seed2, Seed5 in right postcentral gyrus. Therefore, we speculate that activation peaks in the bilateral pericentral area (Seed3 and Seed4) are more representative than others in the swallowing process and may be more suitable as therapeutic targets for poststroke dysphagia. An earlier review revealed that rTMS therapy might help stroke patients with dysphagia regain their ability to swallow, however the effectiveness was not statistically different from that of the standard treatment group (3). The possible reason could be the chosen therapeutic target was not the optimal target. The traditional therapeutic target is determined by motor evoked potential of unilateral mylohyoid (5, 6, 10). Mylohyoid is only one of the representative muscles involved in the oral phase of swallowing. Swallowing is a complex sensory-motor process (51), one single muscle cannot represent the entire swallowing process. Functional brain imaging may be able to detect the neuronal patterns that govern this complicated sensory-motor process, elucidating the key neural mechanisms (51).

There is a wide variation in the frequency of swallowing among the different subjects. This could be a potential influencing factor for the functional connectivity analysis. Although the saliva swallowing task has been widely used in fMRI analysis of the swallowing process, the correlation between swallowing frequency and seed-based functional connectivity has never been analyzed (19, 24, 34, 35, 37, 38). We extracted the FC value of brain areas with significant difference in two-sample t-test and performed correlation test with swallowing frequency. And no correlation was found between swallowing frequency and function connectivity values. This would mean that participants could simply be encouraged to repeatedly swallow in a regular, comfortable, and self-paced rhythm in future studies instead of placing a cap on the number of swallows they can make in a particular amount of time.

Limitations and future directions

The study does have certain restrictions. The statistical strength of our analyses was constrained by the study's modest size. Second, as poststroke dysphagia is most common in the elderly, the current findings in young people must be repeated in this population. Our results suggest that saliva swallowing task-based activation peaks in bilateral pericentral areas based on salivary swallowing tasks may be better therapeutic sites for rTMS treatment of poststroke dysphagia. Further studies in patients with poststroke dysphagia are warranted to investigate whether activation peaks can be used as

stimulants better than the swallowing hotspot area in rTMS treatment of poststroke dysphagia.

CONCLUSION

Saliva swallowing trail task with a regular, comfortable, and self-paced rhythm in sufficient time can activate the swallowing-related brain regions effectively. The activation peaks in the bilateral pericentral area are representative in the swallowing process and could be new therapeutic targets for poststroke dysphagia instead of traditional route.

Acknowledgments: The authors thank all the subjects for participating in this study, the Hangzhou Medical and Health Technology Project and the hospital-level scientific research fund project of the Affiliated Hospital of Hangzhou Normal University that provided funding for our work.

Conflicts of interests: The authors have no competing interests to declare that are relevant to the content of this article.

Author contribution: M.C.: Funding acquisition, conceptualization, formal analysis, methodology, writing – original draft, writing – review & editing, supervision. Y.C.: Investigation, resources, writing – review & editing. X.W. and X.Y.: Writing – review & editing. Z.H.: Formal analysis, investigation, resources. W.W.: Formal analysis, investigation, resources.

Ethical consideration: The Ethics Committee of the hospital that is connected with Hangzhou Normal University examined and granted approval for the experiments involving human subjects (2021(E2)-HS-041). To participate in this study, participants provided written informed permission. The relevant participants' written informed consent was obtained before any potentially identifying photos or data were used in this work.

Funding: This work was supported by the Hangzhou Medical and Health Technology Project [grant number A20210513]; and the hospital-level scientific research fund project of the Affiliated Hospital of Hangzhou Normal University [grant number 2021YN2021080].

Data availability statement: The data that support the findings of this study are available on request from the corresponding author upon reasonable request.

REFERENCES

- Martino R, Foley N, Bhogal S, Diamant N, Speechley M, Teasell R (2005) Dysphagia after stroke: incidence, diagnosis, and pulmonary complications. *Stroke*, **36**(12): 2756-2763.
- Suntrup S, Kemmling A, Warnecke T, et al. (2015) The impact of lesion location on dysphagia incidence, pattern and complications in acute stroke. Part 1: dysphagia incidence, severity and aspiration. *European Journal of Neurology*, **22**(5): 832-838.
- Yang W, Cao X, Zhang X, Wang X, Li X, Huai Y (2021) The effect of repetitive transcranial magnetic stimulation on dysphagia after stroke: A systematic review and meta-analysis. *Frontiers in Neuroscience*, **15**: 769848.
- Lim KB, Lee HJ, Yoo J, Kwon YG (2014) Effect of low-frequency rTMS and NMES on subacute unilateral hemispheric stroke with dysphagia. *Annals of Rehabilitation Medicine-Arm*, **38**(5): 592-602.
- Kim L, Chun MH, Kim BR, Lee SJ (2011) Effect of repetitive transcranial magnetic stimulation on patients with brain injury and dysphagia. *Annals of Rehabilitation Medicine-Arm*, **35**(6): 765-771.
- Park E, Kim MS, Chang WH, et al. (2017) Effects of bilateral repetitive transcranial magnetic stimulation on post-stroke dysphagia. *Brain Stimulation*, **10**(1): 75-82.
- Park JW, Oh JC, Lee JW, Yeo JS, Ryu KH (2013) The effect of 5Hz high-frequency rTMS over contralesional pharyngeal motor cortex in post-stroke oropharyngeal dysphagia: a randomized controlled study. *Neurogastroenterology and Motility*, **25**(4): 250-324.
- Unluer NO, Temucin CM, Demir N, Serel AS, Karaduman AA (2019) Effects of low-frequency repetitive transcranial magnetic stimulation on swallowing function and quality of life of post-stroke patients. *Dysphagia*, **34**(3): 360-371.
- Khedr EM, Abo-Elfetoh N, Rothwell JC (2009) Treatment of post-stroke dysphagia with repetitive transcranial magnetic stimulation. *Acta Neurologica Scandinavica*, **119**(3): 155-161.
- Khedr EM and Abo-Elfetoh N (2010) Therapeutic role of rTMS on recovery of dysphagia in patients with lateral medullary syndrome and brainstem infarction. *Journal of Neurology Neurosurgery and Psychiatry*, **81**(5): 495-499.
- Rao J, Li F, Zhong L, et al. (2022) Bilateral cerebellar intermittent theta burst stimulation combined with swallowing speech therapy for dysphagia after stroke: A randomized, double-blind, sham-controlled, clinical trial. *Neurorehabilitation and Neural Repair*, **36**(7): 437-448.
- Sasegbon A, Smith CJ, Bath P, Rothwell J, Hamdy S (2020) The effects of unilateral and bilateral cerebellar rTMS on human pharyngeal motor cortical activity and swallowing behavior. *Experimental Brain Research*, **238**(7-8): 1719-1733.
- Vasant DH, Michou E, Mistry S, Rothwell JC and Hamdy S (2015) High-frequency focal repetitive cerebellar stimulation induces prolonged increases in human pharyngeal motor cortex excitability. *Journal of Physiology-London*, **593**(22): 4963-4977.
- Sasegbon A, Niziolek N, Zhang M, et al. (2021) The effects of mid-line cerebellar rTMS on human pharyngeal cortical activity in the intact swallowing motor system. *Cerebellum*, **20**(1): 101-115.
- Jayasekaran V, Rothwell J, Hamdy S (2011) Non-invasive magnetic stimulation of the human cerebellum facilitates cortico-bulbar projections in the swallowing motor system. *Neurogastroenterology and Motility*, **23**(9): 341-831.
- Vasant DH, Sasegbon A, Michou E, Smith C, Hamdy S (2019) Rapid improvement in brain and swallowing behavior induced by cerebellar repetitive transcranial magnetic stimulation in poststroke dysphagia: A single patient case-controlled study. *Neurogastroenterology and Motility*, **31**(7): e13609.
- Ogawa S, Tank DW, Menon R, et al. (1992) Intrinsic signal changes accompanying sensory stimulation: functional brain mapping with magnetic resonance imaging. *Proceed Nat Acad Sci USA*, **89**(13): 5951-5955.
- Soros P, Inamoto Y, Martin RE (2009) Functional brain imaging of swallowing: an activation likelihood estimation meta-analysis. *Human Brain Mapping*, **30**(8): 2426-2439.
- Humbert IA, Fitzgerald ME, McLaren DG, et al. (2009) Neurophysiology of swallowing: effects of age and bolus type. *Neuroimage*, **44**(3): 982-991.
- Kawai T, Watanabe Y, Tonogi M, et al. (2009) Visual and auditory stimuli associated with swallowing: an fMRI study. *Bulletin of Tokyo Dental College*, **50**(4): 169-181.
- Babaei A, Kern M, Antonik S, et al. (2010) Enhancing effects of flavored nutritive stimuli on cortical swallowing network activity. *American Journal of Physiology-Gastrointestinal and Liver Physiology*, **299**(2): G422-G429.
- Humbert IA, McLaren DG, Kosmatka K, et al. (2010) Early deficits in cortical control of swallowing in Alzheimer's disease. *Journal of Alzheimers Disease*, **19**(4): 1185-1197.
- Malandraki GA, Perlman AL, Karampinos DC, Sutton BP (2011) Reduced somatosensory activations in swallowing with age. *Human Brain Mapping*, **32**(5): 730-743.
- Martin RE, MacIntosh BJ, Smith RC, et al. (2004) Cerebral areas processing swallowing and tongue movement are overlapping but distinct: a functional magnetic resonance imaging study. *Journal of*

- Neurophysiology*, **92**(4): 2428-2443.
25. Mosier K, Liu WC, Behin B, Lee C, Baredes S (2005) Cortical adaptation following partial glossectomy with primary closure: implications for reconstruction of the oral tongue. *Ann Oto Rhino Laryngo*, **114**(9): 681-687.
 26. Martin R, Barr A, MacIntosh B, et al. (2007) Cerebral cortical processing of swallowing in older adults. *Experimental Brain Research*, **176**(1): 12-22.
 27. Li S, Chen Q, Yu B, et al. (2009) Structural and functional changes mapped in the brains of amyotrophic lateral sclerosis patients with/without dysphagia: a pilot study. *Amyotroph Lateral Scler*, **10**(5-6): 280-287.
 28. Li S, Luo C, Yu B, et al. (2009) Functional magnetic resonance imaging study on dysphagia after unilateral hemispheric stroke: a preliminary study. *Journal of Neurology Neurosurgery and Psychiatry*, **80**(12): 1320-1329.
 29. Malandraki GA, Sutton BP, Perlman AL, Karampinos DC, Conway C (2009) Neural activation of swallowing and swallowing-related tasks in healthy young adults: an attempt to separate the components of deglutition. *Human Brain Mapping*, **30**(10): 3209-3226.
 30. Malandraki GA, Sutton BP, Perlman AL, Karampinos DC (2010) Age-related differences in laterality of cortical activations in swallowing. *Dysphagia*, **25**(3): 238-249.
 31. Haupage S, Peck KK, Branski RC, Hsu M, Holodny A, Kraus D (2010) Functional MRI of tongue motor tasks in patients with tongue cancer: observations before and after partial glossectomy. *Neuroradiology*, **52**(12): 1185-1191.
 32. Michou E, Mistry S, Jefferson S, Singh S, Rothwell J, Hamdy S (2012) Targeting unlesioned pharyngeal motor cortex improves swallowing in healthy individuals and after dysphagic stroke. *Gastroenterology*, **142**(1): 29-38.
 33. Birn RM, Bandettini PA, Cox RW, Shaker R (1999) Event-related fMRI of tasks involving brief motion. *Human Brain Mapping*, **7**(2): 106-114.
 34. Martin RE, Goodyear BG, Gati JS, Menon RS (2001) Cerebral cortical representation of automatic and volitional swallowing in humans. *Journal of Neurophysiology*, **85**(2): 938-950.
 35. Mosier K and Bereznaya I (2001) Parallel cortical networks for volitional control of swallowing in humans. *Experimental Brain Research*, **140**(3): 280-289.
 36. Komisaruk BR, Mosier KM, Liu WC, et al. (2002) Functional localization of brainstem and cervical spinal cord nuclei in humans with fMRI. *American Journal of Neuroradiology*, **23**(4): 609-617.
 37. Suzuki M, Asada Y, Ito J, Hayashi K, Inoue H, Kitano H (2003) Activation of cerebellum and basal ganglia on volitional swallowing detected by functional magnetic resonance imaging. *Dysphagia*, **18**(2): 71-77.
 38. Toogood JA, Barr AM, Stevens TK, Gati JS, Menon RS, Martin RE (2005) Discrete functional contributions of cerebral cortical foci in voluntary swallowing: a functional magnetic resonance imaging (fMRI) "Go, No-Go" study. *Experimental Brain Research*, **161**(1): 81-90.
 39. Kern MK, Jaradeh S, Arndorfer RC, Shaker R (2001) Cerebral cortical representation of reflexive and volitional swallowing in humans. *American Journal of Physiology-Gastrointestinal and Liver Physiology*, **280**(3): G354-G360.
 40. Jing YH, Lin T, Li WQ, et al. (2020) Comparison of activation patterns in mirror neurons and the swallowing network during action observation and execution: a task-based fMRI study. *Frontiers in Neuroscience*, **14**: 867.
 41. Cole DM, Smith SM, Beckmann CF (2010) Advances and pitfalls in the analysis and interpretation of resting-state FMRI data. *Frontiers in Systems Neuroscience*, **4**: 8.
 42. Hampson M, Peterson BS, Skudlarski P, Gatenby JC, Gore JC (2002) Detection of functional connectivity using temporal correlations in MR images. *Human Brain Mapping*, **15**(4): 247-262.
 43. Yan CG, Wang XD, Zuo XN, Zang YF (2016) DPABI: Data Processing & Analysis for (Resting-State) Brain Imaging. *Neuroinformatics*, **14**(3): 339-351.
 44. Calhoun VD, Wager TD, Krishnan A, et al. (2017) The impact of T1 versus EPI spatial normalization templates for fMRI data analyses. *Human Brain Mapping*, **38**(11): 5331-5342.
 45. Xia M, Wang J, He Y (2013) BrainNet Viewer: a network visualization tool for human brain connectomics. *Plos One*, **8**(7): e68910.
 46. Mihai PG, Otto M, Platz T, Eickhoff SB, Lotze M (2014) Sequential evolution of cortical activity and effective connectivity of swallowing using fMRI. *Human Brain Mapping*, **35**(12): 5962-5973.
 47. Michou E and Hamdy S (2009) Cortical input in control of swallowing. *Current Opinion in Otolaryngology & Head and Neck Surgery*, **17**(3): 166-171.
 48. Balasubramaniam RK, Dodderi T, Bhat JS (2017) Does Cerebral Hemispheric Laterality Control Swallow Performance? *Neurology Research International*, **2017**: 8762610.
 49. Lowell SY, Reynolds RC, Chen G, Horwitz B, Ludlow CL (2012) Functional connectivity and laterality of the motor and sensory components in the volitional swallowing network. *Experimental Brain Research*, **219**(1): 85-96.
 50. Mihai PG, von Bohlen UHO, Lotze M (2013) Differentiation of cerebral representation of occlusion and swallowing with fMRI. *American Journal of Physiology-Gastrointestinal and Liver Physiology*, **304**(10): G847-G854.
 51. Lima MS, Mangilli LD, Sassi FC, Andrade CR (2015) Functional magnetic resonance and swallowing: critical literature review. *Brazilian Journal of Otorhinolaryngology*, **81**(6): 671-680.
 52. Humbert IA and Robbins J (2007) Normal swallowing and functional magnetic resonance imaging: a systematic review. *Dysphagia*, **22**(3): 266-275.