

Integrated radiologic diagnosis of pulmonary artery intimal sarcoma: Report of three cases and literature review

X. Fu^{1,2*}, J. Zhao^{2#}, Q. Liu², J. Jia², M. Wang²

¹Zhejiang Chinese Medical University, Hangzhou, Hangzhou, China

²Department of Pathology, Affiliated Jinhua Hospital, Zhejiang University School of Medicine, Hangzhou, China

► Case report

*Corresponding author:

Xiaodan Fu, BM.,

E-mail:

13586980761@163.com

Received: April 2025

Final revised: June 2025

Accepted: June 2025

Int. J. Radiat. Res., April 2025;
23(2): 497-502

DOI: 10.61186/ijrr.23.2.34

Keywords: PAIS, endarterectomy, computed tomography angioplasty.

Xiaodan Fu and Jingwen Zhao contributed equally to this work.

ABSTRACT

Background: Pulmonary artery intimal sarcoma (PAIS), a rare malignancy arising primarily within the pulmonary artery's intimal layer, exhibits an estimated prevalence ranging from 0.001% to 0.003%. Due to overlapping clinical manifestations and imaging characteristics, PAIS is frequently mistaken for acute or chronic pulmonary thromboembolism. Tissue biopsy remains the authoritative method for establishing diagnosis. Regarding therapy, surgery is the principal approach, and undertaking thorough surgical resection alongside endarterectomy yields improved survival outcomes. **Case Presentations:** This study presents three cases of PAIS, analyzing their radiological characteristics, pathological findings, and therapeutic approaches. A comprehensive review of the literature on this condition is also provided. **Conclusion:** Timely detection proves paramount and can significantly enhance patient prognosis. Complete surgical resection is pivotal for improving prognosis, and multidisciplinary collaboration (e.g., radiology, pathology, and thoracic surgery) plays a vital role in formulating precise diagnostic and therapeutic strategies.

INTRODUCTION

Pulmonary artery intimal sarcoma (PAIS), first reported by Mandelstamm, is a rare primary malignant neoplasm, and approximately 400 cases have been reported to date ⁽¹⁾. The disease can occur at any age, with a mean onset age of approximately 45-54 years, while the association between its incidence and gender remains controversial ^(2,3). Arising within the pulmonary artery's intimal layer ⁽⁴⁾, this malignancy demonstrates mesenchymal histogenesis and is associated with unfavorable oncological prognoses. Its incidences are only 0.001% to 0.03% ⁽⁵⁾, but the exact incidence of PAIS is difficult to determine because of its rarity and imitation with pulmonary embolism. PAIS is also aggressive, invading the surrounding tissues in a local invasive manner, and the prognosis of patients is poor. There is no standard treatment for this disease, and surgery is still the first choice of treatment, such as pulmonary endarterectomy, lobectomy or pneumonectomy. PAIS is frequently misdiagnosed as acute or chronic thromboembolism. Furthermore, intimal sarcoma arising from the pulmonary valve may clinically mimic chronic thromboembolic pulmonary hypertension (CTEPH) ⁽⁶⁾. No established standard of care exists for PAIS. Surgical resection, radiotherapy, chemotherapy, and targeted agents

have been utilized ⁽⁷⁾.

We describe three cases, including one erroneously diagnosed as pulmonary thromboembolism (PTE) and administered thrombolytic therapy. This study synthesizes current evidence on pulmonary intimal sarcoma's clinical manifestations, diagnostic approaches, differential considerations, and management paradigms, aiming to heighten clinical vigilance against initial diagnostic errors. These findings provide an original evidence-based framework for the precision diagnosis, molecular subtyping, and targeted therapeutic strategies of PAIS.

Case presentation 1

A 70-year-old male has experienced predominantly progressive dyspnea and chest pain for approximately 10 months. The patient also presented with cough and expectoration, but did not exhibit fever, lower extremity edema, smoking history. The patient denied any significant past medical history.

On admission, physical examination was unremarkable. The tumor marker and procalcitonin levels were within the normal range. D-dimer levels were 588 ug/L, slightly higher than the normal limit (0-500 ug/L). Triglyceride and high-density lipoprotein were 2.02 mmol/L and 0.85 mmol/L,

respectively. Based on the patient's clinical history and examination findings, coronary atherosclerotic heart disease was initially suspected and a coronary computed tomography angioplasty (CTA) was performed, which revealed embolization of the main pulmonary artery (PA) and right branch. Computed tomography pulmonary angiography (CTPA) scan (Philips Healthcare Spectral CT 7500) revealed that there are filling defects lesions in the PA (figure 1A). A cardiac magnetic resonance imaging (MRI) (Canon Medical Systems) showed that there are filling defects within the PA trunk, right PA and first-order branches (figure 1B). According to these findings primary or metastatic malignancy was suspected, but PTE could not be completely excluded. Patient refuses further examination and treatment.

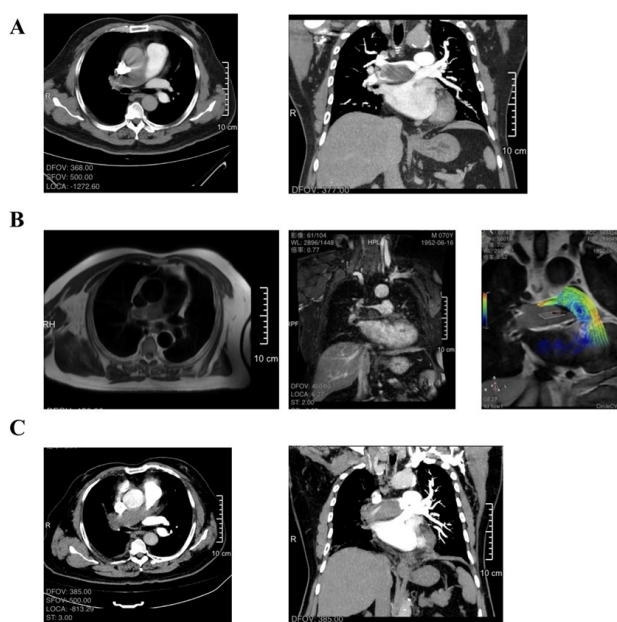


Figure 1. (A) CTPA showed the intraluminal deflections in the main pulmonary artery. (B) Cardiac MRI shows tissue-like filling defects lesions arising from the main pulmonary arteries and extending into their branches. The lesions were poor enhancing and caused almost complete occlusion of the main PA. (C) After nine months, CTPA showed the intraluminal lesion was larger.

Nine months later, the patient was admitted to hospital again due to worsening chest discomfort and dyspnea. CTPA showed that the lesion was larger and more advanced than before (figure 1C). As a result, the patient received a pulmonary artery biopsy. Microscopic examination revealed the mass was composed of a mass of necrotic cell and a small number of a hypercellular spindle cell population with mild atypia (figure 2A). Immunohistochemical staining showed strong and diffuse positivity of cyclin-dependent kinase 4 (CDK4), integrase interactor 1 (INI-1), and smooth muscle actin (SMA). The tumor cells were negative for desmin (Des) (table 1). The fluorescence in situ hybridization (FISH) of mouse double minute 2 homolog (MDM2) amplification was positive (figure 2B). Finally, the histopathological

results confirmed PAIS.

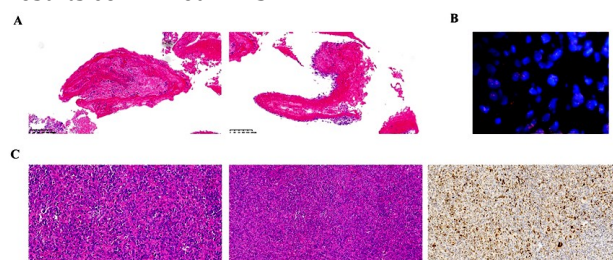

Figure 2. (A) Necrosis and a small amount of short spindle tumor cells could be found in biopsy tissue (100×). (B) The FISH of MDM2 amplification was positive. (C) Tumor cells were spindle growth arrangement and mitosis could be found in tumor surgical specimens (100). The tumor cells showed positive expression of MDM2 (right 100×).

The patient received definitive surgical management comprising En bloc resection of the pulmonary artery tumor mass. At surgery, surgeons found that the tumor occupied the entire length of the pulmonary artery and invaded the heart, spreading into the lungs. As a result, the patient underwent re-section of the tumor, and resection of involved lung. On macroscopic view, the specimen was a grey-whitish, solid, soft tissue mass measuring 7.2×5.7×1.4 cm. In the resected lung tissue, multiple nodules with a maximum diameter of 0.3 to 6.3 cm were observed. Histopathological examination demonstrated proliferation of hyperchromatic spindle cells arranged in fascicular patterns, consistent with PAIS. Solid neoplasms composed of these tumor cells exhibit invasive growth originating in the pulmonary artery intima and penetrating to the adventitia. Significant atypia is evident in most tumor cells. Immunohistochemical evaluation revealed positive staining for MDM2 in the neoplastic cell population (figure 2C). Morphological and immunohistochemical (IHC) profiles confirmed PAIS, with concomitant multifocal tumor metastases and pulmonary parenchymal infiltration. After surgery, the patient died as his blood pressure and heart rate continued to fall and he was unable to resuscitate.

Case presentation 2

A 70-year-old female patient presented with a month history of chest discomfort and a 12.5 kg weight loss over the past three months. The patient had hydrocephalus and right popliteal tumor in history. At the time of admission, the patient was emaciated, but conscious and his vital signs were stable. Pulmonary auscultation revealed normal ventilation in both lungs, with no bibasilar crackles and rhonchi sounds. Cardiac auscultation detected arrhythmia. Carbohydrate antigen-125 (CA-125) and D-dimer levels were 107.16 U/ml and 2230 ug/L, respectively, much higher than normal level (0.00–31.3.00 U/ml and 0–500 ug/L). Chest computed tomography (CT) and abdomen CT revealed a space-occupying lesion in the hilus of the left lung, accompanied with multiple nodules in the

upper lobe and swollen lymph node, and abdominal cavity occupancy, suggestive of a possible tumor (figure 3A and B). Invasion of the left pulmonary artery and vein was also detected in CTPA (figure 3C). Based on the examination results, primary lung carcinoma with systemic metastasis is the primary concern. As the patient's tumor was advanced and surgery was not currently an option, lung aspiration biopsy was performed to determine the pathology.

Surprisingly, histopathology revealed the tissue to be sarcoma, with spindle cells and mitotic figures easily identified. Microscopically, the tumor cells had hyperchromatic nuclei, prominent nucleoli and abundant eosinophilic cytoplasm and necroptosis

was frequent (figure 4A). Immunohistochemical findings showed positivity for MET proto-oncogene (C-met), epidermal growth factor receptor (EGFR), SWI/SNF-related matrix-associated actin-dependent regulator of chromatin subfamily B member 1 (SMARCB1/Brg1), INI-1 and MDM2. Anaplastic lymphoma kinase (ALK), cytokeratin 7 (CK7), cytokeratin 5/6 (CK5/6), Des, SMA and cluster of differentiation 34 (CD34) were not expressed. FISH of MDM2 amplification was positive (figure 4B). Considering the patient's older age, past history medical, and is in a state of advanced tumor, the patient and his family refused further treatment. After 20 days of follow-up, the patient died.

Table 1. Three cases of PAIS diagnosed at our study.

Case	Age, years	Sex	Invasion site	Mis-diagnose	Treatment	Outcome	IHC	MDM2 gene
1	70	man	Main PA and extending into the right PA	No	Surgery	Died	CDK4 (+) Des (-) INI-1 (+) SMA (+)	Positive
2	70	Woman	Main PA and extending into the left PA, and lung	Yes	NO	Died	SMA (-) Des (-) INI-1 (+)	Positive
3	74	man	Main PA and extending into the branches.	No	Surgery	Died	SMA (+) CDK4 (+) INI-1 (+)	--

--no examination. PAIS, Pulmonary Artery Intimal Sarcoma; PA, Pulmonary Artery.

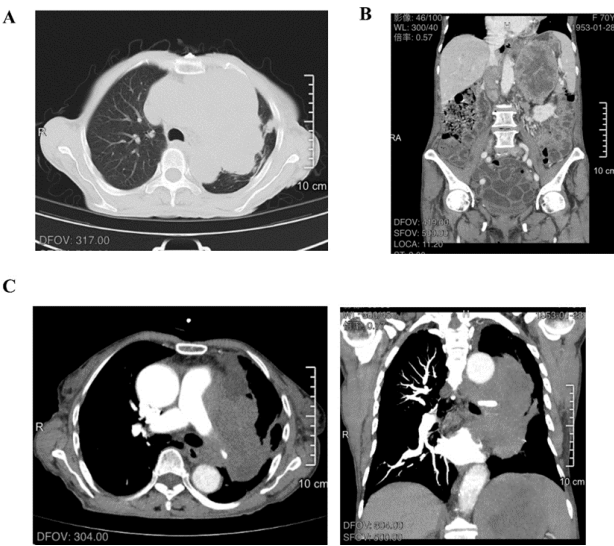


Figure 3. (A and B) The tumor was founded in lung and peritoneal cavity in chest and abdomen CT. (C) CTPA showed the tumor invaded in left pulmonary artery and vein.

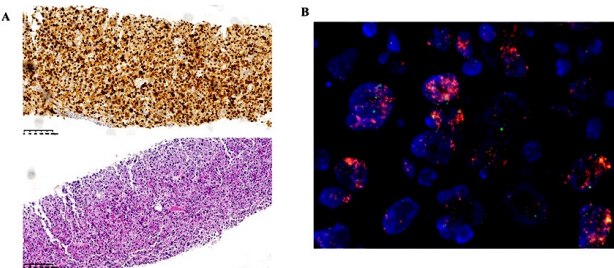


Figure 4. (A) Spindle cells and mitotic figures easily identified in lung biopsy tissue (left, 100x) and MDM2 was positive expressed in tumor cells (right, 100x). (B) The FISH of MDM2 amplification was positive.

Case presentation 3

A 74-year-old male consulted to external hospital with the chief complaints of dyspnea and weak persisting for 7 days. Due to suspected PTE, the patient was transferred to our emergency department. Upon arrival, recorded vital signs included a temperature of 36.3°C, BP 109/76 mmHg, HR 83 bpm, and RR 10 bpm, with room air SpO₂ at 87.7%. The D-dimer value was 1867 ug/L (normal range <500 ug/L). The patient presented with concurrent severe infection, evidenced by leukocytosis (20.35×10⁹/L; reference: 3.5-9.5×10⁹/L). Doppler ultrasonography demonstrated right ventricular dilatation, pulmonary arterial enlargement, and a proximal pulmonary trunk thrombus. Subsequent CT pulmonary angiography revealed extensive filling defects within the main pulmonary artery extending into its bifurcation (figure 5A), characteristic of PAIS.

Initially, diagnosed with pulmonary embolism, the patient received subcutaneous enoxaparin sodium (4,000 AxaIU; 100 AxaIU/kg every 12h) and two doses of alteplase. After five days of failed therapy with persistent D-dimer elevation, surgical intervention was indicated to relieve pulmonary artery obstruction and establish diagnosis. Interventional thrombectomy subsequently extracted copious amounts of white thrombus.

To our surprise, under the microscope, these 'white thrombus' removed from the PA are not thrombus, but are hyperchromatic spindle cells and pleomorphic cells (figure 5B). An immunohistochemical analysis showed that

SMA-positive, CDK4-positive, MDM2-positive. The final pathological diagnosis is PAIS. After surgery, the symptom of the patient was improved, but after six months, patient died because of tumor progression.

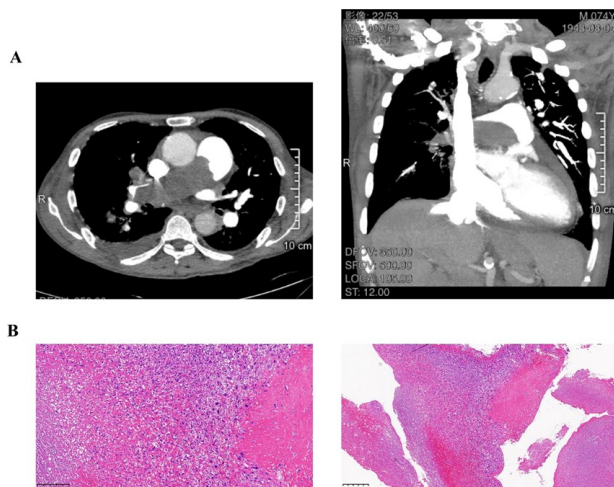


Figure 5. (A) CTPA showed intraluminal defects in the main pulmonary artery. **(B)** Histopathology showed much Necrosis and Heteromorphic tumor cells (100×).

DISCUSSION

PAIS is exceptionally rare, with a pathogenesis that remains poorly understood⁽⁵⁾. Current hypotheses implicate dysregulation in the MDM2-p53 pathway⁽⁸⁾, Li-Fraumeni syndrome⁽⁹⁾, or platelet-derived growth factor receptor β (PDGFRB)⁽¹⁰⁾. The median age at diagnosis is 50 years (range: 13 – 86 years)⁽¹¹⁾, with only one documented pediatric case (age 2 years)⁽¹²⁾. Though epidemiological studies suggest a female predominance (male-to-female ratio: 1:1.3)⁽¹³⁾, Cox *et al.* reported no gender-based incidence disparity⁽¹⁴⁾. Further supporting this contradiction, prior analyses found no sex-specific variations in disease prevalence or clinical outcomes⁽¹⁵⁾. PAIS demonstrates predilection for the main pulmonary artery (80%), unilateral pulmonary arteries (50-70%), or bilateral involvement (40%)⁽¹³⁾. Vascular obstruction by the tumor typically manifests as right ventricular failure with characteristic symptoms: chest pain, dyspnea, productive cough, chest constriction, peripheral edema, and hemoptysis. Constitutional manifestations including weight loss, fever, syncope, asthenia, and anorexia may also indicate systemic neoplastic effects⁽¹⁶⁾. In this study, Case1 is a slow process of right ventricular failure until the tumor progresses to an unbearable re-hospitalization. Case2 patients were well tolerated, and the clinical symptoms were not obvious. However, her weight was reduced by 12.5 kg within 3 months, which was very important to note. Case3 is an emergency patient with the clinical symptoms very similar to those of PTE. Pathological assessment

remains the diagnostic cornerstone for PAIS. Histopathology typically reveals poorly differentiated or undifferentiated malignant neoplasms composed of spindle or epithelioid cells with variable atypia⁽¹⁷⁾. Immunohistochemically, PAIS demonstrates inconsistent Des, CD34, and SMA expression but consistent negativity for endothelial/epithelial markers, h-caldesmon, and S100 protein^(17, 18). MDM2, a p53-inhibiting proto-oncogene shows immunohistochemical expression in most PAIS cases, correlating with MDM2 gene amplification at 12q14-15^(19, 20). In our three cases, HE staining revealed similar characteristic features: extensive necrosis, predominantly fusiform/oval tumor cells with pleomorphic nuclei, prominent nucleoli, and frequent mitotic figures. MDM2 amplification detected via in situ hybridization aids definitive diagnosis⁽⁴⁾; Jimbo *et al.* confirm MDM2 dual-color ISH (DISH) as a reliable FISH alternative⁽⁸⁾. All present cases exhibited classic pathology-MDM2 immunopositivity or high-level FISH-confirmed amplification-with uniform Desmin negativity and INI-1/CDK-4 positivity. Only Case 2 lacked SMA expression. Though RUNX1, nestin, WT1, and CD44 expression suggests pulmonary artery intimal sarcoma (ISPA) originates from vascular wall-resident stem cells⁽²¹⁾, these markers hold no clinical utility.

PAIS and PTE are easily confused, so examination is also very important. However, the results of laboratory examinations are often non-specific. The high tumor markers may be having certain directivity, but not the most important.

The electrocardiogram (ECG) primarily demonstrated right ventricular pressure overload, hypertrophy, and ST-T wave abnormalities, while color Doppler echocardiography revealed right ventricular enlargement, pulmonary hypertension, and tricuspid regurgitation; these findings are non-specific⁽¹⁰⁾. In the present case, however, echocardiography additionally identified a thrombus within the pulmonary trunk and its left and right branches, alongside right heart and pulmonary artery dilation. This thrombus significantly strengthened the probability of pulmonary embolism in case3. CT is the technique that enabled the first step in the differential diagnosis between PAIS and pulmonary embolism. While thorax-CT cannot definitively differentiate between PA thrombus and tumor⁽²²⁾, certain imaging features strongly suggest a tumor. These include a distinctive filling defect completely obliterating the pulmonary trunk lumen accompanied by vessel dilatation, along with heterogeneous and delayed contrast enhancement on CT angiography, which is particularly prominent during the venous phase⁽²³⁾. Additionally, CTPA is the preferred method for detecting pulmonary artery tumors. It can effectively visualize space-occupying lesions within the pulmonary artery, though qualitative diagnosis is often challenging. Clinical experience indicates that

when imaging of pulmonary artery obstruction shows invasion of the vascular wall and adjacent extravascular structures, or when the lesion involves the pulmonary valve and right ventricular outflow tract (manifested as lobulation sign and/or separation sign), pulmonary artery tumor should be highly suspected^(13, 24). The present case's CT and PTCA images demonstrated concordance with the previously outlined features. Differentiation between PAIS and pulmonary embolism was more effectively achieved using positron emission tomography CT (PET-CT), owing to its ability to measure the intensity of metabolic tracer uptake. At a 3.3 cutoff threshold, diagnostic performance demonstrated 98.4% sensitivity, 96.8% specificity, and 97.8% accuracy⁽²⁰⁾. However, hypodense PAIS variants with high mucinous content exhibit standardized uptake values (SUVs) overlapping pulmonary thromboembolism (PTE) ranges⁽²⁵⁾. Cardiac magnetic resonance further enables tissue characterization of lesions and differentiation between thrombotic versus neoplastic components by assessing vascularization patterns and tissue edema extent⁽²²⁾. Following paramagnetic contrast administration, black-blood T1-weighted imaging demonstrated avid enhancement in cardiac masses but absence of enhancement in thrombi⁽²³⁾. Medical imaging remains indispensable for detecting pulmonary artery lesions, yet reliably distinguishing tumor occlusion from pulmonary vascular embolism persists as a diagnostic challenge. Consequently, histopathological sampling through biopsy constitutes the definitive diagnostic step.

CONCLUSION

Early diagnosis leveraging integrated imaging remains pivotal for prognostic improvement in this condition. To date, there is no standard treatment for PAIs and Prognosis is poor. Patients demonstrate a median survival of 12 – 18 months post-symptom onset, with corresponding 1-year and 2-year survival rates of 22% and 7% respectively. Whereas surgical resection extends survival to 3 years, disease progression precluding surgery-particularly progressive right heart failure-correlates with a markedly reduced median survival of merely 6 weeks. Current evidence suggests immunotherapy as a promising therapeutic alternative. Early detection via multimodal imaging integration represents the primary strategy for enhancing clinical outcomes.

ACKNOWLEDGMENT

Not applicable.

Ethical consideration: This study was approved by the ethics committee of Affiliated Jinhua Hospital (Approval no. 24-JH-031). Signed written informed consents were obtained from the patients and/or

guardians. This study was conducted in accordance with the Declaration of Helsinki.

Funding: Not applicable.

Conflict of Interests: The authors affirm the absence of any competing interests.

Author contribution: X.F., provided expert insights into experimental design and data acquisition, laying the critical foundation for this study; J.Z., enhanced the scientific rigor through meticulous data analysis and literature synthesis. Q.L, J.J, M.W., were involved in all parts of the study. All authors read and approved final manuscript for publication.

REFERENCES

- Atahan C, Gural Z, Yucel S, Agaoglu F (2024) Pulmonary artery intimal sarcoma: Case report of a patient managed with multimodality treatment and a comprehensive literature review. *Strahlentherapie Und Onkologie*, **200**(8): 725-729.
- Bandyopadhyay D, Panchabhai TS, Bajaj NS, Patil PD, Bunte MC (2016) Primary pulmonary artery sarcoma: a close associate of pulmonary embolism-20-year observational analysis. *Journal of Thoracic Disease*, **8**(9): 2592-2601.
- Chen D, Zhu G, Wang D, Zhang Z, Fang W, Qu Z (2016). Clinico-pathological and immunohistochemical features of pulmonary artery sarcoma: A report of three cases and review of the literature. *Oncology letters*, **11**(4): 2820-2826.
- Xu R, Zhao Y, Xu X, et al. (2020) Pulmonary intimal sarcoma involving the pulmonary valve and right ventricular outflow tract: A case report and literature review. *Medicine*, **99**(3): e18813.
- Westhofen S, Kugler C, Reichenspurner H, Deuse T (2016) Acute pulmonary artery obstruction as the primary manifestation of a rapidly growing intimal sarcoma in a 54-year-old patient. *Thoracic and Cardiovascular Surgeon Reports*, **5**(1): 36-38.
- Deng L, Zhu J, Xu J, Guo S, Liu S, Song Y (2018). Clinical presentation and surgical treatment of primary pulmonary artery sarcoma. *Interactive Cardiovascular and Thoracic Surgery*, **26**(2): 243-247.
- Nakrani R, Yeung HM, Kim JS, Kamat B, Kumaran M (2020) Pulmonary artery intimal sarcoma: a diagnostic challenge using a multimodal approach. *Case Reports in Medicine*, **2020**: 6795272.
- Jimbo N, Komatsu M, Itoh T, Hirose T (2019) MDM2 dual-color in situ hybridization (DISH) aids the diagnosis of intimal sarcomas. *Cardiovascular Pathology*, **43**: 107142.
- Conte GA, Alidoost M, Devita MS, et al. (2020) Diagnostic enigma: spindle cell sarcoma of the aorta presenting as pulmonary embolism and chronic anaemia. *Eur J Case Rep Intern Med*, **7**(12): 1832.
- Roszik J, Khan A, Conley AP, et al. (2019) Unique aberrations in intimal sarcoma identified by next-generation sequencing as potential therapy targets. *Cancers*, **11**(9):1283.
- Shao N and Deng C (2022) Pulmonary thromboembolic disease or pulmonary artery intimal sarcoma: Case report and literature review. *Oncology Letters*, **24**(4): 350.
- Chappell T, Creech CB, Parra D, Strauss A, Scholl F, Whitney G (2008) Presentation of pulmonary artery intimal sarcoma in an infant with a history of neonatal valvular pulmonic stenosis. *Annals of Thoracic Surgery*, **85**(3): 1092-1094.
- Lu P and Yin BB (2020) Misdiagnosis of primary intimal sarcoma of the pulmonary artery as chronic pulmonary embolism: A case report. *World Journal of Clinical Cases*, **8**(5): 986-994.
- Cox JE, Chiles C, Aquino SL, Savage P, Oaks T (1997) Pulmonary artery sarcomas: a review of clinical and radiologic features. *Journal of Computer Assisted Tomography*, **21**(5): 750-755.
- Hieu NL, Tu VN, Hoan L, et al. (2022) A case report of primary pulmonary artery intimal sarcoma. *Radiol Case Rep*, **17**(6): 1986-1990.
- Chang DY, Lin KC, Pan JY, Liu HW, Kuo SH, Lee L (2020) Pulmonary artery intimal sarcoma: a case report and literature review. *Respirology Case Reports*, **8**(2): e00530.
- Assi T, Kattan J, Rassy E, et al. (2020) A comprehensive review on the diagnosis and management of intimal sarcoma of the pulmonary artery. *Critical Reviews in Oncology Hematology*, **147**: 102889.
- Keel SB, Bacha E, Mark EJ, Nielsen GP, Rosenberg AE (1999) Prima-

- ry pulmonary sarcoma: a clinicopathologic study of 26 cases. *Modern Pathology*, **12**(12): 1124-1131.
19. Koo N, Sharma AK, Narayan S (2022) Therapeutics Targeting p53-MDM2 interaction to induce cancer cell death. *International Journal of Molecular Sciences*, **23**(9):5005.
20. Bode-Lesniewska B, Zhao J, Speel EJ, et al. (2001) Gains of 12q13-14 and overexpression of mdm2 are frequent findings in intimal sarcomas of the pulmonary artery. *Virchows Archiv*, **438**(1): 57-65.
21. Vasuri F, Resta L, Fittipaldi S, Malvi D, Pasquinelli G (2012) RUNX-1 and CD44 as markers of resident stem cell derivation in undifferentiated intimal sarcoma of pulmonary artery. *Histopathology*, **61**(4): 737-743.
22. Barmpas A, Giannakidis D, Fyntanidou V, et al. (2019) Intimal sarcoma of the pulmonary artery, a diagnostic enigma. *Ame Case Reports*, **3**: 32.
23. Attina D, Niro F, Tchouante P, et al. (2013) Pulmonary artery intimal sarcoma. Problems in the differential diagnosis. *Radiologia Medica*, **118**(8): 1259-1268.
24. Jiang W, Liu M, Guo X, et al. (2023) Echocardiographic Characteristics of pulmonary artery intimal sarcoma: Comparison with CTPA. *Heart Lung and Circulation*, **32**(9): 1080-1088.
25. Suto H, Suto M, Inui Y, Okamura A (2022) Difficulty in distinguishing pulmonary arterial intimal sarcoma from pulmonary thromboembolism using FDG PET/CT. *In Vivo*, **36**(3): 1519-1522.