

Ultrasound measurement of sheath nerve diameter for guided drug therapy for severe craniocerebral injury

Y. Fan^{1*}, J. Niu², Q. Lu¹

¹Department of Critical Care Medicine, Shaoxing Second Hospital

²Department of Critical Care Medicine, The First Affiliated Hospital, Medical College, Zhejiang University

ABSTRACT

► Short report

*Corresponding author:

Yaoqun Fan, M.b.,

E-mail:

FanYaoq998@hotmail.com

Received: December 2024

Final revised: June 2025

Accepted: June 2025

Int. J. Radiat. Res., October 2025;
23(4): 1119-1123

DOI: 10.61186/ijrr.23.4.40

Keywords: Severe traumatic brain injury, ultrasound measurement, optic nerve sheath diameter, neurogenic markers, functional recovery.

Background: Severe traumatic brain injured (STBI) is a leading reason for death and long-term disabilities, and improved real-time management of intracranial pressure (ICP) is necessary. This study evaluated the efficacy of drug therapy with ultrasound-guided in patients with STBI by measuring optic nerves sheath diameters (ONSD). **Materials and Methods:** This retrospective case-control study involved 263 patients with STBI who were treated between March 2019 and June 2021. Patients were categorized in an ultrasound group (n=125), which received ONSD-guided therapy, and a regular group (n=138), which received conventional treatment. Neurogenic and inflammatory markers, clinical scales, and functional recovery metrics were assessed. **Results:** The ultrasound group showed remarkably improved early-treatment outcomes, such as decreased abnormal breathing (27.20% vs. 40.58%, $P=0.022$) and lower ICP (54.40% < 350 mmHg vs. 40.58%, $P=0.025$). This group also showed increased neurogenic factors (brain-derived neurotrophic factors (BDNF) and nerve growth factors (NGF)) and notable decreases in inflammatory indicators like tumor necrosis factor α (TNF- α) ($P<0.05$). Post-treatment neurological scores were better in the ultrasound group (National Institutes of Health Stroke Scale (NIHSS): 18.32 vs. 18.96 ($P=0.018$); Glasgow Coma Scale (GCS): 11.19 vs. 10.54 ($P=0.007$)). Functional assessments (Fugl-Meyer Assessment (FMA), Berg Balance Scale (BBS), Modified Barthel Index (MBI)) and quality of life (Simplified Form of Health Questionnaire-36 (SF-36)) indices also favored the ultrasound group. **Conclusion:** Ultrasound-guided ONSD measurement enhances real-time ICP management in drug therapy for patients with STBI. The measurement has positive effects on neurogenic and inflammatory profiles, functional recoveries, and quality of life.

INTRODUCTION

Traumatic brain injury (TBI) is posing a major challenge to global health, with severe cases resulting in high mortality and long-term disability ⁽¹⁾. TBI contributes to approximately 2.87 million emergency visits, hospitalizations, and deaths annually in the United States alone ⁽²⁾. Effective management of severe TBI (STBI) is critical, often involving intracranial pressure (ICP) reduction and neuroprotective therapies ^(3, 4). However, traditional ICP monitoring is invasive and may lack real-time assessment capabilities ⁽⁵⁾.

Recent advancements have positioned ultrasound to a valuable noninvasive instrument for neurological assessments, with optic nerve sheath diameter (ONSD) serving as a promising indicator of ICP fluctuations ^(6, 7). This study investigates the integration of ultrasound-guided ONSD measurement into the treatment regimen for STBI, assessing its impact on clinical outcomes, neurobiological markers, and functional recovery ⁽⁸⁾. Although ONSD has been recognized as a reliable marker for elevated ICP ⁽⁹⁾, its routine application in STBI management remains underexplored ⁽¹⁰⁾.

This study evaluated the impact of integrating ultrasound measurement of ONSD into the therapeutic regimen for patients with STBI. The measurement method was combined with pharmacological treatment for the first time, and the value of this combination in the treatment with STBI patients was explored. We compared the clinical outcomes, neurobiological markers, and functional recovery between an ultrasound group and a conventional treatment group to clarify the potential advantages of this approach in improving the prognosis.

MATERIALS AND METHODS

Case selection

This retrospective controlled study included 263 patients with STBI who were treated at our hospital between March 2019 and June 2021. Patient information was systematically collected, including general characteristics, vital signs, expression levels of relevant factors, and scores on pertinent scales. This study adhered to all applicable regulatory and ethical guidelines for retrospective research and

received approval from the ethics committee of Shaoxing Second Hospital (YK-20180902).

Inclusion criteria, grouping, and treatment methods

Inclusion criteria for the study were a diagnosis of STBI, coma lasting more than 6 hours, medical attention being sought within 24 hours of injury, age between 18 and 65 years, and availability of complete medical records. The exclusion criteria were any other serious illnesses, such as heart, liver, or kidney damage; previous ophthalmic conditions, including optic neuritis or optic nerve tumors; a history of cerebrovascular disease; and allergies to relevant medications.

Patients were categorized in two groups according to the treatment modality. The ultrasound group comprised 125 patients who received medication treatment guided by ultrasound measurement of the ONSD, as well as conventional treatment. The regular group consisted of 138 patients and received only conventional treatment. The mean ages were similar between groups (42.13 ± 3.62 years in the ultrasound group vs. 42.26 ± 3.54 years in regular group; $P = 0.780$). The sex distributions were nearly identical ($P = 0.846$), with males comprising 35.20% of the ultrasound group (44 males and 81 females) and 34.06% of the regular group (47 males and 91 females).

Conventional therapy involved procedures such as removing intracranial hematomas, reducing ICP, protecting brain tissue, and enhancing brain nerve nutrition. For ultrasonographic (2D) measurement of the ONSD (figure 1), the patient was positioned supine with the head at the midline. Patients were instructed to gently close both eyes, which were then protected with disposable transparent patches. Ultrasound transmission gel (Guanggong Brand, Guangzhou Guanggong Technology Development Co., LTD, China) was applied evenly to both the eyes and the ultrasound probe.

A 9-MHz ultrasound probe (Mindray M58, Shenzhen Huasheng Medical Technology Co., LTD, China) was gently positioned above the eyeballs while ensuring minimal pressure on them. The optic nerve sheath was examined and measured 3 mm behind the transverse diameter of both eyes. Three ONSD measurements were taken for each eye, and the average value was recorded with an accuracy of 0.1 mm. All images were stored in both DICOM and JPEG formats.

Glasgow coma scale (GCS)

The GCS is used extensively to assess the severity of TBI. It measures consciousness on a 3 to 15-point scale based on eye opening, verbal, and motor responses. Lower scores indicate more severe injury and worse prognosis. Scores are categorized as follows: 3–8: STBI; 9–12: moderate TBI; and 13–15:

mild TBI. The GCS is simple, reliable (Cronbach's $\alpha=0.850$), and internationally recognized ⁽¹¹⁾.

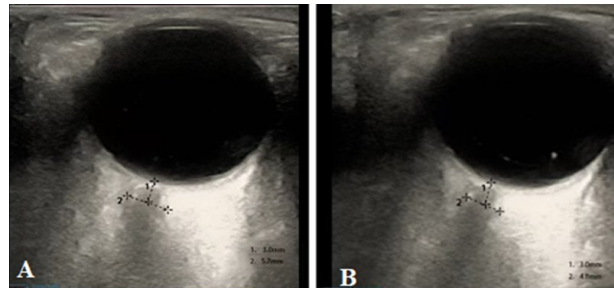


Figure 1. Ultrasonic (2D) Measurement of Neural Diameter in Patients with Severe Traumatic Brain Injury.

Note: The optical nerves sheath is a continuum of the intracranial dura mater and sub-arachnoid spaces, and an increase in intracranial pressure will directly increase optical nerves sheath's diameter. The measurement is mainly taken at 3 mm behind the eyeball, as this area has the greatest elasticity and elasticity with changes in intracranial pressure. 1: Distance behind the eyeball, 2: optic nerve sheath diameter; A: Before Treatment; B: After Treatment.

Fugl-Meyer assessment (FMA) scale

Patients' walking function was evaluated using the FMA. The evaluation included 50 programs related to the upper limbs, and each item is scored between 0 and 2 points, resulting in total maximum of 100 points. Lower scores indicate poorer walking function. High reliability was demonstrated by FMA with Cronbach's $\alpha = 0.924$ ⁽¹²⁾.

Berg balance scale (BBS)

The BBS assesses posture controls and balancing abilities. It comprises 14 items scored as 0 (unable) to 4 (successful), with the maximum score being 56, with higher scores indicating better balancing abilities. The BBS has demonstrated excellent reliability (Cronbach's $\alpha = 0.970$) ⁽¹³⁾.

Modified Barthel index (MBI)

We used the MBI to evaluate patients' activities of everyday living. This scale includes 10 items, which each contribute to a total possible score of 100 points. The items evaluate competencies such as eating, washing, using the toilet, dressing, and controlling urination and defecation. A score of 40 or below signifies an inability to care for oneself, scores between 41 and 59 indicate partial self-care, and scores of 60 or above reflect basic self-care abilities. Higher scores correspond to greater independence in daily activities. The scale exhibits strong reliability with Cronbach's α of 0.900 ⁽¹⁴⁾.

Simplified form of health questionnaire-36 (SF-36)

The SF-36 questionnaires were used to evaluate patients' life quality. This scale evaluates various dimensions of quality of life, including social function, self-management, mental health, and physical functioning. The higher the score, the better the life quality. SF-36 showed good reliability and Cronbach's α of 0.814 ⁽¹⁵⁾.

Statistical analyses

Detailed statistical analysis was conducted by SPSS 29.0. Categorical variable were expressed as frequency and percentage and analyzed by chi-square test or Fisher's exact test as appropriate. Continuous variable was evaluated for normal distribution; otherwise, appropriate non-parametric tests were used. A P -value < 0.05 indicated statistically significance difference.

RESULTS

Neurogenic and inflammatory factor levels after 24 hours

The ultrasound group had a higher BDNF level of 21.16 ± 3.15 pg/mL compared to the value of 20.23 ± 3.16 pg/mL in regular group ($P=0.018$) (figure 2). NGF levels were also remarkably elevated in the ultrasound group (18.74 ± 2.26 pg/mL) relative to regular group (18.02 ± 2.11 pg/mL; $P=0.008$). Furthermore, the ultrasound group demonstrated a lower mean level of hypersensitive C-reactive protein (hs-CRP) at 10.91 ± 1.23 μ g/mL compared to 11.37 ± 1.25 μ g/mL in regular group ($P=0.003$).

Tumor necrosis factor- α (TNF- α) levels were remarkably reduced in ultrasound group (13.52 ± 1.67 ng/mL vs. 14.31 ± 3.36 ng/mL, $P=0.015$). The interleukin-6 (IL-6) concentrations were also lower in the ultrasound group with an average of 22.68 ± 2.99 ng/mL compared to 23.56 ± 3.16 ng/mL in regular group ($P=0.022$). These findings indicate that ultrasound-guided drug therapy may enhance neurogenic factors while reducing inflammatory markers in patients with STBI.

GCS scores before and after treatment

The GCS scores were compared to determine the effects of the proposed treatment (figure 3). Before treatment, no remarkable discrepancy was found in GCS scores of ultrasound group and regular group (6.45 ± 1.28 vs. 6.37 ± 1.33 ; $P=0.622$). However, post-treatment GCS scores were remarkably higher in the ultrasound group (11.19 ± 1.89) relative to regular group (10.54 ± 2.01 ; $P=0.007$), indicating enhanced recovery of consciousness. These results suggest a potential benefit of ultrasound-guided drug therapy in improving neurological outcomes in this patient population.

Analysis of FMA and BBS scores

We used the FMA and the BBS to evaluate the functional and balance outcomes post-treatment (figure 4). Baseline assessments showed no remarkable discrepancy of ultrasound group and regular group. Their FMA scores were 37.06 ± 5.42 and 37.15 ± 5.16 ($P=0.887$), while their BBS scores were 8.53 ± 2.65 and 8.64 ± 3.10 ($P=0.758$), respectively. Remarkable improved in both

assessments were observed after treatment. The ultrasound group demonstrated a greater enhancement in motor function, as indicated by a higher post-treatment FMA score of 80.65 ± 4.96 , whereas 79.36 ± 4.47 was obtained in the regular group ($P=0.028$). Similarly, balance performance measured by the BBS were remarkably higher in ultrasound group with post-treatment scores of 26.26 ± 3.65 versus 25.15 ± 3.31 in regular group ($P=0.010$). These findings suggest that incorporating ultrasound-guided drug therapy may lead to better recovery of motor function and balance.

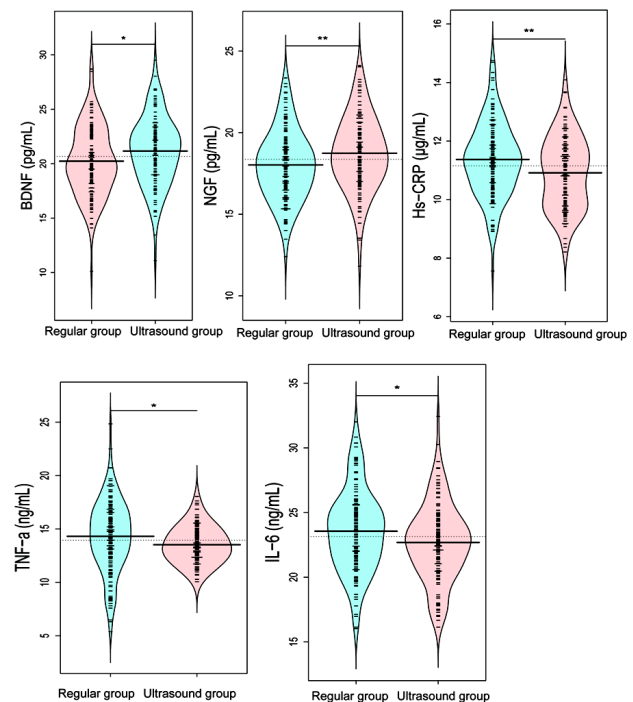


Figure 2. Neurogenic and inflammatory factors level after 24 hours.

Note: BDNF: Brain-Derived Neurotrophic Factors; NGF: Nerve Growth Factors; Hs-CRP: Hypersensitive C-Reactive Proteins; TNF- α : Tumor Necrosis Factor- α ; IL-6: Interleukin-6. A: BDNF 24 h after treatment; B: NGF after 24 h of treatment; C: Hs-CRP after 24 h of treatment; D: TNF- α after 24 h of treatment; E: IL-6 after 24 h of treatment. "*" indicates $P<0.05$, "**" indicates $P<0.01$.

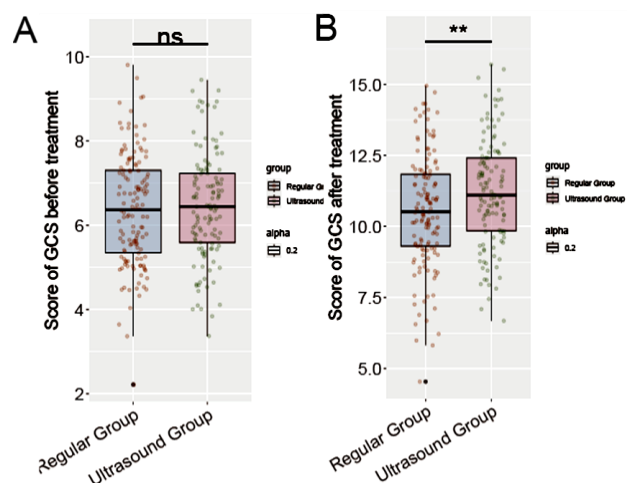


Figure 3. GCS scale assesses the neurological status of patients with TBI before and after treatment.

Note: A: Comparison of GCS scale scores before treatment; B: no remarkable discrepancy in ns in GCS scale scores after treatment; "*" indicates $P<0.01$.

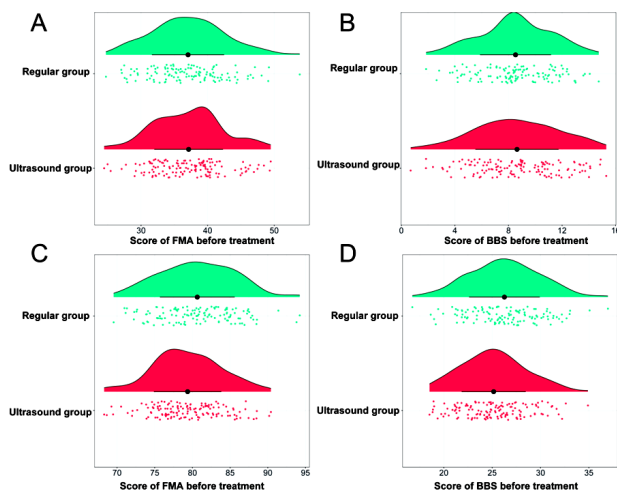


Figure 4. FMA and BBS. Note: FMA: functional motor skills; BBS: berg balance scale.

Analysis of MBI and SF-36 scores

The MBI and SF-36 results are shown in table 1. The baseline scores showed no remarkable discrepancy of ultrasound and regular group with MBI scores of 26.31 ± 4.13 and 26.29 ± 3.98 ($P=0.965$) and SF-36 scores of 22.16 ± 3.67 and 22.08 ± 4.12 ($P=0.865$), respectively. After treatment, both groups exhibited significant improvements, but those of the ultrasound group were higher. The MBI score in the ultrasound group was remarkably higher, indicating greater functional independence (61.36 ± 3.46 compared to 60.24 ± 4.09 in regular group; $P=0.018$). Similarly, the SF-36 score indicated more enhanced quality of life at 61.38 ± 4.25 in ultrasound group compared to 60.32 ± 3.85 in regular group ($P=0.035$). These results suggest that ultrasound-guided drug therapy was related to improved functional independence and life quality in patients with STBI.

Table 1. MBI and SF-36.

Parameters	Ultrasound Group (n = 125)	Regular Group (n = 138)	t	P
Score of MBI before treatment	26.31 ± 4.13	26.29 ± 3.98	0.044	0.965
Score of Sf-36 before treatment	22.16 ± 3.67	22.08 ± 4.12	0.17	0.865
Score of MBI after treatment	61.36 ± 3.46	60.24 ± 4.09	2.387	0.018
Score of Sf-36 after treatment	61.38 ± 4.25	60.32 ± 3.85	2.125	0.035

DISCUSSION

Recently, the management of STBI has advanced through medical imaging, particularly with ultrasound as a guiding tool in drug therapy⁽¹⁶⁾. This study examined the effects of ultrasound-guided ONSD measurements on treatment outcomes for STBI patients. Findings revealed that the ultrasound group achieved remarkably better neurological outcomes, reflected in improved Glasgow Coma Scale (GCS) scores, as well as enhanced functional motor

skills (FMA) and berg balance scale (BBS), suggesting reduced damage to motor pathways. Li *et al.* in their study of ultrasound-guided electrical stimulation on the recovery of hemiplegic upper limbs after stroke also reported marked improvement in the FMA index after treatment, which is consistent with that reported in present study⁽¹⁷⁾.

Ultrasound-guided ONSD measurements effectively monitor intracranial pressure (ICP) and serve as a screening tool for increased ICP^(18, 19). The ultrasound group showed elevated levels of BDNF and NGF, which are vital for neuronal survival and repair, indicating a favorable neurochemical environment linked to improved ICP management. Additionally, decreased levels of inflammatory indicators such as hs-CRP, TNF- α , and IL-6 in ultrasound group suggest that better ICP control mitigates inflammatory responses, further enhancing outcomes. In a study, Liu *et al.* analyzed the efficacy of ultrasound-guided erector spinae plane block (ESPB) as postoperative analgesia after single-port VATS and demonstrated remarkably decreased levels of inflammatory factors in ultrasound group, which is similar to the results of this study⁽²⁰⁾.

Despite these promising results, optimal integration of ultrasound-guided therapy in clinical practice requires further investigation into the frequency of ONSD measurement, intervention thresholds, and the medications that benefit most. Advancements in automated ultrasound measurement and interpretation could improve feasibility and accuracy. Moreover, effective TBI management necessitates multidisciplinary collaboration and staff education on ONSD interpretation to facilitate widespread adoption. Future research should investigate personalized treatment protocols considering individual variations in ICP response to optimize patient outcomes.

CONCLUSION

Ultrasound-guided measurement of ONSD remarkably enhanced drug therapy for STBI. Furthermore, it improved management of ICP, neurogenic and inflammatory profiles, and overall patient outcomes. Ultimately, this technique could foster better functional recovery and quality of life.

Acknowledgment: None.

Consent to Publish: The manuscript has neither been previously published nor is under consideration by any other journal. The authors have all approved the content of the paper.

Consent to Participate: This retrospective study utilized de-identified patient data, posing no risk to patient care. Consequently, the requirement for informed consent was waived by both the hospital's Institutional Review Board and ethics committee.

Ethic Approval: This study was approved by the ethics committee of Shaoxing Second Hospital (YK-20180902).

Author Contribution: Y.F.: Developed and planned the study, performed experiments, and interpreted results. Edited and refined the manuscript with a focus on critical intellectual contributions. J.N.: Participated in collecting, assessing, and interpreting the data. Made significant contributions to data interpretation and manuscript preparation. Q.L.: Provided substantial intellectual input during the drafting and revision of the manuscript.

Data Availability Statement: The data that support the findings of this study are available from the corresponding author, upon reasonable request.

Funding: The Value of Transcranial Doppler Ultrasound in Brain Injury (2022KZ21).

Conflicts of Interest: The authors declare that they have no financial conflicts of interest.

REFERENCES

- Visser K, Koggel M, Blaauw J, et al. (2022) Blood-based biomarkers of inflammation in mild traumatic brain injury: A systematic review. *Neurosci Biobehav Rev*, **132**: 154-168.
- Das AS, Vicenty-Padilla JC, Chua MMJ, et al. (2022) Cerebrovascular injuries in traumatic brain injury. *Clin Neurol Neurosurg*, **223**: 107479.
- Graham NS and Sharp DJ (2023) Dementia after traumatic brain injury. *BMJ*, **383**: 2065.
- Olsen CM and Corrigan JD (2022) Does Traumatic brain injury cause risky substance use or substance use disorder? *Biol Psychiatry*, **91(5)**: 421-437.
- Muehlschlegel S, Rajajee V, Wartenberg KE, et al. (2024) Guidelines for neuroprognostication in critically ill adults with moderate-severe traumatic brain injury. *Neurocrit Care*, **40(2)**: 448-476.
- Patel RH, Foltz EA, Witkowski A, et al. (2023) Analysis of artificial intelligence-based approaches applied to non-invasive imaging for early detection of melanoma: A systematic review. *Cancers*, **15(19)**: 4694.
- Soroushmehr R, Rajajee K, Williamson C, et al. (2019) Automated optic nerve sheath diameter measurement using super-pixel analysis. *Annual International Conference of the IEEE Engineering in Medicine and Biology Society IEEE*, **2019**: 2793-2796.
- Sener K, Kadir A, Altug E, et al. (2023) Is optic nerve sheath diameter diagnostic in methanol intoxication? *Alcohol (Fayettev, NY)*, **113**: 27-31.
- Cho J (2021) Ocular Ultrasound abnormalities and optic nerve sheath diameter in dogs and cats. *Vet Clin North Am Small Anim Pract*, **51(6)**: 1295-1314.
- Stevens RRF, Gommer ED, Aries MJH, et al. (2021) Optic nerve sheath diameter assessment by neurosonology: A review of methodologic discrepancies. *J Neuroimaging*, **31(5)**: 814-825.
- Sadaka F, Patel D, Lakshmanan R (2012) The FOUR score predicts outcome in patients after traumatic brain injury. *Neurocrit Care*, **16(1)**: 95-101.
- Amano S, Umeji A, Takebayashi T, et al. (2020) Clinimetric properties of the shortened Fugl-Meyer Assessment for the assessment of arm motor function in hemiparetic patients after stroke. *Top Stroke Rehabil*, **27(4)**: 290-295.
- Downs S, Marquez J, Chiarelli P (2013) The Berg Balance Scale has high intra- and inter-rater reliability but absolute reliability varies across the scale: a systematic review. *J Physiother*, **59(2)**: 93-99.
- Shah S, Vanclay F, Cooper B (1989) Improving the sensitivity of the Barthel Index for stroke rehabilitation. *J Clin Epidemiol*, **42(8)**: 703-709.
- Wu Q, Chen Y, Zhou Y, et al. (2023) Reliability, validity, and sensitivity of short-form 36 health survey (SF-36) in patients with sick sinus syndrome. *Medicine*, **102(24)**: e33979.
- Schepici G, Silvestro S, Bramanti P, et al. (2020) Traumatic brain injury and stem cells: an overview of clinical trials, the current treatments and future therapeutic approaches. *Medicina (Kaunas)*, **56(3)**: 137.
- Li R, Zhang P, Lu J, et al. (2023) Case report: Ultrasound-guided median nerve electrical stimulation on functional recovery of hemiplegic upper limb after stroke. *Front Neurol*, **14**: 1244192.
- Kerscher SR, Zipfel J, Haas-Lude K, et al. (2024) Ultrasound-guided initial diagnosis and follow-up of pediatric idiopathic intracranial hypertension. *Pediatr Radiology*, **54(6)**: 1001-1011.
- Lioi F, Ramm-Petersen J, Fratini A, et al. (2024) Ultrasonographic assessment of optic nerve sheath diameter as a screening tool for intracranial hypertension in traumatic brain injury. *World Neurosurg*, **192**: e42-e48.
- Liu L, Ni Xx, Zhang Lw, et al. (2021) Effects of ultrasound-guided erector spinae plane block on postoperative analgesia and plasma cytokine levels after uniportal VATS: a prospective randomized controlled trial. *J Anesth*, **35**: 3-9.

