

# Umbelliferone as a promising protective agent in rat kidney against high dose post-irradiation injury; biochemical, immunohistochemical and histopathological evaluations

F. Geyikoglu<sup>1</sup>, G.Y. Deniz<sup>2\*</sup>, M.N.G. Demir<sup>1</sup>, M. Arslan<sup>1</sup>, B. Erdemci<sup>3</sup>

<sup>1</sup>Faculty of Sciences, Biology Department, Atatürk University, 25240 Erzurum, Turkey

<sup>2</sup>Vocational School of Health Services, Ataturk University, 25240 Erzurum, Turkey

<sup>3</sup>Faculty of Medicine, Radiation Oncology Department, Ataturk University, Erzurum, Turkey

## ABSTRACT

### ► Original article

#### \*Corresponding author:

Gulsah Yildiz Deniz, Ph.D.,

#### E-mail:

[gulsah.ydeniz@gmail.com](mailto:gulsah.ydeniz@gmail.com)

Received: October 2023

Final revised: July 2025

Accepted: July 2025

Int. J. Radiat. Res., January 2026;  
24(1): 115-122

DOI: 10.61186/ijrr.24.1.18

**Keywords:** 8-hydroxy-2'-deoxyguanosine (8-OHdG) DNA damage, ionizing radiation, renal dysfunction injury, umbelliferone, thromboxane B2 (TxB2) Vascular injury.

**Background:** Irradiation at the high dose may attenuate renal hemodynamics while retaining the therapeutic effect on cancer cells and thus can life-threatening. Hence the effects on kidneys of irradiation become increasingly crucial. This study aimed to examine oxidative stress, inflammatory response, vascular injury, apoptotic and deoxyribonucleic acid (DNA) DNA damage induced acute high dose ionizing radiation in rat kidney and to investigate whether umbelliferone (UMB) has protective effect on radiation-induced renal damage and dysfunction. **Materials and Methods:** Rats were randomly allocated into eight groups (n = 7): the control group, given physiological saline; the model group, exposed radiation (whole body irradiated with single high dose of 12 Gy of gamma rays) to induce radiation damage in renal tissue; UMB groups, received UMB (30, 60 and 90 mg/kg) alone and treatment groups received orally UMB for 5 days before radiation exposure. Animals were divided groups; control, group whole body irradiated with single dose 12 Gy, groups receiving umbelliferone alone and groups receiving umbelliferone for 5 days before irradiated. **Results:** Radiation-induced pathological findings and functional disorders were significantly ameliorated in UMB umbelliferone-treated groups. Our results revealed that umbelliferone pretreatment in the kidney plays an important role in the regulation of blood pressure in irradiation-induced renal injury. UMB increases the antioxidant activity and decreases inflammatory response in kidney tissue against radiation toxicity. Notably, it exhibits anti-apoptotic and anti-genotoxic actions in damaged renal cells. It also ameliorates the blood urea nitrogen (BUN) and creatinine values. **Conclusion:** In conclusion, UMB umbelliferone from coumarin compounds is a targeted and promising drug to prevent kidney necrosis and dysfunction due to radiation therapy.

## INTRODUCTION

Cancer is a major public health problem of the 21st century. Cancer treatment requires multidisciplinary approaches as surgery, radiotherapy, and chemotherapy. Surgery was the most curative therapy for nonmetastatic solid tumors. Chemotherapy is used successfully in some categories of cancer <sup>(1)</sup>. Although history of radiotherapy is relatively short, its role is great in the survival for cancer patients <sup>(2)</sup>. However, radiation therapy has also been associated with development of metabolic syndromes, which may lead to serious complications such as blindness, renal failure, impairment in lung function, liver injury, neuropathy, cardiac damage and atherosclerosis <sup>(3-7)</sup>. Radiation-induced kidney injury is closely related to oxidative stress, inflammatory responses, glomerular vasculopathy, and necroptosis <sup>(8, 9)</sup>. Renal oxidative stress is a critical mechanism and anti-oxidant agents have been reported to protect against radiation-induced kidney injury <sup>(10)</sup>. Therefore, anti-oxidant

agents may be a possible effective therapeutic method for diminish radiotherapy-related morbidity and mortality <sup>(11)</sup>.

In recent years, numerous pharmacologically active plant constituents have been investigated against radiation injury. These active compounds can selectively protect normal tissues and also allow use of higher radiation doses to obtain possible therapy. Among the most studied natural substances that have proven radioprotective activity are flavones, flavonoids, polyphenols and tannins <sup>(12, 13)</sup>. The exposure to radiation has a powerful impact on DNA (base lesions and strand breaks) and proteins by lipid peroxidation. Mechanistic studies have showed that antioxidant properties, free radical scavenging ability and anti-inflammatory effects may prove important contributors for observed protection <sup>(14, 15)</sup>. Coumarins are biologically active compounds including antioxidant, anti-inflammatory, analgesic, antimicrobial and antitumor activities <sup>(16)</sup>. Coumarin compounds passively penetrate biomembranes after oral administration, and are distributed throughout

the body from the gastrointestinal tract<sup>(17)</sup>. Indeed, these compounds are promising candidates in drug discovery processes. UMB is a coumaric compound which widespread occurrence in numerous plants. Although its mechanism of action is not entirely known, there are several hypotheses explaining its role<sup>(18)</sup>. The most widely accepted hypothesis is the antioxidant property of UMB. UMB could ameliorate myocardial ischemia reperfusion injury<sup>(19)</sup>. UMB also exhibited protective effects against liver injury<sup>(20)</sup>, and alleviated diabetic nephropathy by inhibiting inflammatory response<sup>(21)</sup>. Radiation exposure can be cause acute and irreversible renal injury with a progressive dysfunction over years<sup>(22)</sup>. To our knowledge, the current study is the first to investigate the therapeutic effects of UMB on radiation-induced kidney injury in rats. The aim of the present study was determine whether UMB pretreatment attenuates radiation-induced kidney injury. Here, we also focused to explore the underlying mechanisms of UMB action. Thus, our study exhibits novel therapeutic metabolic activities of UMB in the kidney, which point to the potential use of its against renal injury associated with radiation.

## MATERIAL AND METHODS

### UMB and chemicals

UMB (purity  $\geq 98\%$ ) was procured from Sigma-Aldrich Chemical Co. (MO, USA) and was used as test compound. TXB2 and tumor necrosis factor alpha (TNF- $\alpha$ ) ELISA kits were purchased from SunRed Biotech Co., China. BAX and 8-OHdG were obtained from Cell Signaling Technology (Danvers, MA, USA). Total antioxidant capacity (TAC) (Randox, UK), total oxidative stress (TOS) commercial kits (Rel Assay Diagnostics Mega Tip, Gaziantep, Turkey) and formic acid were purchased from Damao Chemical Reagent Factory (Tianjin, China).

### Animals and experimental design

Fifty six male Sprague Dawley rats (weighing 280-300 g) were provided by the Laboratory Animal Center of Atatürk University. Animals were housed in an air-conditioned room ( $25 \pm 1$  °C) with 12-h day/night cycle. 12-h light-dark cycle. Standard rat feed and water were provided ad libitum. The experimental studies were approved by Local Ethical Committee of Atatürk University, Erzurum, Turkey (permission No. 263, 26.12.2019-. 30.2.ATA.0.23.85-11) and were conducted according to the U.S. National Institutes of Health (NIH) Guide for the Care and Use of Lab animals.

Rats were randomly allocated into eight groups (n = 7): the control group, given physiological saline; the model group, exposed radiation (whole body irradiated with single high dose of 12 Gy of gamma rays)<sup>(23)</sup>, to induce radiation damage in renal tissue; UMB groups, received UMB (30, 60 and 90 mg/kg)

alone and treatment groups, received orally UMB for 5 days before radiation exposure. The doses of UMB were selected according to the literature data<sup>(21)</sup>. However, the main pharmacokinetic parameters, were estimated through a noncompartmental method by using the Drug and Statistics 2.0 (DAS 2.0) software package (Mathematical Pharmacology Professional Committee of China, Shanghai, China).

### Ionizing radiation exposure

Rats were irradiated as previously described by investigators (Sproull *et al.* 2017, A Theratron 780-C source (AECL, Ontario, Canada) at a dose rate of 0.78 Gy/min was used to deliver a single 12 Gy dose to total-body. The applications were performed in Department of Radiotherapy, Atatürk University Medical College Hospital, Erzurum, Turkey. The exposure set up was calibrated by physical measurement using a tissue-equivalent ionizing chamber. The homogeneous irradiated field was  $30 \times 30$  cm, and the field was uniform within 1%. In the process of exposure to radiation, each rat was confined to a ventilated circular holder to minimize its activity so the whole body could receive the uniform radiation dose.

### Biochemical analyses

**TAC and TOS measurements:** The measurements of TAC and TOS were determined using commercially available assay kits. For TAC levels, rat kidney tissues were homogenized using an homogenizer (IKA, Wilmington, USA). Then tissue homogenates were added to a mixture of Fe-EDTA and H<sub>2</sub>O<sub>2</sub> (10 mmol/L) for 60 min.

**Estimation of TNF- $\alpha$  and TXB2:** Rat kidneys were weighed (approximately 2 g) and immediately transferred to  $-80$  °C. Thereafter, brain samples were homogenized into phosphate buffered saline (PBS) and centrifuged at 10,000g, 4 °C for 10 min. The supernatants (40  $\mu$ l) were collected and immediately transferred to  $-80$  °C for further determination. ELISA kits were used to measure the levels of TNF- $\alpha$  and TXB2 according to the manufacturer's instructions.

**Estimation of BUN and creatine levels:** BUN and creatinine levels in serum were estimated by using biochemical automatic detector (HITACHI 7600-020 Japan).

### Histopathological studies

The renal tissues of rats were fixed in buffered 10% formalin solution for 48 h and embedded in a paraffin wax. Tissues were then sectioned at 5- $\mu$ m and stained with hematoxylin eosin (H & E), Periodic acid Schiff (PAS) and Congo red methods.

Tissue samples were evaluated by a single experienced pathologist in a blinded fashion. For each kidney section corresponding blocks of H&E, whole slide was examined for histopathological evaluation under bright field using an Olympus BX60

microscope equipped with a charge-coupled device (CCD) CCD. In addition, high-resolution pictures ( $\times 200$ ) of samples were taken under the same microscope.

### Immunological examinations

B-cell lymphoma 2 (Bcl-2) associated X protein (BAX) and 8-OHdG expressions in the kidney specimens were detected by specific monoclonal antibodies. The tissue sections (at 5  $\mu\text{m}$  thickness) were deparaffinized and dehydrated with graded ethanol solutions. The sections were then blocked using hydrogen peroxide and blocking serum. Immunohistochemical stainings were performed using BAX (Santa Cruz; diluted 1:250 with diluent buffer) and 8-OHdG antibodies (Santa Cruz; 1:2500 dilution) with Novolink Polymer Detection kits (Leica Microsystems Pte Ltd., Taipei, Taiwan), following the manufacturer's instructions. Diaminobenzidine was applied as chromogen and slides were counterstained with Mayer's hematoxylin (24).

### Statistical analysis

Data analysis of biochemical parameters was performed using a one-way analysis of variance (ANOVA) test by Graphpad prism 5.0 statistics software (GraphPad, La Jolla, CA, USA). Tukey's test was used as a post hoc. The non-parametric Kruskal-Wallis test was used to analyze variations among data obtained using the semi-quantitative method at histopathological examination. Analyses between the two groups were performed using the Mann-Whitney U test.  $p < 0.05$  was regarded as statistically significant.

## RESULTS

TAC, TOS, TNF- $\alpha$  and TBX2 levels in renal tissue are summarized according to groups in table 1. There were no significant differences between control and UMB groups. However, the group exposition to radiation compared with the control group showed an increase in the level of TOS and a significant decrease in the TAC level ( $P < 0.05$ ), thus indicating an impairment in the oxidative balance in the kidney tissue. We also determined the anti-inflammatory activity of UMB by measuring the content of TNF- $\alpha$ . While the level of TNF- $\alpha$  was significantly up-regulated in the radiation-exposed group, the group pretreated with UMB showed a marked down-regulation of TNF- $\alpha$  in the kidney homogenate. Moreover, the TBX2 level were significantly higher in radiation group than in the other seven groups, indicating an increase in vascular injury in irradiated group ( $p < 0.05$ ). The rats treated with UMB showed restoration of these levels to the control levels.

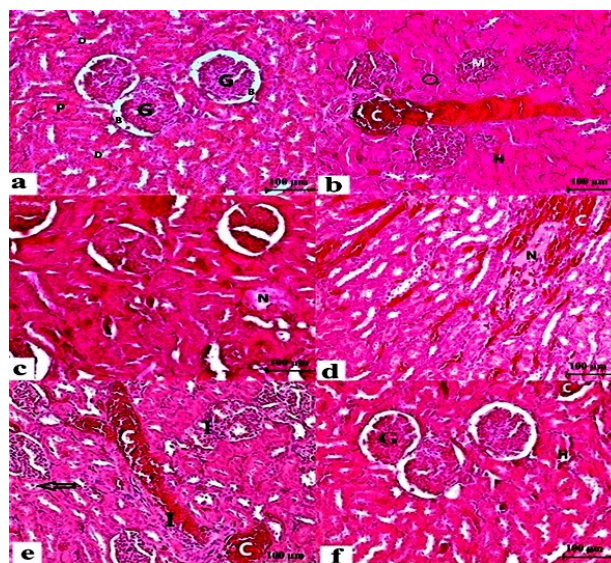
An in-depth characterization of renal pathology in irradiated rats, selected images of different methods-

stained kidney sections are presented in figures 1, 2 and 3. H&E staining demonstrated that the tissue sections of the control group exhibited their general characteristic shape. In the radiation-exposed group, the structure of renal tissue was severely damaged with congestion, infiltration, hemorrhage, apoptosis, mesenchymal matrix increase, and hydropic degenerations and even necrosis. By contrast, the pretreatment of UMB (90 mg/kg) significantly ameliorated pathologic alterations of kidneys in irradiated animals (data not shown at 30 and 60 mg/kg) (figure 1a-f).

**Table 1.** The effects of UMB on levels of TAC, TOS, TNF- $\alpha$  and TBX2 in radiation-induced kidney injury.

Groups	TAC (mmol Trolox Equiv./L)	TOS ( $\mu\text{mol H}_2\text{O}_2$ Equiv./L)	TNF- $\alpha$ (pg/mg doku)	TBX2 (Pg/ml)
Control	8.96 $\pm$ 0.79	6.01 $\pm$ 0.28	4.90 $\pm$ 0.31	430 $\pm$ 20
Rad (12 Gy)	4.90 $\pm$ 0.11 <sup>a</sup>	9.12 $\pm$ 0.01 <sup>a</sup>	7.32 $\pm$ 0.28 <sup>a</sup>	650 $\pm$ 15 <sup>a</sup>
Umb (L)	9.19 $\pm$ 0.12 <sup>b</sup>	6.15 $\pm$ 0.06 <sup>b</sup>	4.83 $\pm$ 0.12 <sup>b</sup>	415 $\pm$ 20
Umb (M)	9.28 $\pm$ 0.28 <sup>b</sup>	6.12 $\pm$ 0.10 <sup>b</sup>	4.80 $\pm$ 0.06 <sup>b</sup>	412 $\pm$ 14
Umb (H)	9.44 $\pm$ 0.11 <sup>b</sup>	6.06 $\pm$ 0.20 <sup>b</sup>	4.84 $\pm$ 0.13 <sup>b</sup>	408 $\pm$ 7
Umb (L)+Rad	5.82 $\pm$ 0.18 <sup>a,b,c</sup>	5.81 $\pm$ 0.05 <sup>a,b,c</sup>	6.11 $\pm$ 0.17 <sup>a,b,c</sup>	600 $\pm$ 12 <sup>a,b</sup>
Umb (M)+Rad	6.66 $\pm$ 0.16 <sup>a,b,c</sup>	5.53 $\pm$ 0.07 <sup>a,b,c</sup>	5.39 $\pm$ 0.19 <sup>a,b,c</sup>	500 $\pm$ 17 <sup>a,b,c</sup>
Umb (H)+Rad	8.58 $\pm$ 0.21 <sup>b,c,d</sup>	5.99 $\pm$ 0.01 <sup>b,c,d</sup>	4.85 $\pm$ 0.09 <sup>b,c,d</sup>	470 $\pm$ 11 <sup>a,b,c,d</sup>

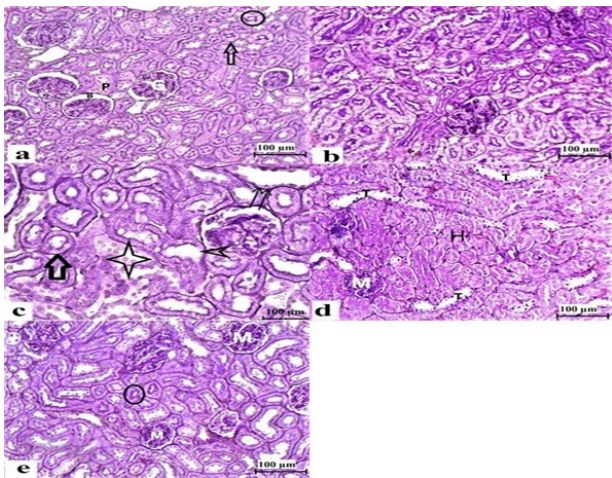
Data are presented as means  $\pm$  SD (n=7). a,b,c,d The groups in the same column with different letters are statistically significant ( $p < 0.05$ ). Abbreviation used: Rad: Radiation, Umb (L): 30 mg/kg, Umb (M): Umb (H): 90 mg/kg umbelliferone TAC: Total antioxidant capacity, TOS: Total oxidative stress, TNF- $\alpha$ : Tumor necrosis factor alpha, TBX2: Thromboxane B2.



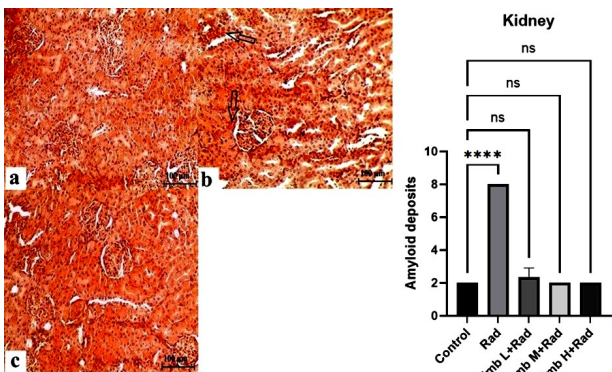
**Figure 1.** The kidney tissue in control and experimental groups. **a)** The normal architecture of kidney from control rats, **G;** Glomerulus, **B;** Bowman's space, **D;** Distal tubule, **P;** Proximal tubule. **b, c, d** and **e)** Severe renal injuries in irradiated group; **C;** Congestion, **M;** The expansion of mesangial matrix **H;** Haemorrhage, Circle; Apoptosis, **N;** Necrosis, Arrow; Hydropic degeneration, **I;** Infiltration. **f)** Slight renal injury in group given UMB before irradiated, **G;** Glomerulus, **H;** Haemorrhage, **C;** Congestion. (H&E) Bar: 100  $\mu\text{m}$ .

PAS staining revealed decreased of glycogen content in renal tissue of exposed rats to radiation. Besides, there were important pathological findings as desquamation in the tubule epithelium, thickening

of the tubular basement membranes, deterioration of the brushy edges of the tubule epithelium, haemorrhage and tubular dilatations. These changes were reduced when UMB orally was given to rats before irradiated (figure 2a-e).



**Figure 2.** The kidney tissue in control and experimental groups. **a)** The normal architecture of kidney from control rats, **G;** Glomerulus, **B;** Bowman's space, **P;** Proximal tubule. Circle; Brush border, Arrow; Tubular basement membrane. **b, c** and **d)** The cells stained weakly and severe renal injuries in irradiated group, Arrow; Thickening of the tubular basement membrane, Asterisk; Desquamated epithelial cells, Arrow head; The loss of brush border, **T;** Tubular dilatation, **M;** Mesangial matrix, **H;** Haemorrhage. **e)** Slight renal injury in group given UMB before irradiated, **M;** Normal histological appearance of mesangial matrix, Circle; Brush border. (PAS), Bar: 100 µm. Abbreviation used: PAS: Periodic Acid-Schiff.



**Figure 3.** The kidney tissue in control and experimental groups. **a)** The normal architecture of kidney from control rats. **b)** The amyloid aggregations in renal tissue of irradiated group, Arrow; Amyloid deposits. **c)** Normal histological appearance of kidney in group given UMB before irradiated. (Congo red), Bar: 100 µm.

With Congo red staining method, in renal tissue was observed extensively amyloid deposits indicating disorders of circulation after radiation exposure. Examination of sections in UMB group (at high dose) revealed that the renal tissue retained its normal architecture (figure 3a-c).

To clearly and accurately describe the histopathological changes in all the experimental groups, we did the semiquantitative evaluation of the

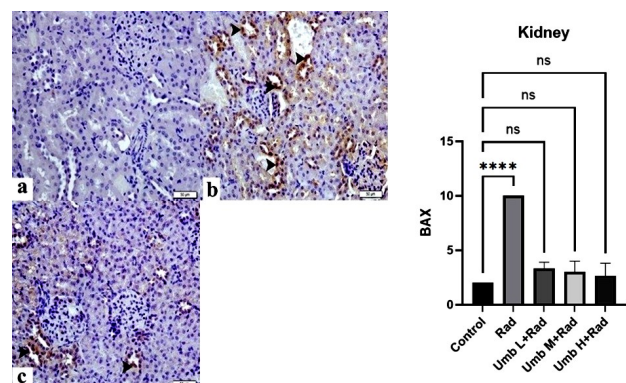
renal lesions and summarized the results in table 2. The kidneys of rats irradiated exhibited marked histological changes ( $p < 0.05$ ). Treatment with UMB before administration of radiation has protective effects on renal cells, which suggested that the UMB at high dose can alleviate kidney injury induced by radiation; however, despite pretreatment with UMB at low doses (30 and 60 mg/kg), the structure of renal tissue slightly ameliorated.

**Table 2.** Statistical data of the radiographic parameters (kVp and mAs values) and patient anthropometric data for selected X-ray examinations.

Groups	Congestion	Infiltration	Tubular Necrosis	Tubular Dilatation	Mesenchymal matrix	Amyloid aggregates
Control	0,00±0,00	0,00±0,00	0,00±0,00	0,00±0,00	0,00±0,00	0,00±0,00
Rad (12 Gy)	4,50±0,51 <sup>a</sup>	3,82±0,63 <sup>a</sup>	3,51±0,92 <sup>a</sup>	3,87±0,65 <sup>a</sup>	1,28±0,53 <sup>a</sup>	3,82±1,85 <sup>a</sup>
Umb (L)	0,00±0,00 <sup>b</sup>	0,00±0,00 <sup>b</sup>	0,00±0,00 <sup>b</sup>	0,00±0,00 <sup>b</sup>	0,00±0,00 <sup>b</sup>	0,00±0,00 <sup>b</sup>
Umb (M)	0,00±0,00 <sup>b</sup>	0,00±0,00 <sup>b</sup>	0,00±0,00 <sup>b</sup>	0,00±0,00 <sup>b</sup>	0,00±0,00 <sup>b</sup>	0,00±0,00 <sup>b</sup>
Umb (H)	0,00±0,00 <sup>b</sup>	0,00±0,00 <sup>b</sup>	0,00±0,00 <sup>b</sup>	0,00±0,00 <sup>b</sup>	0,00±0,00 <sup>b</sup>	0,00±0,00 <sup>b</sup>
Umb (L) +Rad	2,97±0,35 <sup>a,b</sup>	3,70±0,48 <sup>a,b</sup>	3,44±0,74 <sup>a,b</sup>	3,73±0,53 <sup>a,b</sup>	0,71±0,34 <sup>a,b</sup>	3,14±0,30 <sup>a,b</sup>
Umb (M) +Rad	2,85±0,42 <sup>a,b</sup>	2,00±0,27 <sup>a,b,c</sup>	0,81±0,45 <sup>a,b,c</sup>	0,71±0,41 <sup>a,b,c</sup>	0,43±0,17 <sup>a,b,c</sup>	1,33±0,86 <sup>a,b,c</sup>
Umb (H) +Rad	0,42±0,20 <sup>a,b,c</sup>	0,61±0,10 <sup>a,b,c</sup>	0,58±0,22 <sup>a,b,c</sup>	0,93±0,25 <sup>a,b,c</sup>	0,25±0,15 <sup>a,b,c</sup>	0,41±0,17 <sup>a,b,c</sup>

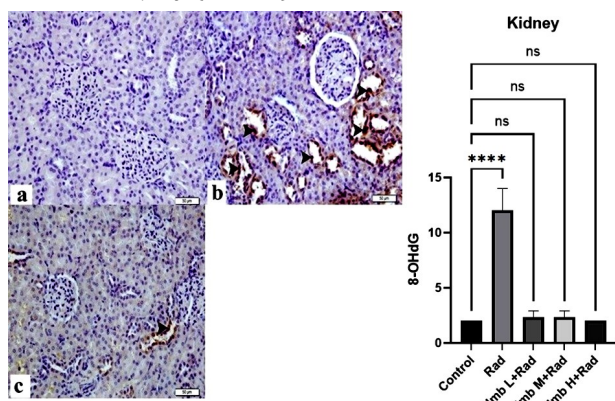
Data are presented as means ± SD (n=7). a,b,c The groups in the same column with different letters are statistically significant ( $p < 0,05$ ). For abbreviations see legend table 1.

To further evaluate the protective effect of UMB in a radiation-induced rat nephrotoxicity model, immunohistochemical analyzes were performed. No staining was observed in the control slides. However strong BAX immunoreactivity was detected in the renal tissue with adverse effect of radiation. By contrast, the expression of BAX was weaker in the kidney sections when given UMB (90 mg/kg) as radioprotective agent (figure 4a-c).



**Figure 4.** Immunohistochemical expression of BAX in kidney tissue of control and experimental groups. **a)** The normal architecture of kidney from control rats. **b)** Widespread BAX expression in renal tissue of irradiated group, Arrowheads; BAX positive cells. **c)** UMB regulates BAX-induced apoptosis in comparison with irradiated group, Arrowheads; BAX positive cells. Bar: 50 µm. Abbreviation used: BAX: Bax is a pro-apoptotic member of the Bcl-2 family of genes which regulate programmed cell death.

We detected 8-OHdG immunoreactivity as an excellent biomarker of oxidative stress after exposure to radiation. 8-OHdG-positive cells weren't observed in control rats, while a significant amount of 8-OHdG-positive cells was presented in the radiation group. Whereas, preadministration of UMB at high dose significantly decreased the levels of 8-OHdG immunoactivity in renal tissue compared with that in the radiation-exposed group (figure 5a-c). Moreover, we scored our data for all groups to explore the effects on apoptosis and oxidative DNA damage of UMB. Our data revealed that the ability of UMB was remarkable to protect the renal cells from BAX activation and 8-OHdG formations against radiation injury (table 3).



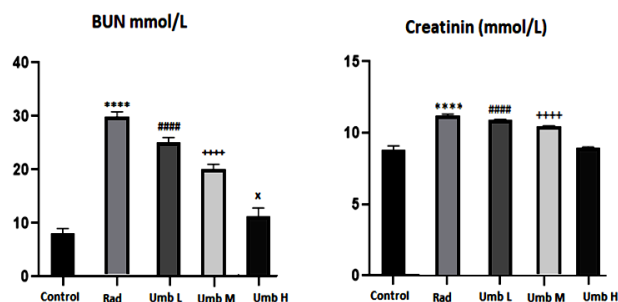
**Figure 5.** Immunohistochemical expression of 8-OHdG in kidney tissue of control and experimental groups. **a)** The normal architecture of kidney from control rats, **b)** Renal tissue which exhibits a strong 8-OHdG immunostaining in irradiated group, Arrowheads; 8-OHdG positive cells. **c)** UMB regulates oxidative stress-induced 8-OHdG expression in comparison with irradiated group, Arrowheads; 8-OHdG positive cells. Bar: 50  $\mu$ m. Abbreviation used: 8-OHdG: 8-hydroxy-2'-deoxyguanosine.

**Table 3.** The scores of immunohistochemical findings in renal tissue for all groups.

Groups	BAX	8-OHdG
Control	-	-
Rad (12 Gy)	+++	+++
Umb (L)	-	-
Umb (M)	-	-
Umb (H)	-	-
Umb (L) +Rad	+++	+++
Umb (M) +Rad	+++	+++
Umb (H) +Rad	+	+

According to immunohistochemical findings: none (-), mild (+), moderate (++) and severe (+++). For abbreviations see legend in table 1.

As shown in figure 6, when compared to the control group, serum BUN and creatinine (Cre) levels increased significantly in the irradiated group of rats, indicating impairment of renal function ( $p < 0.05$  and  $p < 0.001$ ). Whereas, UMB dose-dependently restored kidney function as indicated by the significant reduction of these parameters.



**Figure 6.** The effects of UMB on renal BUN and Creatinin levels against radiation injury, respectively. Data are presented as mean  $\pm$  SEM ( $n=7$ ). \* denotes significant differences between other studied groups and sham (\*:  $p < 0.05$ , \*\*\*:  $p < 0.0001$ ), # denotes significant differences between other studied groups and radiation group (####:  $p < 0.0001$ ) by Tukey's multiple range tests. Abbreviation used: Rad: Radiation, Umb (L): 30 mg/kg, Umb (M): Umb (H): 90 mg/kg UMB, BUN: Blood urea nitrogen.

## DISCUSSION

Understanding the mechanisms of radiation-induced changes is essential to prevent organ damages following radiotherapy (25). The high doses of radiation are associated with renal toxicity and numerous effort has been made to provide treatment guidelines (26). In the current study, the UMB pretreatment on radiation-induced kidney injury has largely been directed toward these mechanisms and the relationship between them. From our experimental data, the increasing amount of TAC due to UMB supplement is important to be involved in the redox modulation of kidney tissue after the high dose radiation exposure. Depending on the oxidative stress, various signaling pathways may be repressed or activated to ensure that kidney health is preserved. That's why, it is necessary to evaluate the oxidative damage markers in the prevention of renal damage under the high radiation doses to determine therapeutic modalities (27). The cellular antioxidants depletion cause large changes in renal tissue but the functional significance of coumarin compounds in response to oxidative stress remain poorly characterised against radiation damage (28). In a study, UMB treatment before irradiation increased antioxidant enzyme activities in human lymphocytes (29). In another study, UMB could improve antioxidant enzyme activities and glutathione (GSH) levels in human dermal fibroblasts cell culture (30). Oxidative stress increases from external agents due to exposure to radiation, drugs or chemicals (31). Excess ROS induced by high dose irradiation may be considered a "radical burst" (32). The TOS is frequently included in the set of parameters used to characterize cellular stress responses (33). Coumarins have function by detoxifying various reactive oxygen species (ROS) forms and protecting tissues against oxidative

damage<sup>(34)</sup>. Our results show a significant increase in TOS levels in kidneys of the irradiation-treated animals. The antioxidant properties of coumarins are due to their conjugated double bonds<sup>(35)</sup>. Each double bond in the coumarin ring are one of the major targets of ROS and and subsequently produces various ketones and aldehydes<sup>(36)</sup>. Taken together, the results of this study clearly suggest the radioprotective effect of UMB in rat kidney by inhibiting reactive oxygen species generation and its subsequent toxicity.

To explore the mechanism underlying the protective effects of UMB on inflammatory damage, the expression of TNF- $\alpha$  was analyzed by biochemical studies. Our results demonstrated that UMB could successfully block this inflammatory cytokin. Its maximal therapeutic benefit was reduce radiation-induced secretion of TNF- $\alpha$  and treatment with UMB presented similar TNF- $\alpha$  levels to control group. Radiation induces the cytokine responses of that could play an important role in mediating radiation toxicity radiation nephropathy does not have a major cellular inflammatory component<sup>(37)</sup>. Here, we suggest a pivotal role of TNF- $\alpha$  in these processes. At the same time, we think that signalling of this cytokine may provide promising prognostic markers for evaluating UMB against radiation toxicity. A previous experimental study has showed that UMB reduced the diabetes-induced renal injury by down regulation of transforming growth factor- $\beta$  (TGF- $\beta$ )<sup>(38)</sup>. On the other hand, protective effects of UMB might be related to the suppression of Toll-like receptor (TLR)/ Nuclear factor kappa-light-chain-enhancer of activated B cells (NF- $\kappa$ B) on myocardial ischemia<sup>(39)</sup>. According to recent data, the anti-inflammatory agents showed immunoregulatory effects and thus, could control the proinflammatory cytokine responses<sup>(40)</sup>. In the present study, we provide, UMB treatment to 12 Gy radiation exposed rats aided in restoring leukocytes tissue infiltration and TNF- $\alpha$  in comparison to irradiated alone rat, thus enhancing their immune system against ionizing radiation-induced assaults. In addition, ROS may affect the levels of inflammatory cytokines in acute radiation exposure<sup>(41)</sup>. Whereas, the role of antioxidant agents in modulating the inflammatory response is highly topical to reduce side effects of radiation<sup>(42)</sup>. With this study, we also demonstrate that UMB has antioxidant effects and therefore, can control the proinflammatory cytokine response.

The restoration of blood flow produces a 'third hit' phenomenon with the effect of UMB. TXB2 is stable metabolite of TXA2 and the overproduction of this vasoconstrictor factor may cause to impaired of the vascular relaxation<sup>(42)</sup>. The present study was demonstrated that TXB2 values significantly increased after acute radiation exposure compared to control levels. Radiation may induce severe impairment in microvessel functions<sup>(43)</sup>. Attention

has focused on which is anti-thrombotic and a vasorelaxant, and TXB2 derived from intrarenal macrophages and platelets<sup>(44)</sup>. In our study, the increase in TXB2 is likely to reflect a parallel activation to renal cell inflammation induced by radiation. The inflammatory process has a critical role in mediating the kidney injury and ultimately leads to poor vascularity<sup>(45)</sup>. However, administration of UMB significantly decrease the increasing values of radiation-mediated TXB2 in rats, suggesting that there may be inhibit to the initiation of vascular injury by secretion of pro-inflammatory cytokines in the kidney in the radiation exposure. Therefore, UMB offers an avenue for the development of new endovascular-based therapies as alternative treatment options for acute kidney injury.

The exposure to high acute doses of ionizing radiation appeared to specifically increase the risk of apoptosis, DNA damage and even carcinogenesis<sup>(46)</sup>. In this study, we focused our attention on BAX and 8-OHdG immunodetections in kidney cells irradiated with single radiation dose of 12 Gy. We observed significant increases in the expressions of BAX and 8-OHdG. BAX plays a crucial role in protecting against renal apoptosis after radiation. Increased Bax expression can inhibit apoptosis while decreased BAX expression can trigger apoptosis<sup>(47)</sup>. 8-OHdG is an important biomarker of oxidative stress-mediated DNA damage in many disease kind and various cancers<sup>(48)</sup>. However, to the best of our knowledge, only few studies have evaluated the impact of ionizing radiation on 8-OHdG damages. We suggested that there is a positive relationship between 8-OHdG values and high radiation dose. Moreover, our findings indicated that 8-OHdG is a rapid and sensitive immunohistochemical method to monitor the DNA damage induced by radiation. Radiation damage contains a complex network of various signaling pathways and is thought the reactive oxygen species critically plays an important role in this process<sup>(49)</sup>. Our study reveals that UMB prevents radiation-induced cell death and genotoxicity by affecting oxidative stress and inflammatory cascades induced by radiation. Moreover, inhibiting TXB2 signalling confers microvascular protection in kidney. All these mechanisms may lead to suppression of increased apoptosis ratio and inhibition of 8-OHdG content

Although the kidney is known as a radiosensitive organ, the pathophysiology of radiotherapy-associated renal injury is poorly understood<sup>(50)</sup>. In our pathological analysis, renal tissue after acute high dose radiation exposure shows paranchymal apoptosis and extensive necrosis which is consistent with radiation nephropathy in other models<sup>(51)</sup>. In addition, our microscopic examination shows congestion, inflammatory cell infiltration, hemorrhage, severe glomerular and tubular injury the hydropic degenerations and brush border loss in

kidney specimens. Pretreatment with UMB significantly alleviates irradiation-induced histopathological changes in rat kidneys. Furthermore, UMB restores increased BUN and creatinine levels in kidney tubules. Radiation can cause a reduction in renal function that may be due to free radical-mediated oxidation. It is suggested that the administered doses must be limited to avoid kidney damage<sup>(52)</sup>. Since vasoactive and anti-inflammatory drugs act as key player in tissue repair. There appears to be significant influence of the use of UMB on the acute kidney injury.

Our study presents new and strong evidences highlighted the importance of UMB use in the prevention of acute renal injury before the radiation exposure. The data in this work show that UMB significantly decreases inflammatory cytokines and improves renal vascular function against radiation damage. Moreover, UMB prevents radiation-induced oxidative stress, DNA damage, renal apoptosis and necrosis. Taken together, this findings indicate that UMB pretreatment maintains normal the kidney histological architecture and function, this will provide the greatest opportunity for its efficacy as a novel drug across a range of radiotherapy.

**Declaration of competing interest:** The authors declare that they have no known competing financial interests or personal relationships that could have appeared to influence the work reported in this paper.

**Funding:** This project was supported by Atatürk University Scientific Research Projects Support Office (Permission No. 263, 26.12.2019-. 30.2.ATA.0.23.85-11).

**Author contributions:** G.Y.D.: Methodology, data curation, formal analysis, visualization, writing – original draft. F.G.: Methodology, formal analysis, writing – review & editing. M.N.G.D., M.A., B.E.: Formal analysis

**Data availability:** Data will be made available on request.

## REFERENCES

- Englund DA, Jolliffe AM, Hanson GJ, et al. (2024) Senotherapeutic drug treatment ameliorates chemotherapy-induced cachexia. *JCI Insight*, **9**(2): e169512.
- Gong L, Zhang Y, Liu C, et al. (2021). Application of radiosensitizers in cancer radiotherapy. *Int J Nanomedicine*, **16**: 1083-1102.
- Seregard S, Pelayes DE, Singh AD (2013) Radiation therapy: posterior segment complications. *Dev Ophthalmol. Rev*, **2013**(52): 23-114.
- Zolghadri S, Rabiei M, Karimian A, et al. (2024) Radiation dose estimation of human organs for <sup>177</sup>Lu-anti-EGFR-PAMAM complex. *International Journal of Radiation Research*, **22**(4): 817-822.
- Kemmner S, Verbeek M, Heemann U (2017) Renal dysfunction following bone marrow transplantation. *J Nephrol*, **30**(2): 201-209.
- Wang X, Xie X, Zhang G, et al. (2024) The efficacy and safety of transcatheter arterial chemoembolization combined with lenvatinib plus radiotherapy in the treatment of hepatocellular carcinoma: a meta-analysis. *International Journal of Radiation Research*, **22**(4): 947-954.
- Armanious MA, Mohammadi H, Khodor S, Oliver DE, et al. (2018) Cardiovascular effects of radiation therapy. *Curr Probl Cancer*, **43**(4): 433-442.
- Saini S, and Gurung P (2025). A comprehensive review of sensors of radiation-induced damage, radiation-induced proximal events, and cell death. *Immunological Reviews*, **329**(1): e13409.
- Geng F, Chen J, Song B, et al. (2024) Chaperone-and PTM-mediated activation of IRF1 tames radiation-induced cell death and the inflammatory response. *Cellular & Molecular Immunology*, **21**(8): 856-872.
- Hsieh MH, Choe JH, Gadhvi J, et al. (2019) p63 and SOX2 dictate glucose reliance and metabolic vulnerabilities in squamous cell carcinomas. *Cell Rep*, **28**(7): 1860-1878.
- Klaus R, Niyazi M, Lange-Sperandio B (2021) Radiation-induced kidney toxicity: molecular and cellular pathogenesis. *Radiat Oncol*, **16**(1): 43.
- Baliga MS, Rao S, Rai MP, et al. (2016) Radioprotective effects of the Ayurvedic medicinal plant *Ocimum sanctum* Linn. (Holy Basil): A memoir. *J Cancer Res Ther*, **12**(1): 7-20.
- Alsherbiny MA, Abd-El salam WH, El Badawy SA, et al. (2019). Ameliorative and protective effects of ginger and its main constituents against natural, chemical and radiation-induced toxicities: A comprehensive review. *Food Chem Toxicol*, **123**: 72-97.
- Kageyama H and Waditee-Sirisattha R (2019) Antioxidative, anti-inflammatory, and anti-aging properties of mycosporine-like amino acids: molecular and cellular mechanisms in the protection of skin-aging. *Mar Drugs*, **17**(4): 222.
- Sharma N, Raina P, Mulla G, et al. (2024) Phytochemical profiling and assessment of habbe musaffe khoon against cervical cancer. *Pharmacognosy Magazine*, **20**(1): 179-188.
- Ameixa J and Bald I (2024) Unraveling the complexity of DNA radiation damage using DNA nanotechnology. *Accounts of Chemical Research*, **57**(11): 1608-1619.
- Leal LE, Moreira ES, Correia BL, et al. (2024) Comparative study of the antioxidant and anti-inflammatory effects of the natural coumarins 1, 2-benzopyrone, umbelliferone and esculetin: In Silico, in vitro and in vivo analyses. *Naunyn-Schmiedeberg's Archives of Pharmacology*, **397**(1): 173-187.
- Sadeghinejad S, Mousavi M, Zeidoooni L, et al. (2024) Ameliorative effects of umbelliferone against acetaminophen-induced hepatic oxidative stress and inflammation in mice. *Research in Pharmaceutical Sciences*, **19**(1): 83-92.
- Yan R, Yang H, Jiang X, et al. (2024) Renal protective effect of umbelliferone on acute kidney injury in rats via alteration of HO-1/Nrf2 and NF-κB signaling pathway. *In Doklady Biochemistry and Biophysics*, **518**(1): 442-451.
- Molinar-Inglis O, DiCarlo AL, Lapinskas PJ, et al. (2024) Radiation-induced multi-organ injury. *Int J Radiat Biol*, **100**(3): 486-504.
- Cruz LF, Figueiredo GF, Pedro LP, et al. (2020) Umbelliferone (7-hydroxycoumarin): A non-toxic antidiarrheal and antiulcerogenic coumarin. *Biomed Pharmacother*, **129**: 110432.
- Luo H, Fan Z, Xiang D, et al. (2018) The protective effect of umbelliferone ameliorates myocardial injury following ischemia reperfusion in the rat through suppression NLRP3 inflammasome and upregulating the PPAR-γ. *Mol Med Rep*, **17**(2): 3404-3410.
- Sproull M, Kramp T, Tandle A, et al. (2017) Multivariate analysis of radiation responsive proteins to predict radiation exposure in total-body irradiation and partial-body irradiation models. *Radiation Research*, **187**(2): 251-258.
- Furukawa S, Nagamatsu A, Nenoï M, et al. (2020) Space Radiation Biology for "Living in Space". *Biomed Res Int*, **8**: 4703286.
- De Wolf K, Rottey S, Vermaelen K, et al. (2017) Combined high dose radiation and pazopanib in metastatic renal cell carcinoma: a phase I dose escalation trial. *Radiat Oncol*, **12**: 157.
- Soliman AF, Saif – Elnasr M, Abdel Fattah SM (2019) Platelet-rich plasma ameliorates gamma radiation-induced nephrotoxicity via modulating oxidative stress and apoptosis. *Life Sci*, **219**: 238-247.
- Karthikeyan R, Kanimozhi G, Prasad NR, et al. (2016) 7-Hydroxycoumarin prevents UVB-induced activation of NF-κappaB and subsequent overexpression of matrix metalloproteinases and inflammatory markers in human dermal fibroblast cells. *J Photochem Photobiol B*, **161**: 6-170.
- Miolo G, Sturaro G, Cigolini G, Menilli L, Tasso A, Zago I, et al. (2018) 4,6,4'-trimethylangelicin shows high anti-proliferative activity on DU145 cells under both UVA and blue light. *Cell Prolif*, **51**: 12430.
- Kanimozhi G, Prasad NR, Ramachandran S, Pugalendi KV (2011)

- Umbelliferone modulates gamma-radiation induced reactive oxygen species generation and subsequent oxidative damage in human blood lymphocytes. *Eur J Pharmacol*, **672**: 9-20.
30. Gu Y, Han J, Jiang C, *et al.* (2020) Biomarkers, oxidative stress and autophagy in skin aging. *Ageing Res*, **59**: 101036.
  31. Simunkova M, Alwasel SH, Alhazza IM, *et al.* (2019) Management of oxidative stress and other pathologies in Alzheimer's disease. *Arch Toxicol*, **93**: 2491-2513.
  32. Jae Kun K, Sung M, Han Jong KK (2016) Fluorescence imaging of reactive oxygen species by confocal laser scanning microscopy for track analysis of synchrotron X-ray photoelectric nanoradiator dose: X-ray pump-optical probe. *J Synchrotron Radiat*, **23**: 6-1191.
  33. Dilber B, Akbulut UE, Serin HM, Alver A, Mentese A, Kolaylı CC, *et al.* (2021) Plasma and erythrocyte oxidative stress markers in children with frequent breath-holding spells. *Klin Padiatr*, **233**(04): 173-180.
  34. Xie X, Huo F, Chao J, *et al.* (2019) A dual electron - withdrawing enhanced selective / sensitive chemodosimeter for detection on bisulfate and its living cell imaging. *Spectrochimica Acta Part A: Molecular and Biomolecular Spectroscopy*, **220**: 117148.
  35. Ma N, Kato T, Isogai T, Gu Y, Yamashita T (2019) The potential effects of taurine in mitigation of radiation nephropathy. *Adv Exp Med Biol*, **1155**: 497-505.
  36. Zhang L and Wei W (2020) Anti-inflammatory and immunoregulatory effects of paeoniflorin and total glucosides of paeony. *Pharmacol Ther*, **207**: 107452.
  37. Garud MS and Kulkarni YA (2017) Attenuation of renal damage in type I diabetic rats by umbelliferone - A coumarin derivative. *Pharmacol Rep*, **69**: 1263-1269.
  38. Gan J, Qian W, Lin S (2018) Umbelliferone alleviates myocardial ischemia: the role of inflammation and apoptosis. *Inflammation*, **41**: 464-473.
  39. Li X, Zhuang X, Qiao T (2019) Role of ferroptosis in the process of acute radiation-induced lung injury in mice. *Biochem Biophys Res Commun*, **519**: 240-245.
  40. Cao Y, Zhang M, Ding H, *et al.* (2019) Synchrotron radiation microtomography for high-resolution neurovascular network morphology investigation. *J Synchrotron Radiat*, **26**: 607-618.
  41. Wen Y, Lu X, Ren J, *et al.* (2019) KLF4 in Macrophages Attenuates TNF $\alpha$ -mediated kidney injury and fibrosis. *J Am Soc Nephrol*, **30**: 1925-1938.
  42. Patrono C and Rocca B (2019) Measurement of thromboxane biosynthesis in health and disease. *Front Pharmacol*, **10**: 1244.
  43. Winter M, Dokic I, Schlegel JU, *et al.* (2017) Deciphering the acute cellular phosphoproteome response to irradiation warcken with X-rays, protons and carbon ions. *Mol Cell Proteomics*, **16**: 855-872.
  44. Conti P, Caraffa A, Gallenga CE, Ross R, Kritas SK, Frydas I, *et al.* (2020) IL-1 induces throboxane-A2 (TxA2) in COVID-19 causing inflammation and micro-thrombi: inhibitory effect of the IL-1 receptor antagonist (IL-1Ra). *J Biol Regul Homeost Agents*, **34**: 1623-1627.
  45. Nasehi M, Torabinejad S, Hashemi M, *et al.* (2020) Effect of cholestasis and NeuroAid treatment on the expression of Bax, Bcl-2, Pgc-1alpha and Tfam genes involved in apoptosis and mitochondrial biogenesis in the striatum of male rats. *Metab Brain Dis*, **35**: 183-192.
  46. Purbey PK, Scumpia PO, Kim PJ, *et al.* (2017) Defined sensing mechanisms and signaling pathways contribute to the global inflammatory gene expression output elicited by ionizing radiation. *Immunity*, **47**: 421-434.
  47. Shanshan C, Xin L, Wen L, *et al.* (2018) Folic acid modulates VPO1 DNA methylation levels and alleviates oxidative stress-induced apoptosis in vivo and in vitro. *Redox*, **19**: 81-91.
  48. Barciszewska AM, Giel-Pietraszuk M, Perrigue PM, Naskręć-Barciszewska M (2019) Total DNA methylation changes reflect random oxidative DNA damage in gliomas. *Cells*, **9**(8): 1065.
  49. Cai X, Yang Y, Shen Y, *et al.* (2019) Noninvasive stereotactic radiotherapy for renal denervation in a swine model. *J Am Coll Cardiol*, **74**: 1697-1709.
  50. Han NK, Jung MG, Jeong YJ, *et al.* (2019) Plasma Fibrinogen-Like 1 as a potential biomarker for radiation-induced liver injury. *Cells*, **8**: 1042.
  51. Bellés M, Gonzalo S, Serra N, *et al.* (2017) Environmental exposure to low-doses of ionizing radiation. Effects on early nephrotoxicity in mice. *Environ Res*, **156**: 291-296.
  52. Paul S, Hanna L, Harding C, *et al.* (2020) Output from VIP cells of the mammalian central clock regulates daily physiological rhythms. *Nat Commun*, **11**: 1453.