

Efficacy and safety of ultrasound-guided microwave ablation therapy for benign and malignant thyroid nodules of different sizes based on real-world evidence

L. Zhang^{1#}, Y. Liu^{2#}, P. Zhang¹, Y. Zhang³, M. Xie⁴, X. Zhang¹, H. Li², Y. Duan^{5*}

¹Department of Clinical Nutrition and Metabolism, Shijiazhuang People's Hospital, Shijiazhuang, Hebei, China

²Department of Endocrinology and Metabolism, Shijiazhuang People's Hospital Fanxi Road Campus, Shijiazhuang, Hebei, China

³School of Medicine, Medical Sciences and Nutrition, University of Aberdeen, UK

⁴Department of Plastic and Cosmetic Surgery, Shijiazhuang People's Hospital Fanxi Road Campus, Shijiazhuang, Hebei, China

⁵Department of Medical Imaging, Henan Armed Police Corps Hospital, Zhengzhou, Henan, China

ABSTRACT

► Original article

*Corresponding author:

Yulong Duan, M.D.,

E-mail:

Duanyulong191960@126.com

Received: April 2025

Final revised: June 2025

Accepted: August 2025

Int. J. Radiat. Res., January 2026;
24(1): 143-150

DOI: 10.61186/ijrr.24.1.22

Keywords: Microwave Ablation, ultrasonography, thyroid nodule, nodule size, therapeutic efficacy.

Background: Benign and malignant thyroid nodules (BMTDs) often show lymph-node metastasis in the neck and impose great physical and psychological burdens. Therefore, early diagnosis and treatment BMTD are essential. The objective of this study was to analyze the effectiveness and safety of ultrasound-guided microwave ablation therapy for BMTDs of different sizes. **Materials and Methods:** The study examined 180 patients with solitary BMTD from Shijiazhuang People's Hospital between June 2022 and June 2024. Patients with BMTD diameter larger than 1 cm were assigned to group A (60 patients), and those with diameters of 0.5–1 cm were assigned to group B (60 patients). Group C comprised those with BMTD diameters smaller than <0.5 cm (60 patients). All patients were treated with conventional thyroid ultrasound, ultrasonography, and ultrasound-guided microwave ablation. The primary assessments were the change in transverse and longitudinal diameters of the thyroid nodules, volume reduction rate (VRR), and cure rate at months 1, 3, 6, and 9 post-treatment. The secondary outcomes were quality-of-life scores, incidence of adverse effects, complications, and recurrence rates. **Results:** After treatment, all indicators improved in all groups. Group C had greater improvements in nodule diameter, VRR, cure rate, cosmetic score, adverse reactions, and complications than group A and group B. Thyroid biochemical indicators showed greater improvement in groups B and C than group A ($P < 0.05$). No groups showed any recurrence ($P > 0.05$). **Conclusion:** Ultrasound-guided microwave ablation can treat BMTD and is particularly suitable for solitary thyroid nodules with diameter <0.5 cm, which showed the highest cure rate.

INTRODUCTION

Thyroid nodules are commonly occurring confined masses that form in tissues after abnormal proliferation of thyroid cells. However, the yearly incidence of thyroid cancer has been rising⁽¹⁾, and differentiation between benign and malignant thyroid nodules (BMTDs) is critical. Epidemiological studies have shown that more than 90% of adult thyroid nodules are benign, and 5–15% of them show malignancy⁽²⁾.

The various types of benign nodules include nodules that are formed by a simple goiter, which are often due to iodine deficiency and other causes of compensatory thyroid hyperplasia. Thyroid adenomas are common benign tumors that originate from the follicular epithelium of thyroid gland, and thyroid cysts are often cystic cavities that contain fluid⁽³⁾. Most patients with benign nodules have no obvious symptoms, although some larger nodules

may compress the surrounding tissues. This results in symptoms such as shortness of breath due to compression of the trachea, as well as dysphagia due to compression of the esophagus, but the overall progression is slow⁽⁴⁾.

Malignant nodules (i.e., thyroid cancer) are commonly characterized by papillary carcinoma, follicular cell carcinoma, undifferentiated carcinoma, and medullary carcinoma. Papillary carcinoma is the most common type, although it has a relatively low degree of malignancy and slow growth. Undifferentiated carcinoma is highly malignant and progresses rapidly, with neck lymph node metastasis and distant metastasis occurring at an early stage. Those who are affected are prone to symptoms such as hoarseness and respiratory difficulties in addition to neck lumps⁽⁵⁾.

Benign nodule formation is often associated with conditions such as abnormal iodine intake (iodine deficiency or excess) and autoimmune thyroiditis⁽⁶⁾.

The pathogenesis of malignant nodules is more complex, but ionizing radiation is a clear risk factor, and the risk of thyroid cancer is remarkably increased after receiving a certain dose of radiation during childhood. Genetic factors play a role in some thyroid cancers, such as familial medullary carcinoma, which has a clear genetic predisposition⁽⁷⁾. Improved diagnostic accuracy of microscopic thyroid cancer maximizes the detection of early thyroid malignancies, improves the prognosis thanks to earlier surgery, and reduces excessive diagnosis and treatment of benign nodules.

Ultrasound-guided microwave ablation is an emerging minimally invasive treatment method that is widely employed in treating thyroid nodules⁽⁸⁾. With the help of accurate real-time positioning using ultrasound, a microwave ablation needle percutaneously punctures the thyroid nodule, and the thermal effect of microwaves is used to induce coagulative necrosis of the nodule tissue as a minimally invasive treatment⁽⁹⁾. The electromagnetic field generated by the microwaves increases the movement speed of ions and polar molecules in the tissue and generates heat through friction. This increases the local temperature to 60–100°C in a short period of time, which leads to denaturation of the cellular proteins and rupture of the cell membranes. Thus, the tissues undergo necrosis and are ultimately absorbed by the body⁽¹⁰⁾.

This technique has significant advantages. Through precise localization, high-frequency ultrasound can clearly indicate the location, size, and morphology of the nodule and its relationship with the surrounding tissues⁽¹¹⁾. This information can guide the precise placement of the ablation needle with minimal error while effectively avoiding important structures such as blood vessels and nerves, which reduces the risk of complications⁽¹²⁾. This method also involves minimal trauma, a puncture width of only about 3 mm, no need for sutures, and rapid healing. The aesthetic results are also excellent, with no obvious scars forming on the neck, which makes the method suitable for patients who have stringent aesthetic requirements⁽¹³⁾.

Compared with traditional thyroidectomy, microwave ablation maximizes the preservation of normal thyroid tissue, maintains thyroid function, reduces the incidence of postoperative hypothyroidism, and eliminates the need for long-term use of thyroid hormone-replacement medication for most patients⁽¹⁴⁾. For benign thyroid nodules, it can significantly reduce the size of nodules, effectively relieve compression symptoms, and improve the quality of life of patients. Some studies have shown that it is also effective in controlling tumor progression in cases of percutaneous transluminal mitral commissurotomy (PTMC) that meet the indications⁽¹⁵⁾.

Although the overall safety of this technique is high, complications may still occur, such as voice change, local pain, bleeding, and infection. Nevertheless, the incidence of such complications is low, and in most cases recovery symptomatic treatment is possible. The risk of complications can be reduced further by strictly controlling the indications and contraindications, standardizing the operation process, and improving operation technique⁽¹⁶⁾. The indications include ultrasound suggestive of a single nodule, diameter ≤ 1 cm, a nodule distance > 2 mm from the pericardium, confirmation of papillary carcinoma by fine needle aspiration biopsy (FNA), suspicions of lymph-node metastasis in the lateral neck region, and benign thyroid nodules such as thyroid adenoma and nodular goiter^(17,18).

Compared with similar previous studies, the present study demonstrated unique novelty in several dimensions. In terms of study design, most of the previous studies only focused on a single size range of thyroid nodules or did not differentiate between benign and malignant nodules at different sizes. In contrast, this study comprehensively observed the therapeutic effects of ultrasound-guided microwave ablation on benign and malignant thyroid nodules of different sizes, and this multi-comparison design was able to reveal the differences in the efficacy of this treatment for different nodule sizes more accurately. This study provides rich data for clinical support, which is expected to provide reference for the standardized application of this technology in the treatment of thyroid nodules of different sizes, and to provide clinicians with more alternative treatment strategies, which will contribute to the further development of the field of thyroid nodule treatment.

MATERIALS AND METHODS

Study design and participants

This retrospective clinical study involved 180 patients with solitary thyroid nodules (benign or malignant) who were admitted to Shijiazhuang People's Hospital from June 2022 to June 2024. The patients were grouped according to the diameter of the nodule into group A (≥ 1 cm, 60 patients), group B (0.5–1 cm, 60 patients), and group C (< 0.5 cm, 60 patients). All patients were treated with conventional thyroid ultrasound, ultrasonography, and ultrasound-guided microwave ablation.

Sample-size calculation

The sample size required to detect a statistically significant difference was calculated using a power analysis with the software G*Power 3.1.9.7. The sample size was calculated based on the primary outcome of the nodal volume reduction rate.

Considering an α level of 0.05 and 85% efficacy, a sample size of 49 patients was required for each group. Considering the potential uncertainties, a sample size of 60 cases per group was chosen for this study, which should allow for reliable conclusions to be drawn.

Inclusion and exclusion criteria

Inclusion criteria: (1) All included patients met the clinical diagnostic criteria for thyroid nodules and (2) all underwent ultrasound examination and ultrasound-guided microwave ablation in our hospital. (3) The patients had not taken hormone-containing drugs within 6 months of treatment and (4) were in the age range of 20–65 years. (5) All patients were able to truthfully express their main complaints about their symptoms and answer relevant questions from medical staff, and (6) all patients and their families agreed to participate in the study and signed an informed consent form.

Exclusion criteria: Patients were excluded (1) if they had malignant tumors of any site or type, such as thyroid cancer or (2) if they had multiple thyroid nodules. (3) Patients were also excluded if they had combined hemorrhagic coagulation dysfunction, severe liver or renal function defects, severe cardiovascular disease, or other more serious diseases. (4) Those who had combined chronic infectious diseases or had been involved in clinical drug trials or clinical studies were excluded as well, as were (6) patients with comorbid neurological or psychiatric disorders that would make it difficult for them to communicate normally. Other exclusion criteria included (7) a previous history of chest surgery, (8) any request to stop treatment or automatic discharge for personal reasons, (9) other conditions that the study physician believed should warrant exclusion, and (10) other circumstances that could affect the indicators assessed during follow-up observations.

Ethics statement

The study was performed in compliance with the Declaration of Helsinki and the hospital's ethical guidelines. This study was approved by the Ethics Committee of the Shijiazhuang People's Hospital. Ethical approval number 2019092.

Instruments and equipments

The surgical equipment was a KY-2000A microwave ablator (Nanjing Kangyou Medical Technology Co., Ltd., Approval No.: State Mechanical Note Quarantine 20193011833). The selected microwave ablation needle was a KY-2450A-2 sterile disposable microwave ablation needle (Nanjing Kangyou Medical Technology Co., Ltd.). The tip size of the needle's anterior pole was 3 mm, and the length of the needle pole was 10 cm. The ultrasound contrast agent was Sonic Novelty (Bracco, Italy),

which contains 59 mg of sulfur hexafluoride gas and 25 mg of white lyophilized powder. Furthermore, 5 mL of 0.9% sodium chloride were added to form a milky-white microfoam suspension after shaking, and 2.4 mL of contrast were injected into the elbow vein. Ultrasound equipment was Philips EPIQ 7 diagnostic ultrasound system (Philips Healthcare, The Netherlands). Sodium chloride solution (Baxter International Inc., USA). Epinephrine (Sigma-Aldrich, USA). 2% Lidocaine injection (Hubei Tiansheng Pharmaceutical, China).

Ultrasound-guided microwave ablation examination

The patient was placed in the supine position to adequately expose the neck area. Intraoperative vital signs were continuously monitored and intravenous access was established. After routine disinfection and towel, a 2% lidocaine anesthetic puncture path was used under ultrasound guidance.

Three-dimensional radii were measured under ultrasound, and the 'fluid barrier method' was used during puncture. When the nodule was adjacent to important structures such as carotid artery, laryngeal return nerve, trachea, etc., 30–40 mL of 0.9% sodium chloride solution (or add 0.5 mg of epinephrine) was injected under ultrasound guidance to form a fluid isolation band of about 5 mm.

The thyroid ultrasonographic quadrants were divided into puncture paths: outer lower quadrant nodules were punctured from the midline of the neck to the outside; inner lower quadrant nodules were punctured from the outside of the neck to the inside; and outer upper and inner upper quadrant nodules could be selected from either of the above two paths. During the ablation process, the path of the ablation needle was monitored by real-time ultrasound, and important structures were strictly avoided to avoid related injuries.

Primary observation indicators

We observed the changes in the size of the transverse diameters (upper and lower diameters) and longitudinal diameters (anterior and posterior diameters) of the nodule at 1, 3, 6, and 9 months after follow-up. We calculated the nodule volume reduction rates (VRRs) as $VRR = (V_{preoperative} - V_{follow-up}) / V_{preoperative} * 100\%$. The cure rate was determined using the condition of the nodules. "Cured" meant that the nodules had completely disappeared, while "not cured" meant that the nodules had not disappeared. To determine thyroid biochemical indexes, fasting venous blood was collected from the patients, and the upper serum layer was extracted. The levels of thyroid stimulating hormone (TSH), triiodothyronine (T3), thyroxine (T4), and free thyroxine (FT4) were measured using an automatic chemiluminescence immunoassay analyzer (Suzhou Lihe Biomedical Engineering Co., Ltd., Model: H360)

(19).

Secondary indicators

The cosmetic improvement was assessed before and 9 months after surgery using a cosmetic score. The cosmetic outcome was scored as follows: 1: no palpable mass; 2: a mass is not visible but is palpable; 3: a mass is visible upon swallowing; 4: a mass is visible. The occurrence of adverse reactions was recorded for all three groups and included nausea or vomiting, bleeding, dysphagia, and pain during treatment. Complications were recorded in all three groups, including intra-nodal hemorrhage, tracheal compression, esophageal compression and so on. We also evaluated the recurrence rate during the follow-up period.

Statistical methods

The statistical software SPSS 27.0 was used for analysis of the data. Measurements that conform to a normal distribution value were represented as the mean ± standard deviation ($\bar{x}\pm s$). Comparisons between groups were made using an independent-sample *t*-test. Numerical data were expressed as the rate (%) and tested using a χ^2 test. *P*<0.05 indicated statistically significant differences.

RESULTS

Basic information

The study involved 180 patients with BMTD with

60 patients each in groups A, B, and C. Table 1 shows their demographic and baseline characteristics, which showed no remarkable discrepancies between groups (*P*>0.05). Thus, the three groups were comparable at the pretreatment level, and confounding by demographic or clinical factors did not affect the analysis results.

Transverse and longitudinal diameter of nodules

Table 2 shows the changes in the size of the transverse and longitudinal diameters of nodules at 1, 3, 6, and 9 months after surgery. The nodule diameters of all three groups of patients were markedly reduced after surgery, and the difference among between them was significant (*P*<0.05). The reduction of nodule diameter was more obvious in group C. This may have resulted from group C having the smallest nodules, so the effect would be more obvious. This indicates that ultrasound-guided microwave ablation can clearly treat thyroid nodules of different sizes, and smaller diameter leads to more obvious treatment effect in the short term.

VRR

The benign and malignant nodal contrast is illustrated in figure 1. Under contrast, the preoperative nodules all demonstrated inhomogeneous hyperenhancement. Immediately after ablation, they showed the formation of a strong echogenic vaporized area, and the lesions were non-enhancing and showed clearly visible shrinkage after the procedure.

Table 1. Patient demographics and baseline disease characteristics.

Parameter	A group	B group	C group	F/ χ^2	P
Age (year)	43.35±5.11	43.07±4.73	43.37±5.76	0.063	0.939
Gender (male/female)	23/37	25/35	26/34	0.579	0.749
Height (year)	160.34±8.09	159.48±9.14	160.11±8.97	0.154	0.857
Weight (kg)	61.88±7.45	61.63±6.97	61.81±8.47	0.017	0.983
Position (side/center)	53/7	55/5	54/6	0.889	0.641
Body mass index (kg/m ²)	22.47±2.57	22.22±2.53	22.19±2.37	0.222	0.801
Nature of nodule (benign/malignant)	45/15	46/14	47/13	0.261	0.878
Thyroid function (abnormal/normal)	20/40	19/41	18/42	0.216	0.898
Hypertension (yes/no)	15/45	13/47	12/48	0.730	0.694
Diabetes (yes/no)	10/50	9/51	11/49	0.336	0.845
Medical history (initial findings/review findings)	38/22	41/19	40/20	0.624	0.732
Cancer grading (low/medium/high)	5/35/15	6/34/15	5/36/14	0.401	0.982
Cancer staging (I~II/III~IV)	45/15	44/16	46/14	0.427	0.808
Lymph node metastasis (yes/no)	18/42	17/43	19/41	0.381	0.827
Distant metastasis (yes/no)	5/55	6/54	4/56	0.611	0.737

Note: A Group (nodule diameter ≥1cm, n=60), B Group (nodule diameter 0.5-1cm, n=60), C Group (nodule diameter <0.5cm, n=60).

Table 2. Nodule transverse and longitudinal diameters ($\bar{x}\pm s$, mm).

Time		A group	B group	C group	F	P
Preoperative	Transverse diameter	13.42±0.59 ^a	6.53±0.54 ^d	3.48±0.60 ^c	4635.88	<0.001
	Longitudinal diameter	12.05±0.38 ^a	6.24±0.33 ^d	3.35±0.41 ^c	8291.42	<0.001
1 month after surgery	Transverse diameter	9.39±0.27 ^a	4.92±0.33 ^{ab}	2.49±0.23 ^c	9268.09	<0.001
	Longitudinal diameter	9.20±0.34 ^a	4.74±0.28 ^b	2.31±0.24 ^c	8882.96	<0.001
3 months after surgery	Transverse diameter	6.72±0.34 ^a	2.99±0.30 ^b	1.66±0.29 ^c	4294.44	<0.001
	Longitudinal diameter	6.35±0.28 ^a	2.80±0.34 ^{ab}	1.44±0.27 ^c	4295.82	<0.001
6 months after surgery	Transverse diameter	5.55±0.26 ^a	2.03±0.32 ^{ab}	1.12±0.30 ^c	3742.24	<0.001
	Longitudinal diameter	5.26±0.31 ^a	1.93±0.28 ^b	1.03±0.31 ^c	3339.51	<0.001
9 months after surgery	Transverse diameter	3.50±0.32 ^a	1.44±0.29 ^b	0.56±0.24 ^c	1680.52	<0.001
	Longitudinal diameter	3.23±0.33 ^a	1.30±0.24 ^{ab}	0.48±0.30 ^c	1386.26	<0.001

Note: “*” represents marked discrepancy compared with preoperative, *P*<0.05; “a”、“b” and “c” indicates marked differences among groups compared to each other, *P*<0.05. A Group (nodule diameter ≥1cm, n=60), B Group (nodule diameter 0.5-1cm, n=60), C Group (nodule diameter <0.5cm, n=60).

Table 3. The VRR results (x±s, %).

Time	A group	B group	C group	F	P
1 month after surgery	31.58±7.53	33.60±7.94	34.51±8.16	2.171	0.117
3 months after surgery	51.88±7.97 ^a	55.54±8.81 ^b	63.30±7.84 ^c	30.188	<0.001
6 months after surgery	58.68±9.42 ^a	69.19±8.37 ^b	74.36±8.89 ^c	48.285	<0.001
9 months after surgery	71.65±7.97 ^a	78.96±7.68 ^b	83.52±8.16 ^c	34.144	<0.001

Note: “*” represents marked discrepancy compared with preoperative, $P < 0.05$; “a”, “b” and “c” indicates marked differences among groups compared to each other, $P < 0.05$. A Group (nodule diameter ≥ 1 cm, n=60), B Group (nodule diameter 0.5-1cm, n=60), C Group (nodule diameter < 0.5 cm, n=60).

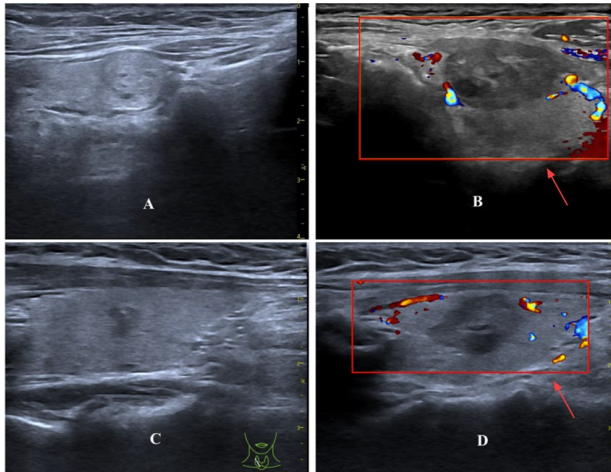


Figure 1. Imaging of benign and malignant nodules.

A: preoperative benign nodule; B: postoperative benign nodule; C: preoperative malignant nodule; D: postoperative malignant nodule.

The nodal VRR results of three groups are demonstrated in table 3. The nodes of three groups of patients reached a shrinkage rate of more than 30% at one month after surgery, and no marked discrepancy in nodal VRR was observed among the three groups ($P > 0.05$). After three months postoperatively, the VRR comparison of three groups of patients differed remarkably. At 9 months after surgery, the nodule VRR was the largest in group C patients and reached 83.52±8.16%, whereas 71.65±7.97% and 78.96±7.68% were observed in groups A and B, respectively. This indicates that microwave ablation was effective in treatment of thyroid nodules, and group C had the best therapeutic effect.

Cure rate

Table 4 shows the cure-rate results. At 3 months postoperatively, there were marked discrepancies in the cure rate of nodules among the three groups. Group C had the highest rate (18%), followed by group B (10%) and group A (3.8%) ($P < 0.05$). At 9 months after surgery, the cure rate of group C was as high as 85.6% and was markedly higher than the rates of 73.8% in group B and 68.4% in group A. The results indicated that microwave ablation had the highest cure rate for the treatment of small thyroid nodules.

Table 4. Cure rate (x±s, %).

Time	A group	B group	C group	F	P
1 month after surgery	0	0	0	-	-
3 months after surgery	3.8 ^a	10 ^b	18 ^c	10.354	<0.05
6 months after surgery	39.2 ^a	45.3 ^b	65.4 ^c	14.827	<0.05
9 months after surgery	68.4 ^a	73.8 ^b	85.6 ^c	9.211	<0.05

Note: “*” represents marked discrepancy compared with pre-treatment, $P < 0.05$; “a”, “b” and “c” indicates marked differences among groups compared to each other, $P < 0.05$. A Group (nodule diameter ≥ 1 cm, n=60), B Group (nodule diameter 0.5-1cm, n=60), C Group (nodule diameter < 0.5 cm, n=60).

Thyroid biochemical indicators

Thyroid biochemical indicators are important for analyzing changes in thyroid function. The results are shown in table 5. No remarkable discrepancy was found in the thyroid biochemical indexes of three groups before treatment ($P > 0.05$), but they were markedly reduced post-treatment. The results were also markedly different between the three groups. The level of indicators of group A was obviously greater than those of other groups ($P < 0.05$). The indicators of groups B and C were within the normal range. Thus, the improvement of thyroid biochemical indicators was greater in groups B and C.

Table 5. Thyroid biochemical indicators (x±s).

Norm	Time	A group	B group	C group	F	P
TSH (mIU/L)	Pre-treatment	6.42±1.89	6.48±2.97	6.51±1.95	0.022	0.979
	Post-treatment	4.52±2.04 ^a	3.09±1.91 ^b	2.77±1.15 ^c	17.196	<0.001
T3 (nmol/L)	Pre-treatment	8.38±2.10	8.29±1.91	8.15±2.06	0.199	0.820
	Post-treatment	4.18±1.82 ^a	2.53±0.63 ^b	1.73±0.63 ^c	67.702	<0.001
T4 (nmol/L)	Pre-treatment	324.86±21.06	324.49±22.86	324.94±27.93	0.006	0.994
	Post-treatment	187.96±10.53 ^a	155.36±8.30 ^b	101.22±8.74 ^c	116.94	<0.001
FT4 (pmol/L)	Pre-treatment	34.87±3.02	34.54±2.92	34.96±3.33	0.312	0.733
	Post-treatment	22.91±2.68 ^a	18.94±2.25 ^b	14.15±1.02 ^c	261.14	<0.001

Note: “*” represents marked discrepancy compared with pre-treatment, $P < 0.05$; “a”, “b” and “c” indicates marked differences among groups compared to each other, $P < 0.05$. A Group (nodule diameter ≥ 1 cm, n=60), B Group (nodule diameter 0.5-1cm, n=60), C Group (nodule diameter < 0.5 cm, n=60).

Cosmetic score

The cosmetic score results are shown in table 6. No obvious discrepancy was found between groups before treatment ($P > 0.05$), but the scores were markedly reduced post-treatment. Group A had the highest scores (2.19±0.18), followed by group B (1.24±0.18) and group C (0.59±0.10) ($P < 0.05$). This indicates that the cosmetic condition of the patients in all three groups improved after treatment, and group C had the best improvement.

Adverse reactions

The three groups experienced adverse reactions of varying degrees during treatment, such as nausea or vomiting, as shown in table 7. No obvious discrepancy was found in the comparison of adverse reactions among the groups of patients, and the total

incidences of adverse reactions in group A, group B, and group C were 21.67% (13/60), 15.00% (9/60) and 8.33% (5/60), respectively. These results were obviously different compared between groups ($P>0.05$). This suggests that a smaller diameter of the nodule leads to a lower degree of adverse reactions post-treatment.

Table 6. Cosmetic scores ($\bar{x}\pm s$, scores).

Time	A group	B group	C group	F	P
Pre-treatment	3.33±0.42	3.38±0.35	3.43±0.37	0.987	0.375
Post-treatment	2.19±0.18 ^a	1.24±0.18 ^b	0.59±0.10 ^c	1598.72	<0.001
t	-19.325	-42.118	-57.396		
P	<0.001	<0.001	<0.001		

Note: "a", "b" and "c" indicates marked differences among groups compared to each other, $P<0.05$. A Group (nodule diameter ≥ 1 cm, n=60), B Group (nodule diameter 0.5-1cm, n=60), C Group (nodule diameter <0.5 cm, n=60).

Table 7. Incidence of adverse reactions [n (%)].

	A group	B group	C group	χ^2	P
Nausea or vomiting	2(3.33)	1(1.67)	1(1.67)	0.293	0.864
Bleeding	1(1.67)	1(1.67)	0(0.00)	2.027	0.363
Difficulty or pain in swallowing	1(1.67)	1(1.67)	1(1.67)	0.000	1.000
Skin inflammation	2(3.33)	0(0.00)	1(1.67)	2.847	0.241
Restricted neck movement	2(3.33)	2(3.33)	1(1.67)	0.257	0.879
Localized pain	1(1.67)	1(1.67)	0(0.00)	2.027	0.363
Hoarseness	1(1.67)	1(1.67)	0(0.00)	2.027	0.363
Fast heartbeat	1(1.67)	1(1.67)	0(0.00)	2.027	0.363
Skin burns	2(3.33)	1(1.67)	1(1.67)	0.293	0.864
Total incidence	13(21.67)	9(15.00)	5(8.33)	7.686	<0.05

Note: A Group (nodule diameter ≥ 1 cm, n=60), B Group (nodule diameter 0.5-1cm, n=60), C Group (nodule diameter <0.5 cm, n=60).

Complications and recurrence rate

Table 8 shows the complications that occurred, which included intra-nodal hemorrhage and tracheal compression. No obvious discrepancy was found among the three groups ($P>0.05$). The total incidences in group A, group B, and group C were 23.33% (14/60), 16.67% (10/60), and 8.33% (5/60), respectively, which were obviously different between groups ($P<0.05$). This suggests that smaller nodule diameter leads to a lower incidence of complications post-treatment. No nodule recurrence was observed in any of the three groups. The results indicate that ultrasound-guided microwave ablation is effective in treating BMTD of different sizes.

Table 8. Complications [n(%)].

	A group	B group	C group	χ^2	P
Intra-nodal hemorrhage	2 (3.33)	1 (1.67)	1 (1.67)	0.293	0.864
Tracheal compression	1 (1.67)	1 (1.67)	0 (0.00)	2.027	0.363
Esophageal compression	1 (1.67)	1 (1.67)	0 (0.00)	2.027	0.363
Injury to the recurrent laryngeal nerve	2 (3.33)	2 (3.33)	1 (1.67)	0.257	0.879
Burns to surrounding tissue	2 (3.33)	2 (3.33)	1 (1.67)	0.257	0.879
Rupture of the nodule	1 (1.67)	0 (0.00)	0 (0.00)	4.027	0.134
Abnormal thyroid function	2 (3.33)	1 (1.67)	1 (1.67)	0.293	0.864
Infection	1 (1.67)	1 (1.67)	0 (0.00)	2.027	0.363
Scarring	2 (3.33)	1 (1.67)	1 (1.67)	0.293	0.864
Total incidence	14(23.33)	10(16.67)	5(8.33)	8.482	<0.05

Note: A Group (nodule diameter ≥ 1 cm, n=60), B Group (nodule diameter 0.5-1cm, n=60), C Group (nodule diameter <0.5 cm, n=60).

DISCUSSION

Most thyroid nodules are benign, and their detection rate is up to 50% when using high-resolution ultrasound. Many patients are asymptomatic, and nodules are often found unintentionally during other examinations (20). Thyroid nodules vary in size, which correlates with benignity, malignancy, and symptoms to some extent. Smaller nodules may remain asymptomatic for a long period of time, while larger nodules trigger symptoms such as shortness of breath, hoarseness, and dysphagia due to compression of surrounding tissues. The risk of compression symptoms is significantly higher for nodules ≥ 4 cm in diameter (21).

There are various types of thyroid nodules. Simple nodules form from the proliferation of normal thyroid tissue and are usually asymptomatic. Colloid nodules result from the accumulation of colloid in the thyroid follicles and are also usually asymptomatic. Adenomas are benign tumors that are formed by the proliferation of follicular epithelial cells, some of which can produce thyroid hormones and cause hyperthyroidism. Cysts are fluid-filled sac-like structures that are mostly benign but sometimes cause symptoms by compressing the surrounding tissue. Inflammatory nodules are associated with chronic inflammation of the thyroid gland and may be associated with autoimmune diseases such as Hashimoto's thyroiditis.

Most benign nodules do not require specific treatment and are reviewed regularly (22, 23). About 5% of thyroid nodules are malignant. The common types of thyroid cancer are papillary thyroid carcinoma (PTC), follicular carcinoma, medullary carcinoma, and undifferentiated carcinoma. PTC is the most common and accounts for over, 80% of cases, although it has relatively low malignancy and a better prognosis. Follicular carcinoma is the second most common and has higher malignancy than PTC. Medullary carcinoma and undifferentiated carcinoma are less common but have high malignancy and poorer prognoses (24, 25).

Determination of the benignity or malignancy of thyroid nodules is very important and is mainly based on ultrasonography, fine-needle aspiration biopsy, and serologic examination (26). Ultrasonography is used for preliminary judgments by observing the size, morphology, border, echogenicity, blood flow, and calcification of the nodule. Signs that suggest malignancy include irregular morphology, an unclear border, hypoechogenicity, an aspect ratio > 1 , microcalcification, and an abundant-blood flow signal (27). Fine-needle aspiration biopsy is done by extracting nodule cells for pathological examination, which is important for clarifying the nature of the nodule and is highly accurate (28). In serologic examination, indicators

such as thyroglobulin and calcitonin can assist in the judgment of nodules⁽²⁹⁾.

Ultrasound-guided microwave ablation is a minimal-invasive treatment which received much attention recently⁽³⁰⁾. The procedure is usually completed within 15–30 minutes and is highly safe. It can effectively avoid normal tissue and neurovascular damage and preserves the function of the corresponding organs. The small incision, excellent aesthetic results, rapid recovery, and wide range of applications make it an attractive treatment option for patients^(31,32).

The transverse and longitudinal diameters of thyroid nodules can help determine the nature of the nodule and assist in evaluating the extent of surgical resection, and changes in these diameters are important for monitoring postoperative recurrence⁽³³⁾. VRR is a key indicator for assessing the postoperative efficacy of thyroid nodules, and for nodules of different sizes, a higher VRR usually indicates a better therapeutic efficacy and good postoperative recovery⁽³⁴⁾. The cure rate reflects the effectiveness of surgery in eradicating thyroid nodules of different sizes. The cure rate is higher for benign nodules, while for malignant nodules, it depends on the nodule size, stage, and other factors. Thus, it is an important indicator of the success of surgery and the prognosis of patients⁽³⁵⁾.

The findings of this study show that the nodule diameters of all three groups were markedly reduced after surgery, and the reduction was more pronounced in group C ($P<0.05$). Group C had the largest nodal VRR, which was markedly greater than in group A and group B ($P<0.05$). The cure rate of group C was as high as 85.6%, which was remarkably higher than the rates of 73.8% in group B and 68.4% in group A ($P<0.05$). Thyroid biochemical indicators can be used to determine the functional status of the thyroid gland; assist in the diagnosis of thyroid disease, thyroid cancer, and other conditions; and help to monitor the condition of the patient. The results showed that the thyroid biochemical indicators of three groups were obviously reduced after surgery, and the indicator levels in group C were markedly below those of the other two groups ($P<0.05$). Cui *et al.* in their analysis of the short-term efficacy of radiofrequency ablation in BMTDs of different sizes reported a higher cure rate with smaller nodule diameters, which is similar to the findings of the present study⁽³⁶⁾.

The postoperative cosmetic score for thyroid nodules can help to judge the cosmetic outcome of the surgical incision, provide patients with quantitative information about the recovery of their postoperative appearance, and help to relieve their psychological stress. At the same time, the score can help doctors assess the impact of surgical techniques on appearance and provide a reference for improving surgical methods and enhancing cosmetic results⁽³⁷⁾.

The results showed that post-treatment, the scores of all three groups were markedly reduced ($P<0.05$), but group C had the best improvement. The rates of adverse reactions and complications in group C were markedly below those of group A and group B. During the follow-up period, no obvious recurrence of nodules was observed in all three groups. Sun *et al.* studied of the efficacy of ultrasound-guided radiofrequency ablation for benign thyroid nodules of different sizes and similarly found that smaller nodules show better improvement in appearance⁽³⁸⁾.

This study had some limitations. The relatively small sample size did not cover all the different types of thyroid nodules, which may have led to biased findings and affected the extrapolation and reliability of the conclusions. One limitation of single-center studies is that there may be differences in the patients' underlying conditions, which may affect the generalizability of the findings. In addition, the relatively short follow-up period did not allow for adequate assessment of the long-term effects and safety of the treatment. Therefore, further studies should use large sample sizes and longer follow-up periods to more completely assess the efficacy and safety of ultrasound-guided microwave ablation for BMTD of different sizes.

CONCLUSION

This study analyzed the effectiveness and safety of ultrasound-guided microwave ablation therapy for BMTD of different sizes to provide a new reference for treatment. The results indicated that all indicators of the three groups improved in the post-treatment period. Compared with both groups, the improvement effect of group C was better than that of groups A and B. No recurrence was observed in all three groups. It indicates that ultrasound-guided microwave ablation has significant effects in treating BMTDs of different sizes. This method can effectively reduce the size of nodules and reduce the occurrence of adverse reactions and complications. However, the present study had a small sample size and a short follow-up period, and more specific indexes could not be examined. High-quality clinical studies involving multiple centers and larger samples should be carried to validate these results.

Acknowledgment: None.

Consent to Publish: The manuscript has neither been previously published nor is under consideration by any other journal. The authors have all approved the content of the paper.

Consent to Participate: We secured a signed informed consent form from every participant.

Ethic Approval: This study was approved by the Ethics Committee of the Shijiazhuang People's Hospital. Ethical approval number 2019092.

Data Availability Statement: The data that support the findings of this study are available from the corresponding author, upon reasonable request.

Funding: None.

Conflicts of Interest: The authors declare that they have no financial conflicts of interest.

Author Contribution: L.Z., Y.L.: Developed and planned the study, performed experiments, and interpreted results, edited and refined the manuscript with a focus on critical intellectual contributions. Y.Z., M.X., X.Z., H.L.: Participated in collecting, assessing, and interpreting the data, made significant contributions to data interpretation and manuscript preparation. P.Z., Y.D.: Provided substantial intellectual input during the drafting and revision of the manuscript.

REFERENCES

- Alexander EK and Cibas ES (2022) Diagnosis of thyroid nodules. *The Lancet Diabetes & Endocrinology*, **10(7)**: 533-539.
- Alexander EK, Doherty GM, Barletta JA (2022) Management of thyroid nodules. *The Lancet Diabetes & Endocrinology*, **10(7)**: 540-548.
- Durante C, Grani G, Lamartina L, et al. (2018) The diagnosis and management of thyroid nodules: a review. *The Journal of the American Medical Association*, **319(9)**: 914-924.
- Noel JE and Sinclair CF (2024) Radiofrequency ablation for benign thyroid nodules. *The Journal of Clinical Endocrinology & Metabolism*, **109(1)**: e12-e17.
- Kobaly K, Kim CS, Mandel SJ (2022) Contemporary management of thyroid nodules. *Annual Review of Medicine*, **73(73)**: 517-528.
- Fan K, Loh E, Tam K (2024) Efficacy of HIFU for the treatment of benign thyroid nodules: a systematic review and meta-analysis. *European Radiology*, **34(4)**: 2310-2322.
- Lebbink CA, Links TP, Czarniecka A, et al. (2022) 2022 European Thyroid Association Guidelines for the management of pediatric thyroid nodules and differentiated thyroid carcinoma. *European Thyroid Journal*, **11(6)**: e220146.
- Gu J, Fan X, Sun X, et al. (2023) Efficacy and safety of ultrasound-guided percutaneous laser ablation in the treatment of unifocal papillary thyroid microcarcinoma. *International Journal of Radiation Research*, **21(3)**: 577.
- Liu L, Wang T, Lei B (2021) Ultrasound-guided microwave ablation in the management of symptomatic uterine myomas: a systematic review and meta-analysis. *Journal of Minimally Invasive Gynecology*, **28(12)**: 1982-1992.
- Guo M, Dou J, Zheng L, et al. (2024) Ultrasound-guided microwave ablation versus surgery for solitary T1bN0M0 papillary thyroid carcinoma: a prospective multicenter study. *European Radiology*, **34(1)**: 569-578.
- Xiuming L and Fuxing L (2024) Study on the effectiveness and accuracy of ultrasound diagnosis and pathological diagnosis of thyroid lesions. *International Journal of Radiation Research*, **22(3)**: 727.
- Zhao W, Guo J, Li H, et al. (2022) Safety and efficacy of percutaneous microwave ablation using combined computed tomography and ultrasound-guided imaging in patients with hepatocellular carcinoma: A retrospective study. *Journal of Cancer Research and Therapeutics*, **18(2)**: 418-425.
- Li H, Zhang G, Wang H, et al. (2024) Ultrasound-guided microwave ablation for the treatment of idiopathic granulomatous mastitis: comparison with surgical excision. *BMC Women's Health*, **24(1)**: 248.
- Qian Y, Li Z, Fan C, et al. (2024) Comparison of ultrasound-guided microwave ablation, laser ablation, and radiofrequency ablation for the treatment of elderly patients with benign thyroid nodules: A meta-analysis. *Experimental Gerontology*, **191**: 112425.
- Ren Y, Li Y, Chu X, et al. (2025) Ultrasound-guided microwave ablation versus surgery for low-risk solitary papillary thyroid microcarcinoma: a propensity-matched cohort study. *Endocrine Connections*, **14(2)**: e240366.
- Zhou W, Ni X, Xu S, et al. (2020) Ultrasound-guided laser ablation versus microwave ablation for patients with unifocal papillary thyroid microcarcinoma: a retrospective study. *Lasers in Surgery Medicine*, **52(9)**: 855-862.
- Liang X, Jiang B, Ji Y, et al. (2025) Complications of ultrasound-guided thermal ablation of thyroid nodules and associated risk factors: an experience from 9667 cases. *European Radiology*, **35(4)**: 2307-2319.
- Li N, Yilie D, Yunchuan D, et al. (2024) Comparison of the efficacy and safety of ultrasound-guided radiofrequency ablation and microwave ablation for the treatment of unifocal papillary thyroid microcarcinoma: a retrospective study. *International Journal of Hyperthermia*, **41(1)**: 2287964.
- Feng P, Wei D, Zhang Y, et al. (2022) Comparison on the consistency of Mindray and Siemens chemiluminescence analyzers for detecting FT3, FT4 and TSH in patients with hyper- and hypothyroidism. *Annals of Translational Medicine*, **10(20)**: 1133.
- Wu X, Tan G, Luo H, et al. (2024) A knowledge-interpretable multi-task learning framework for automated thyroid nodule diagnosis in ultrasound videos. *Medical Image Analysis*, **91**: 103039.
- Giovanella L, Campenni A, Tuncel M, et al. (2024) Integrated Diagnostics of Thyroid Nodules. *Cancers*, **16(2)**: 311.
- Kant R, Davis A, Verma V (2020) Thyroid Nodules: Advances in Evaluation and Management. *American Family Physician*, **102(5)**: 298-304.
- Muhammad H, Santhanam P, Russell JO, et al. (2021) RFA and benign thyroid nodules: Review of the current literature. *Laryngoscope Investigative Otolaryngology*, **6(1)**: 155-165.
- Bernet VJ and Chindris A-M (2021) Update on the evaluation of thyroid nodules. *Journal of Nuclear Medicine*, **62(2)**: 135.
- Tufano RP, Pace Asciak P, Russell JO, et al. (2021) Update of radiofrequency ablation for treating benign and malignant thyroid nodules. The future is now. *Frontiers in Endocrinology*, **12**: 698689.
- Navin PJ, Thompson SM, Kurup AN, et al. (2022) Radiofrequency ablation of benign and malignant thyroid nodules. *RadioGraphics*, **42(6)**: 1812-1828.
- Xie F, Luo Y, Lan Y, et al. (2022) Differential diagnosis and feature visualization for thyroid nodules using computer-aided ultrasonic diagnosis system: initial clinical assessment. *BMC Medical Imaging*, **22(1)**: 153.
- Park JY, Choi W, Hong AR, et al. (2023) A comprehensive assessment of the harms of fine-needle aspiration biopsy for thyroid nodules: A systematic review. *Endocrinology and Metabolism*, **38(1)**: 104-116.
- García González L and García Pascual L (2022) Clinical usefulness of thyroid ultrasonography in patients with primary hypothyroidism. *Endocrinología, Diabetes y Nutrición (English ed)*, **69(9)**: 686-693.
- Miao B, Ruan G, Meng F, et al. (2025) The effects of radiofrequency ablation on lymphocytes, subsets and cytokines in patients with thyroid cancer: A meta-analysis. *International Journal of Radiation Research*, **23(1)**: 1.
- Xia B, Yu B, Wang X, et al. (2021) Conspicuousness and recurrence related factors of ultrasound-guided microwave ablation in the treatment of benign thyroid nodules. *BMC Surgery*, **21(1)**: 317.
- Wang X, Xiaoyan N, Shuang M, et al. (2021) Analysis and evaluation of the efficacy of ultrasound-guided microwave ablation for papillary thyroid microcarcinoma. *International Journal of Hyperthermia*, **38(1)**: 1476-1485.
- Zhang F, Russell YX, Guber HA (2021) Transverse and longitudinal ultrasound location of thyroid nodules and risk of thyroid cancer. *Endocrine Practice*, **27(7)**: 682-690.
- Chung SR, Choi YJ, Lee SS, et al. (2020) Interobserver reproducibility in sonographic measurement of diameter and volume of papillary thyroid microcarcinoma. *Thyroid*, **31(3)**: 452-458.
- Kandil E, Issa PP, Randolph GW (2023) Can thyroid nodules be managed with radiofrequency ablation? *Advances in Surgery*, **57(1)**: 87-101.
- Cui W, Ma J, Liang R, et al. (2025) Evaluation of short-term efficacy of RFA in different size of benign and malignant thyroid nodules. *Chinese Journal of Ultrasound in Medicine*, **41(1)**: 4-8.
- Lee DW, Bang HS, Jeong JH, et al. (2021) Cosmetic outcomes after transoral robotic thyroidectomy: Comparison with transaxillary, postauricular, and conventional approaches. *Oral Oncology*, **114**: 105139.
- Sun M, Li Q, Niu J, et al. (2023) Effect of ultrasound-guided radiofrequency ablation on benign thyroid nodules of different sizes. *Chinese Journal of Ultrasound in Medicine*, **39(2)**: 134-137.